

International guidelines for the diagnosis and management of hereditary haemorrhagic telangiectasia

M E Faughnan,^{1,2} V A Palda,³ G Garcia-Tsao,⁴ U W Geisthoff,^{5,6} J McDonald,⁷ D D Proctor,⁸ J Spears,⁹ D H Brown,¹⁰ E Buscarini,¹¹ M S Chesnutt,¹² V Cottin,¹³ A Ganguly,¹⁴ J R Gossage,¹⁵ A E Guttmacher,¹⁶ R H Hyland,¹ S J Kennedy,¹⁷ J Korzenik,¹⁸ J J Mager,¹⁹ A P Ozanne,²⁰ J F Piccirillo,²¹ D Picus,²² H Plauchu,²³ M E M Porteous,²⁴ R E Pyeritz,²⁵ D A Ross,²⁶ C Sabba,²⁷ K Swanson,²⁸ P Terry,²⁹ M C Wallace,³⁰ C J J Westermann,¹⁹ R I White,³¹ L H Young,³² R Zarrabeitia³³

► Additional tables are published online only. To view these files please visit the journal online (<http://jmg.bmj.com>).

For numbered affiliations see end of article.

Correspondence to

M E Faughnan, St. Michael's Hospital, University of Toronto, St. Michael's Hospital, 30 Bond St, Toronto, M5B-1W8, Canada; faughnanm@smh.ca

The HHT Guidelines Working Group intends to generate updated clinical guidelines within approximately 5 years. Centres with recognised expertise in the diagnosis and management of HHT can be located at <http://www.hht.org/>, the website for the HHT Foundation International.

Received 2 May 2009

Revised 22 May 2009

Accepted 30 May 2009

ABSTRACT

Background HHT is an autosomal dominant disease with an estimated prevalence of at least 1/5000 which can frequently be complicated by the presence of clinically significant arteriovenous malformations in the brain, lung, gastrointestinal tract and liver. HHT is under-diagnosed and families may be unaware of the available screening and treatment, leading to unnecessary stroke and life-threatening hemorrhage in children and adults.

Objective The goal of this international HHT guidelines process was to develop evidence-informed consensus guidelines regarding the diagnosis of HHT and the prevention of HHT-related complications and treatment of symptomatic disease.

Methods The overall guidelines process was developed using the AGREE framework, using a systematic search strategy and literature retrieval with incorporation of expert evidence in a structured consensus process where published literature was lacking. The Guidelines Working Group included experts (clinical and genetic) from eleven countries, in all aspects of HHT, guidelines methodologists, health care workers, health care administrators, HHT clinic staff, medical trainees, patient advocacy representatives and patients with HHT. The Working Group determined clinically relevant questions during the pre-conference process. The literature search was conducted using the OVID MEDLINE database, from 1966 to October 2006. The Working Group subsequently convened at the Guidelines Conference to partake in a structured consensus process using the evidence tables generated from the systematic searches.

Results The outcome of the conference was the generation of 33 recommendations for the diagnosis and management of HHT, with at least 80% agreement amongst the expert panel for 30 of the 33 recommendations.

(AVMs) in the brain, lung, gastrointestinal (GI) tract and liver.

Unfortunately, HHT is often not diagnosed, and entire families therefore remain unaware of available screening and treatment, and children and adults unnecessarily develop stroke or life-threatening haemorrhage. The goal of the international HHT guidelines process was to develop evidence-based consensus guidelines for the diagnosis of HHT, the prevention of HHT-related complications, and treatment of symptomatic disease.

METHODS

The overall guidelines process (figure 1) was developed using the AGREE framework³ with guidelines methodologists. The structure was that of a systematic evidence-based process with incorporation of expert evidence in a structured consensus process where evidence was lacking. We expected only weak or poor evidence in most areas, but chose this approach to maximise quality and applicability of the guidelines and provide a foundation for future research and guidelines in HHT.

Determination of need for guidelines

The need for clinical guidelines for HHT was identified by the HHT Foundation International, an international advocacy group for people with HHT, and the Foundation's Scientific and Medical Advisory Board. This was based on their consistent observations of care gaps in HHT, specifically that HHT is underdiagnosed, that there are often delays in diagnosis, and that most patients and families with HHT are not receiving appropriate preventive treatment. No clinical guidelines were in place for the multisystem manifestations of the disorder, except for guidelines for liver vascular malformations (VMs).⁴

Membership of the HHT guidelines working group

An organising committee of clinicians, scientists, methodologists, patients and Foundation members selected the members of the HHT Guidelines Working Group. This included experts (clinical and genetic) from 11 countries, in all aspects of HHT, guidelines methodologists, healthcare workers and administrators, HHT Foundation representatives,

INTRODUCTION

Hereditary haemorrhagic telangiectasia (HHT) is an autosomal dominant disease with an estimated prevalence of 1/5000¹ and is thought to be present in all races and parts of the world. Although epistaxis is the most common symptom of HHT and mucocutaneous telangiectasia the most common sign,² HHT is also often complicated by the presence of arteriovenous malformations



This paper is freely available online under the BMJ Journals unlocked scheme, see <http://jmg.bmj.com/site/about/unlocked.xhtml>

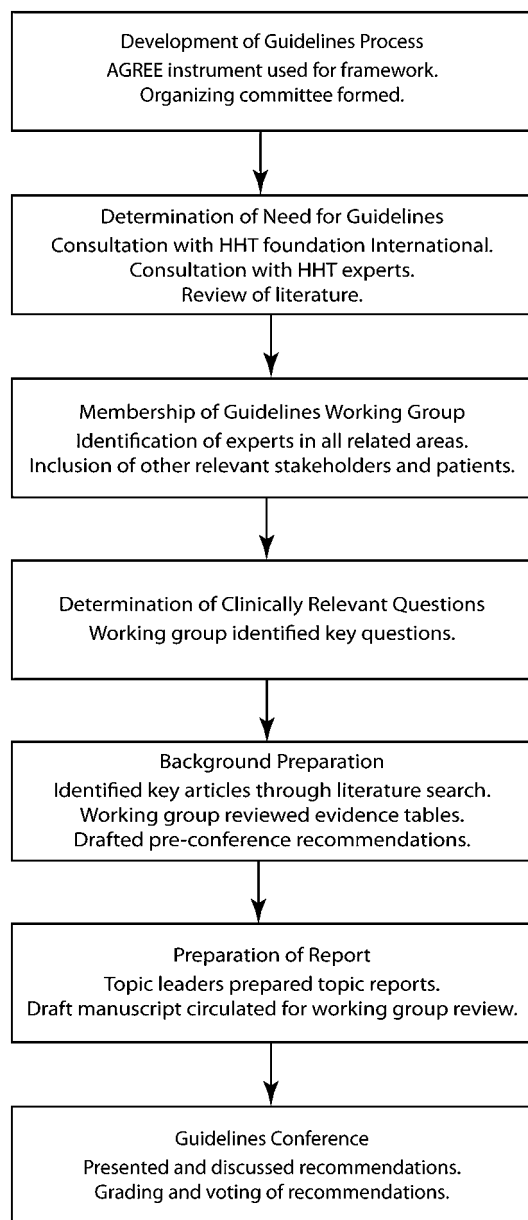


Figure 1 The adopted process of guideline development. HHT, hereditary haemorrhagic telangiectasia.

and patients with HHT. Each member was also a member of a topic subgroup (diagnosis, epistaxis, cerebral vascular malformations (CVMs), pulmonary AVMs (PAVMs), GI bleeding and liver VMs). Patients contributed to the development of the clinically relevant questions and the recommendations, with particular input regarding values around recommendations.

Determination of clinically relevant questions

During the pre-conference process, the topic subgroups worked by email to develop clinically relevant questions. The subgroups circulated and edited these through several iterations. These formed the basis for the literature review.

Background preparation

A literature search was conducted using the OVID Medline database from 1966 to October 2006 to identify relevant English-language publications, using the search strategies as outlined in table AI (see online). Hand searches of relevant

articles and reviews were also performed for each clinically relevant question. Bibliographies of retrieved publications were reviewed to identify sources not obtained in our search. Publications in abstract form were included to minimise publication bias. One author (MEF) and the literature review assistant (J Silver) independently reviewed abstracts, and any relevant studies were pulled for review. Inclusion and exclusion criteria for study selection are listed in table AI (see online). Results from selected studies were extracted into evidence tables, and, along with original papers, were sent to participants for review and to determine if any relevant literature was missing.

Determination of clinical recommendations

Participants convened at the Guidelines Conference to take part in a structured consensus process using the evidence tables. With the assistance of professional guidelines facilitators, topic subgroups prioritised clinically relevant questions and then generated recommendations for these. All participants assembled afterwards to vote for all generated recommendations. Those recommendations achieving less than 80% agreement were further discussed, revised again with a facilitator, and voted on again. Wording of recommendations was considered final, and they are presented with the percentage agreement obtained on the final vote. Priorities for future research were also identified during the process (see online table AII).

Grading of evidence

Each recommendation was graded to indicate the level of evidence available using the classification system of the Canadian Task Force on the Periodic Health Examination⁵ (table 1). In addition, values around recommendations were generated using the GRADE instrument,^{6,7} and these were reported as 'strength of the recommendation'. The 'strength of the recommendation' incorporated evidentiary and non-evidentiary factors, including baseline risks of outcomes, benefits of treatment, potential harms of treatment, certainty of point estimates, and levels of evidence. Values were also incorporated, such as the importance of certain outcomes to stakeholders and other factors such as availability of certain tests.

General organisation

The pre-conference process occurred by email over 6 months leading up to the 2-day Guidelines Conference near Toronto, Canada, in November 2006. The Conference was held in a facility with anonymous key pad voting technology. The large group sessions were recorded (audio) and minuted.

Preparation of report

Topic leaders generated each area of this article, which was then revised by MEF, VP and the topic members for each group, and then reviewed by the other authors. The literature search

Table 1 Categorisation of the quality of evidence

Quality of evidence	Description
I	Evidence obtained from at least one properly randomised, controlled trial
II-1	Evidence obtained from well-designed controlled trials without randomisation
II-2	Evidence obtained from well-designed cohort or case-control analytical studies, preferably from more than one centre or research group
II-3	Evidence obtained from comparison between times and places with or without the intervention, or dramatic results in uncontrolled experiments
III	Opinions of respected authorities, based on clinical experience, descriptive studies, or reports of expert committees

Table 2 Curaçao Criteria for clinical diagnosis of hereditary haemorrhagic telangiectasia (HHT)

Criteria	Description
Epistaxis	Spontaneous and recurrent
Telangiectases	Multiple, at characteristic sites: lips, oral cavity, fingers, nose
Visceral lesions	Gastrointestinal telangiectasia, pulmonary, hepatic, cerebral or spinal arteriovenous malformations
Family history	A first-degree relative with HHT according to these criteria

referenced was that obtained in October 2006. At the time of final manuscript review, two steps were taken to ensure that no generated recommendation needed immediate revision. Firstly, a literature search for any interim randomised controlled trials in HHT was performed, which revealed none. Secondly, the Working Group was polled for knowledge of any recent publications that would lead to a significant change in any of the recommendations, and none were identified.

Role of funding sources

Although the funding organisations were not directly involved in the generation of the recommendations, some of the participants in the guidelines process were also board members of the HHT Foundation International and its Scientific and Medical Advisory Board. The other funding sources had no role in the design, conduct and reporting of the study or in the decision to submit the results for publication.

DIAGNOSIS OF HHT

Background

Making the diagnosis of HHT in a patient allows the appropriate screening and preventive treatment to be undertaken in the patient and their affected family members. HHT has traditionally been diagnosed on the basis of its clinical features, but can now also be diagnosed using genetic testing. We reviewed the evidence and expert experience for clinical and genetic diagnosis in HHT.

The clinical diagnostic features of HHT have been identified by describing the clinical presentation of patients who have known or suspected HHT and their close relatives. The average age of onset for epistaxis is 12 years, with nearly 100% affected by age 40 years.^{2 8–10} Most patients report the appearance of telangiectasia of the mouth, face or hands 5–30 years after the onset of nose bleeds, most commonly during the third decade. Unfortunately, there are no longitudinal natural history studies of HHT clinical manifestations and how these might vary with genotype.

In 2000, consensus clinical diagnostic criteria known as the Curaçao Criteria were published¹¹ (table 2). Using these criteria, a diagnosis of HHT is considered ‘definite’ if three or more criteria are present, ‘possible or suspected’ if two criteria are present, and ‘unlikely’ if 0 or 1 criterion is present.

There have been no studies reporting sensitivity and specificity of the Curaçao Criteria, but the expert panel agreed that the Curaçao Criteria are particularly helpful in two situations: (1) discriminating affected from non-affected older adults and (2) ruling-in the diagnosis in younger adults and children. The expert panel was specifically concerned about the risk of missing diagnoses in children and young adults, who might have no epistaxis or visible telangiectases, yet have undiagnosed PAVMs or CVMs.¹² It is in these groups that genetic testing should be most useful.

The goal of genetic testing for HHT is to clarify the specific HHT mutation in an HHT family, allowing diagnosis among those relatives (often children and young adults) who do not meet clinical diagnostic criteria. Genetic testing is performed first on the index case in the family and involves DNA sequencing and deletion/duplication analysis of the coding exons of the endoglin gene (*ENG*, HHT1) and the activin A receptor type II-like 1 gene (*ACVRL1*, HHT2). Mutations in these genes account for the majority of cases of HHT. At least two other HHT loci have been described, although specific genes at these loci are not yet identified.^{13 14} Mutations in the *SMAD4* gene can cause a rare syndrome which combines juvenile polyposis and HHT.¹⁵ Genetic testing in HHT is complex relative to many other genetic conditions because a mutation in one of multiple genes can cause the condition, not all genes that can cause HHT have been discovered, and there are no ‘common mutations’, with most families having their own ‘private’ HHT mutation.

Several authors have reported^{16 17} a clinical sensitivity/mutation detection rate of ~75% for sequence analysis of *ENG* and *ACVRL1*. Use of an additional method to detect large deletion/duplication mutations increases the detection rate by ~10%.^{16 17} Recent reports suggest that about 1–3% of patients clinically diagnosed with HHT will have a mutation detected in the *SMAD4* gene, or about 10% of those who test negative for *ENG* and *ACVRL1* mutations.^{17–19}

There is considerable clinical overlap between patients/families with *ENG* mutation and those with *ACVRL1* mutation, with VMs reported in similar organs in both types.^{20–22} The expert panel agreed that *ENG* versus *ACVRL1* genotype should not significantly influence screening recommendations for VMs. Most HHT patients/families with *SMAD4* mutation reported to date have juvenile polyposis and are therefore at risk of GI malignancy.^{15 18}

There is currently no evidence about the effect of prenatal testing for HHT and no consensus among experts about how fetal diagnosis might alter pregnancy or delivery management. Expert experience is that prenatal diagnosis is not commonly sought in HHT, and is most often requested as an alternative to postnatal diagnostic testing when there is already another reason for performing prenatal testing.

Table 3 Level II study of screening tests for pulmonary arteriovenous malformations (PAVMs) in patients with hereditary haemorrhagic telangiectasia (HHT), using reference standard

Study	No of subjects	Prevalence of PAVMs	Reference standard	Test	Sensitivity	Specificity
Cottin <i>et al</i> (2004) ⁸²	105	45%	CT or PA	TTCE	93%	52%
				Chest x-ray	70%	98%
				A-a gradient	68%	98%

A-a gradient, alveolar–arterial gradient calculated from arterial blood gas on room air; CT, CT of the chest; PA, diagnostic pulmonary angiography; TTCE, transthoracic contrast echocardiography (using agitated saline).

Recommendations

The expert panel recommends that clinicians diagnose HHT using the Curaçao Criteria (see table) or by identification of a causative mutation.

Clinical considerations: Applying the Curaçao Criteria for clinical diagnosis of HHT requires a targeted, multi-generation family history for HHT, given that most individuals with HHT will have an affected parent, grandparent and other close relatives. When applying the Curaçao Criteria, the clinician should consider the patient's age, given the commonly delayed appearance of the signs and symptoms of HHT. At least 90% of patients with HHT meet the clinical criteria by age 40, but few do in the first decade of life. If a patient has clinical features suggestive of HHT, but no family history, it is possible that patient has a new mutation, and therefore the diagnosis of HHT remains possible.

The expert panel recommends that clinicians consider the diagnosis of HHT in patients with one or more Curaçao Criteria (see table).

Clinical considerations: When applying the Curaçao Criteria for clinical diagnosis, identifying 2 or fewer of the criteria after clinical examination and history should not be considered sufficient evidence to rule out the diagnosis, particularly in the first few decades of life.

The expert panel recommends that asymptomatic children of a parent with HHT be considered to have possible HHT, unless excluded by genetic testing.

Clinical considerations: Given the expected poor sensitivity of the Curaçao Criteria for clinical diagnosis in children, the clinician can clarify the diagnosis using genetic testing, if a familial mutation has been identified. If genetic testing is not possible, the clinician should proceed as if the child has HHT and consider appropriate screening for visceral AVMs.

The expert panel recommends that clinicians refer patients for diagnostic genetic testing for HHT

1. To identify the causative mutation in a family with clinically confirmed HHT
2. To establish a diagnosis in relatives of a person with a known causative mutation, including:
 - a. Individuals who are asymptomatic or minimally symptomatic
 - b. Individuals who desire prenatal testing
3. To assist in establishing a diagnosis of HHT in individuals who do not meet clinical diagnostic criteria

Clinical considerations: Genetic testing for HHT is a multi-step process. In an experienced laboratory, the index case is generally tested by sequence and deletions/duplications analysis of both the *ENG* and *ACVRL1* genes. It is reasonable to perform the deletion/duplication analysis either simultaneously with the sequence analysis or only in cases in which the sequence analysis is negative or equivocal.

If an HHT-causing mutation is identified in the index case (test is positive), diagnostic genetic testing for HHT can be offered to all at-risk relatives. These relatives would have 'family-specific' mutation testing by targeted sequencing.

If no mutation is identified (test is negative) in the index case, diagnostic genetic testing cannot be offered to other family members. Such families should be advised that, in the future, currently undetectable HHT mutations will become detectable as new genes and testing methods are discovered. In the meantime, diagnosis and medical management of at-risk family members will rely on clinical findings and knowledge of the natural history of HHT.

If a genetic variant of uncertain significance is identified (test is equivocal) in the index case, additional confirmatory testing may be available, or additional interpretive information may become available in the future, to clarify whether the genetic variant in question is in fact a benign variant or a disease-causing mutation.

The expert panel recommends that for individuals who test negative for *ENG* and *ACVRL1* coding sequence mutations, *SMAD4* testing should be considered to identify the causative mutation.

Clinical considerations: If full gene analysis for the *ENG* and *ACVRL1* genes is negative, the next step is for the clinician to request similar testing of the *SMAD4* gene.

The expert panel recommends that all HHT patients and their families with *SMAD4* gene mutations should undergo gastrointestinal screening for polyposis and gastrointestinal malignancies as per national screening recommendations.

Clinical considerations: Appropriate screening for patients and those with the *SMAD4* gene mutations includes colonic screening for polyposis with colonoscopy, starting at age 15–18 and everyone to 2 years thereafter. The first colonoscopy should be performed at an age 5 years younger than that at which the youngest family member developed colon cancer. Affected patients should also undergo upper GI surveillance with oesophagogastroduodenoscopy/enteroscopy/small bowel series or capsule study starting at age 25 and everyone to 2 years thereafter in accordance with previously published guidelines.²⁵

Level of evidence: III
Strength of recommendation: weak
Agreement: 82%

Level of evidence: III
Strength of recommendation: weak
Agreement: 91%

Level of evidence: III
Strength of recommendation: weak
Agreement: 87%

Level of evidence: III
Strength of recommendation: weak
Agreement: 80%

Level of evidence: III
Strength of recommendation: weak
Agreement: 93%

Level of evidence: III
Strength of recommendation: strong
Agreement: 97%

EPISTAXIS

Background

Recurrent spontaneous epistaxis is the most common symptom of HHT and often leads to iron-deficiency anaemia.²⁴ Epistaxis appears before the age of 20 years in about 50% of patients, with 78–96% of all HHT patients developing it eventually.² During the guidelines development process, patients identified epistaxis as a priority HHT-related health concern affecting their everyday life, and the literature suggests that epistaxis is an important factor reducing quality of life in HHT.²⁵ We reviewed the evidence for treatment of HHT-related epistaxis, searching for studies regarding treatment of the usual chronic recurrent epistaxis as well as of acute episodes of epistaxis requiring urgent medical consultation.

Non-invasive management of chronic recurrent epistaxis in HHT has focused to date on prevention of epistaxis events

through measures to maintain integrity of the nasal mucosa, such as humidification. The rationale for humidification is that endonasal crusting and airflow lead to damage of endonasal telangiectasia and secondary bleeding, whereas humidification should help prevent endonasal crusting. There are small case series of various topical medications, including lubricants (eg, saline, antibiotic ointments),^{26 27} as well as topical oestrogen cream/ointment²⁸ and antifibrinolytics,²⁹ with variable success in decreasing HHT-related epistaxis. There are insufficient published data to recommend one topical therapy over another; however, expert experience is that there is mild benefit from humidification and that the risk of topical lubricants and saline is very low.

Procedural therapies for chronic HHT-related epistaxis include endonasal laser, electrical or chemical coagulation techniques, replacement of the fragile endonasal mucosa by

Table 4 Level II uncontrolled case series of transcatheter embolisation (detachable coils, balloons, etc) for pulmonary arteriovenous malformations (PAVMs)

Study	Subjects/ PAVMs	Diagnosis of HHT	Mean (range) age (years)	Intervention	% with follow-up	Mean follow-up (months)	Post-embolisation outcome	Frequency post- embolisation outcome	Procedural complication	Frequency complication
Pollak <i>et al</i> 2006 ⁸⁵	155/415	95%	45 (7–77)	100%	100%	96	PAVM involution Reperfusion Growth small PAVMs	97% 3% 18%	Long term Pleurisy Angina TIA	0% 12% 2% 0.5%
Prasad <i>et al</i> 2004 ⁸⁶	54/306	94%	38	100%	100%	35	PAVM involution Reperfusion	93% 7%	Long term Pleurisy Paradoxical embolisation Device misplaced PAVM perforation TIA	0% 12% <0.5% 1% 1% 1%
Mager <i>et al</i> 2004 ⁸³	112/296	96%	45 (7–85)	100%	100%	62	Improved PaO ₂ pre–post Improved shunt (100% O ₂) pre–post Reperfusion Growth small PAVMs TIA Brain abscess	p<0.001 p<0.001 13% (patients) 8% (PAVMs) 14% (patients) 3% 2%	Pleurisy Angina Stroke TIA Paradoxical embolisation Surgical device removal Pulmonary hypertension Long term Pleurisy	13% 2% 1% 2% 2% 1% 0% 3% 5%
Gupta <i>et al</i> 2002 ⁸⁵	66/225	83%	44 (13–77)	100%	98%	27	Improved SpO ₂ pre–post Improved shunt (Tc99 MAA)	p<0.0001 p<0.0001	Angina Paradoxical embolisation Haemoptysis Long term Pleurisy Confusion Stroke Paradoxical embolisation Myocardial puncture Pleurisy Air embolisation Paradoxical embolisation DVT Pulmonary infarct	1% 1% 1% 0% 9% 3% 2% 1% 2% 31% 2% 4% 8% 8%
Dutton <i>et al</i> 1995 ⁹³	53/–	79%	41 (8–70)	100%	100%	Minimum 3	Improved SpO ₂ pre–post Improved shunt (Tc99 MAA)	p<0.0001 p<0.0001	Angina Paradoxical embolisation Haemoptysis Long term Pleurisy Confusion Stroke Paradoxical embolisation Myocardial puncture Pleurisy Air embolisation Paradoxical embolisation DVT Pulmonary infarct	5% 1% 1% 0% 9% 3% 2% 1% 2% 3% 2% 4% 8% 8%
Lee <i>et al</i> 1997 ⁸⁷	45/52 (Large PAVMs)	87%	42 (12–73)	100%	100%	56	Reperfusion	15%		
Chilvers <i>et al</i> 1990 ⁸⁴	15/–	73%	41 (13–63)	100%	100%	3	Improved SpO ₂ pre–post Improved shunt (100% O ₂) pre–post Improved peak work capacity pre–post Technical success Improved O ₂ pre–post TIA	p<0.05 p<0.001 60%		
White <i>et al</i> 1988 ⁸²	76/276	88%	36 (5–76)	100%	95%	Minimum 3	Technical success Improved O ₂ pre–post TIA	100% 77% 2%	Pleurisy Air embolisation Paradoxical embolisation DVT	10% 5% 3% 1%
Gershon <i>et al</i> 2001 ⁸⁸	7/13	100%	28 (24–34)	100%	100%	30	Technical success	100%	Pleurisy Fetal/childhood complications	29% 0%
Faughnan <i>et al</i> 2004 ⁸⁷	42/172 Paediatric	86%	12 (4–18)	100%	90%	84	Estimated fetal radiation dose Improved PaO ₂ pre–post Absence of PAVM complications (FOCAL group) Absence of PAVM complications (DIFFUSE group) Reperfusion	50–220 mRad p<0.003 100% 83% (2 deaths, 1 from brain abscess, 1 from lung transplant) 15%	Long-term Pleurisy Other pain Paradoxical embolisation Device misplaced Brachial plexus injury	0% 24% 2% 1% 0% 3% 1%

DVT, deep vein thrombosis; Tc99 MAA, shunt measurement using Technetium 99m-labelled albumin macroaggregates; TIA, transient ischaemic attack.

skin or buccal mucosa (dermoplasty), nasal artery embolisation and closure of the nasal cavity (known as Young's procedure). There have been no controlled or well-designed comparative studies of any of these procedures in HHT-related epistaxis, for either acute or chronic management. Case series and expert opinion of endonasal coagulation for treatment of moderate HHT-related epistaxis suggests that most types of endonasal coagulation appear to be low-risk procedures with subjective improvement in most patients.^{24 26 30–34} Chemical cautery (eg, AgNO₃) and CO₂ laser coagulation appear to have poorer outcomes in HHT and higher risk of intraoperative bleeding.²⁶ Septal dermoplasty has been reported, in one uncontrolled retrospective case series of patients with severe epistaxis, to decrease mean transfusion requirements and to improve subjective quality of life, but follow-up was available in <50% of treated patients³⁵ and complications included endonasal crusting and dryness. Young's procedure has been shown in a few small case series of patients with severe epistaxis to cause cessation of epistaxis and also to improve quality of life, although patients report side effects of chronic mouth breathing.^{36–38} Nasal artery embolisation is generally not useful for treatment of chronic epistaxis, since the effect is generally short term.^{39 40} Submucosal or intravascular endonasal injections of different substances have been reported,^{41 42} often with reduction in epistaxis but also reports of complications such as severe allergic reactions and blindness.⁴²

The expert panel agreed that, given the learning curve for surgical management of chronic HHT-related epistaxis, involvement of surgeons with expertise in HHT-related epistaxis may increase the likelihood of appropriate choice of treatment and improve outcomes of therapy. The expert panel also agreed that this applied to nasal surgery for indications other than epistaxis, in HHT patients.

Several medical treatments have been reported for HHT-related epistaxis, but there are no well-designed studies supporting their effectiveness and most studies have been limited by the lack of a validated sensitive outcome measure. There is one negative randomised placebo-controlled double-blind trial of oestrogen,⁴³ and another of tranexamic acid,⁴⁴ in which investigators were unable to demonstrate significant improvement in haemoglobin (primary outcome) but did demonstrate significant improvement in subjective epistaxis (secondary outcome).⁴⁴

There are no well-designed studies of the first-line management of acute epistaxis, although nasal packing is often used to control acute bleeding. However, endonasal telangiectasias are extremely fragile and therefore packing removal can cause rebleeding. This can be minimised with atraumatic packing—for example, using lubricated or pneumatic packing, the latter allowing insertion and removal of the packing in a deflated size. Low-pressure pneumatic packing may also minimise mucosal ischaemic damage. Two uncontrolled case series of embolisation,^{40 45} in patients with severe ongoing epistaxis despite packing, reported excellent immediate success rates (80–100%), but with early recurrence of epistaxis and risk of serious procedural complications (stroke, tissue necrosis).

The panel also discussed management when an HHT patient has an indication for antiplatelet or anticoagulant therapy. There are no published studies regarding the use of anticoagulants in HHT, but expert experience revealed a wide range of outcomes, with some HHT patients tolerating anticoagulation and others developing life-threatening bleeding.

Table 5 Therapeutic trials for gastrointestinal (GI) bleeding in hereditary haemorrhagic telangiectasia (HHT)

Study	Subjects	No with HHT	Mean (range) age (years)	Intervention	% with follow-up	Mean follow-up (months)	Post-treatment outcome	Frequency post-treatment outcome	Procedural complication	Frequency complication
Bown <i>et al</i> 1985, ¹⁰⁹ Case series	18, severe GI bleeding, transfusion dependent	8/18 (44%)	62 (42–74)	100% 2 APC	100%	14	Reduced transfusions No further transfusions	8/8 (100%) 3/8 (38%)	Perforation	0%
Gostout <i>et al</i> 1988, ¹¹¹ Case series	93, severe GI bleeding, transfusion dependent	10/93 (11%)	63	6 ND-YAG (mean 7 sessions) 100% ND-YAG (2–6 sessions)	100%	15	Reduced transfusions	3/8 (38%) 9/10 (90%)	Perforation Delayed bleeding	3/93 (3%) 5/93 (5%)
Sargeant <i>et al</i> 1993, ¹¹⁰ Case series	41, severe GI bleeding, transfusion dependent	9/41 (22%)	66 (55–81)	100% ND-YAG (repeated sessions)	100%	51	Reduced or stabilised number of transfusions Reduction in mean yearly transfusions pre-post	6/9 (67%) 8 (4–42) vs 4 (0–44)	Perforation Antral narrowing	1/41 (2%) 2/41 (4%)
Van Cutsem <i>et al</i> 1990, ¹⁰⁶ Placebo-controlled cross-over trial	10, severe GI bleeding from VMs, transfusion dependent	6/10 (60%)	65–89	100% ethinylestradiol + norethisterone versus placebo	100%	6	Reduced mean transfusions pre-post* No further bleeding	p<0.002 5/6	Death (MI) Feminising Vaginal bleeding DVT	1/10 (10%) 1/10 (10%) 2/10 (20%) 1/19 (5%)
Longacre <i>et al</i> 2003, ¹⁰³ Case series	43, HHT-related GI bleeding	43/43 (100%)	57 (33–78)	23/43 (53%) Medical therapy 19 ethinylestradiol/norethindrone 2 danacrine 2 aminocaproic acid	100%	18	Mean haemoglobin pre-post	8.6 vs 9.9 p=0.0018		

*Mean for all 10 patients (HHT and non-HHT). APC, argon plasma coagulation; DVT, deep vein thrombosis; MI, myocardial infarction; Nd-YAG, neodymium-doped yttrium aluminium garnet laser.

Recommendations

The expert panel recommends that physicians advise patients with HHT-related epistaxis to use agents that humidify the nasal mucosa to prevent epistaxis.	Level of evidence: III Strength of recommendation: weak Agreement: 94%
The expert panel recommends that for HHT-related epistaxis requiring surgical intervention, clinicians consider endonasal coagulation as a first-line treatment option. Clinical considerations: Endonasal coagulation should be applied carefully and with experience to avoid complications such as septal perforation (which often leads to worse epistaxis), even if it means repeating the intervention several times. If recurrent endonasal coagulation has not been effective and epistaxis is severe, then more invasive procedures, such as septal dermoplasty or Young's procedure, can be considered.	Level of evidence: III Strength of recommendation: weak Agreement: 93%
The expert panel recommends that clinicians refer HHT patients with epistaxis and who desire treatment to otorhinolaryngologists with HHT expertise for evaluation and treatment. Clinical considerations: Primary physicians are key players in the care of HHT patients, especially in the emergency situation. In the patient with epistaxis problematic enough to warrant consideration of treatment, consultation with an otorhinolaryngologist with HHT expertise should help guide the intervention choice, to maximise effectiveness and reduce risk, in this life-long rare disorder.	Level of evidence: III Strength of recommendation: weak Agreement: 87%
The expert panel recommends that, when considering nasal surgery for reasons other than epistaxis, the patient and clinician obtain consultation from an otorhinolaryngologist with expertise in HHT-related epistaxis. Clinical considerations: In the patient with HHT and an unrelated ENT problem requiring surgery, consultation with an otorhinolaryngologist with HHT expertise should help guide the procedural interventions to minimise risk of worsening epistaxis.	Level of evidence: III Strength of recommendation: weak Agreement: 100%
The expert panel recommends that the treatment for acute epistaxis requiring intervention include packing with material or products that have a low likelihood of causing rebleeding on removal (eg, lubricated low-pressure pneumatic packing). Clinical considerations: In order to perform atraumatic packing, the clinician can lubricate the packing or use pneumatic packing which allows insertion and removal of the packing in a deflated size. When pneumatic packing is used, low-pressure packing is preferable. This recommendation specifically addresses nasal packing performed by physicians, although the expert panel is aware that patients often choose to self-pack the nose.	Level of evidence: III Strength of recommendation: weak Agreement: 93%
The expert panel recommends that HHT-related epistaxis is not an absolute contraindication to anticoagulant/antiplatelet therapy. Anticoagulant/antiplatelet therapy can increase the risk of epistaxis, and the decision to use these agents should be based on the individual patient risk and benefits. Clinical considerations: HHT-related epistaxis will seldom, if ever, lead to sudden death, while the use of anticoagulants/antiplatelets may prevent catastrophic or life-threatening events. In most HHT patients in whom visceral sources for life-threatening haemorrhage (ie, significant PAVMs and CVMs) have been ruled out, a trial of anticoagulation can be considered if indicated. Referral to an otorhinolaryngologist with expertise in HHT should be considered, before the start of anticoagulation therapy, to create a prior treatment plan in the event of a catastrophic bleeding event and to consider preventive surgical procedures.	Level of evidence: III Strength of recommendation: strong Agreement: 100%

CEREBRAL VASCULAR MALFORMATIONS

Definition

The term CVM refers to a variety of vascular abnormalities, classified on the basis of morphology, including: (1) arteriovenous malformations (CAVMs) (including microAVMs measuring <1 cm in size); (2) cavernous malformations; (3) venous angiomas/developmental venous anomalies (DVAs); (4) capillary telangiectasias, enlarged capillary-sized vessels; (5) vein of Galen malformations; (6) high-flow pial fistulae (arteriovenous fistulae (AVFs)); and (7) mixed malformations.⁴⁶ All of these types of CVMs can be found in HHT patients, although typically HHT is associated with CAVMs, AVFs, microAVMs and telangiectasias.⁴⁷

Background

Approximately 23% of HHT patients will harbour a CVM.^{48–50} The rationale for screening for CVMs in HHT is that screening will detect a treatable CVM before the development of a life-threatening or debilitating complication. We therefore reviewed the evidence regarding complications of CVMs, the performance of screening tests, and the effectiveness of treatment for CVMs. Given the rarity of HHT-related CVMs, most of the evidence reviewed relates to the more common sporadic CVMs.

The bleeding risk of CVMs in HHT has been estimated retrospectively at ~0.5% per year,⁵¹ although there are no prospective natural history studies. In larger series of sporadic

Table 6 Screening studies for liver vascular malformations (VMs) in hereditary haemorrhagic telangiectasia (HHT)

Study	Number	Population	% with HHT	Type of study	Test	Findings for liver VMs	Frequency of abnormality in liver VMs	Prevalence of liver VMs detected	Gold standard
Memeo <i>et al</i> 2005 ¹¹²	105	HHT, consecutive patients	100%	Screening Descriptive	CT	Telangiectasia CVMs AV shunt AP shunt AV & AP shunt Perfusion abN PHT	50/78 (64%) 20/78 (26%) 40/78 (51%) 16/78 (21%) 22/78 (28%) 46/78 (59%) 46/78 (59%)	78/100 (78%)	No
Ravard <i>et al</i> 2004 ¹¹³	24 24	HHT, consecutive patients controls	100%	Screening Descriptive comparative	CT	Dilated HA Telangiectasia AV shunt AP shunt	16/16 (100%) 12/16 (75%) 5/16 (31%) 3/16 (19%)	16/24 (67%)	No
Buscarini <i>et al</i> 2004 ¹¹⁴	346	HHT, members of HHT families	221 (64%)	Screening Descriptive	Doppler US	Mild Moderate Severe	11/92 (12%) 70/92 (76%) 11/92 (12%)	92/221 (41%)	No
Buscarini <i>et al</i> 1997 ¹¹⁵	73	HHT, one family	40 (55%)	Screening Descriptive	Doppler US	Mild Moderate Severe	3/13 (23%) 7/13 (46%) 7/13 (46%)	13/40 (32%)	Angio12/13
Ocran <i>et al</i> 2004 ¹¹⁶	22	HHT consecutive patients	100%	Screening Descriptive	Doppler US	Dilated HA Dilated intra HA AV shunts	14/16 (88%) 15/16 (94%) 16/16 (100%)	16/22 (73%)	No

Clinical liver VMs, patients with clinical signs or symptoms of liver VMs.

abN, abnormal; AP, arterioportal; AV, arteriovenous; CVM, confluent vascular malformations; HA, hepatic artery; PHT, portal hypertension; PV, portovenous; US, ultrasonography.

Table 7 Case series of treatment for liver vascular malformations (VMs) in hereditary haemorrhagic telangiectasia (HHT)

Study	No	Clinical types	Treatment	Median follow-up (months)	Outcomes of treatment	Frequency of outcomes	Complications	Frequency of complications
Lerut <i>et al</i> 2006 ¹²⁷	40	14 HF	Trans	58	5-year survival	83%	Intraoperative bleed*	1/40 (3%)
		12 BIL			HF improved	18/24 (75%)	GI bleed*	1/40 (3%)
		5 PHT			HF Stable	5/24 (21%)	CHF*	1/40 (3%)
		6 HF+BIL			HF alone Death	1/24 (4%)	Acute rejection*	1/40 (3%)
		2 HF+PHT			BIL +/- HF Death	4/18 (22%)	Chronic rejection*	1/40 (3%)
		1 HF+PHT+BIL			PHT +/- HF Death	3/8 (38%)	Graft failure*	1/40 (3%)
							Cerebral bleed*	1/40 (3%)
Chavan <i>et al</i> 2004 ¹²⁵	15	11 HF	Staged HA embolisation	28	Alive	11/15 (73%)	Non-fatal complications	24/40 (60%)
		5 Steal			HF alive	10/11 (91%)	Hepatic necrosis*	1/15 (7%)
		4 PHT			HF improved	10/11 (91%)	Cholangitis/cholecystitis*	3/15 (20%)
					Steal alive	5/5 (100%)		
					Steal improved	5/5 (100%)		
					PHT alive	2/4 (50%)		
					PHT improved	2/4 (50%)		
Azoulay <i>et al</i> 2002 ¹²⁶	6	3 BIL	Transplant	57	Alive	4/6 (67%)	GI bleeding*	1/6 (17%)
		2 PHT			BIL alive	3/3 (100%)	Peritonitis*	1/6 (17%)
		1 HF+BIL			PHT alive	1/2 (50%)		
					HF+BIL alive	0/1 (0%)		

*Causing death.

CHF, congestive heart failure; GI, gastrointestinal; HA, hepatic artery; HF, high-output heart failure; PAVM, pulmonary arteriovenous malformation; PHT, portal hypertension; BIL=biliary.

CAVMs,⁵² the annual rate of rupture is 2–4%/year.⁵² On the basis of case series, CAVMs and AVFs appear to have a more aggressive natural history, while cavernous malformations (CM), capillary telangiectasias and DVAs, also reported to occur in HHT,⁴⁹ appear to have a more benign natural history.^{12 48 51 53 54} There are several case series and reports of catastrophic haemorrhagic sequelae of CVMs and spinal AVFs occurring during childhood.^{50 55–58} Rarely, spontaneous resolution of CVMs has been reported.^{59 60}

The typical imaging features of HHT CVMs include the presence of either multiple, cortical, micro AVMs or AVFs harbouring single feeding arteries and single draining veins.^{12 53 54} Catheter angiography remains the 'gold standard' for diagnosis of most types of CVMs, but carries a 0.5% risk of permanent stroke.⁶¹ MRI is considered to be a safe, non-invasive modality to screen for CVMs, but unfortunately there are no screening studies assessing its performance in HHT. MRI screening studies for non-HHT CVMs have been limited by small size, retrospective design and lack of blinding to clinical status, but suggest sensitivity of 80–95% for medium to large sized CVMs.^{62–64} MRI is less sensitive for the detection of micro AVMs,⁶⁴ but the addition of contrast enhancement (gadolinium for patients >2 years of age) to MRI sequences increases the sensitivity for microAVMs. The inclusion of sequences designed to detect blood products (currently gradient echo sequences) also increases the sensitivity of MRI for microAVMs and signs of asymptomatic haemorrhage.⁵⁵ 'False-positive' results may occur when other types of CVMs are encountered including telangiectasias which have a favourable natural history⁴⁹ and for which no further invasive imaging is required. Transcranial Doppler ultrasonography (US) has also been used to screen for CVMs,^{65 66} with reported sensitivity of ~80% for medium to large-sized CVMs, but studies are limited by sample size and design. No evidence exists for follow-up screening after an initial negative study, as there is no evidence to suggest that adult patients with HHT develop new CVMs.

MRI provides a relatively safe, sensitive testing modality to identify CVMs in children.⁶⁷ While MRI itself poses little risk, the expert panel acknowledges the risk related to sedation/anaesthesia of children for diagnostic procedures. Of greatest concern is the risk of respiratory depression, but this should be minimised with appropriate cardiorespiratory monitoring. No

evidence exists at this time to recommend follow-up screening after an initial negative study during childhood, but consideration should be given to one adulthood MRI following initial negative childhood MRI.

The expert panel agreed that CVM obliteration is required to effectively eliminate the future risk of haemorrhage. Although treatment may provide a large relative risk (RR) reduction for cerebral bleeding, procedural risks are significant. There are no published studies of the efficacy or safety of any form of treatment of CVMs in HHT patients. However, several large case series (>200 patients, mostly single-centre) of embolisation, microsurgery and stereotactic radiation in non-HHT CAVMs show widely ranging effectiveness for each modality.^{49 54 56 68–78}

On the basis of this, as well as expert experience, the expert panel agreed that effective treatment strategies include embolisation, microsurgery and stereotactic radiation, or combinations of these. With the rarity of CVMs and the associated risks of treatment, the expert panel agreed that each case should be managed in an individualised manner and decisions about invasive testing and therapy should occur at centres with significant experience and expertise in all treatment modalities. Although there is no evidence regarding differences in outcomes according to expertise in management of these cases, the expert panel agreed that centres with experience in HHT-related CVMs will be more aware of important issues related to the care of HHT patients and likely to have better outcomes of surgical and other procedures.

CVMs occur in infants and children with HHT.^{12 47 50 57 79 80} Before the age of 6 these malformations tend to be high-flow pial fistulae (cerebral or spinal cord AVFs).⁴⁷ Expert opinion is that these malformations have a more aggressive natural history than nidus-type CAVMs, including presenting events such as intracerebral haemorrhage, cognitive deficit, cardiac insufficiency, epilepsy and hydrocephalus.^{12 47 79 80} Embolisation or microsurgical obliteration of these high-flow pial fistulae in children may therefore be of significant benefit when performed by a neurovascular centre with expertise in these techniques in children.

There is no evidence to guide the management of CVMs during pregnancy and delivery, as there is no good evidence regarding the risk of CVM complications or treatment during pregnancy and delivery.

Recommendations

<p>The expert panel recommends that the clinician screen adult patients with possible or definite HHT for CVMs. Clinical considerations: Dissension resulted primarily from the lack of evidence of treatment effectiveness for asymptomatic CVMs in HHT and therefore the lack of evidence for benefit of screening. The specifics regarding screening method are detailed in the next recommendation. There is no evidence for any role for repeat MRI screening in adults, after an initial negative study. The likelihood of detecting a CVM will be less in patients with only a 'possible' diagnosis of HHT, but screening in these patients may be reasonable if the diagnosis of HHT cannot be ruled out genetically. The expert panel could not generate a recommendation regarding screening for spinal AVFs, given their rarity and the absence of evidence. However, if screening for spinal AVFs is being considered in children with HHT, a sagittal T2 MRI scan of the spine would be appropriate.</p>	<p>Level of evidence: III Strength of recommendation: weak Agreement: 77%</p>
<p>The expert panel recommends the use of MRI for CVM screening in adults with possible or definite HHT using a protocol with and without contrast administration and using sequences that detect blood products, to maximise sensitivity. Clinical considerations: If patients have received previous embolisation, coil compatibility with MRI must be confirmed before MR examination. The expert panel acknowledges that the optimum age for adult screening remains unknown, but felt that age 18 was appropriate as patients enter adulthood. In the presence of a negative MRI result in adulthood, no further screening tests are suggested. There may be additional benefits to performing an MRI at initial assessment, in the detection of infarcts and other central nervous system complications of HHT.</p>	<p>Level of evidence: III Strength of recommendation: weak Agreement: 100%</p>
<p>The expert panel recommends that the clinician screen children with possible or definite HHT for CVMs in the first 6 months of life (or at time of diagnosis) with an unenhanced MRI, and refer all patients with an MRI positive for these lesions to a centre with neurovascular expertise for consideration of invasive testing and further management. Clinical considerations: Dissension resulted primarily from the lack of evidence of treatment effectiveness for asymptomatic CVMs in HHT and therefore the lack of evidence for benefit of screening, as well as greater risk of screening in children. When MR screening is performed with the use of sedation and anaesthesia in young children, it is necessary to monitor cardiorespiratory parameters during the procedure and to provide an equivalent standard of care to that provided in an operating room. The technique used to sedate/anaesthetise infants for MRI should be performed in accordance with local expertise and no undue risk taken to obtain such a screening test. The MRI would generally be planned at the time of HHT diagnosis, preferably before 6 months of age when the risk/benefit ratio would be optimal.</p>	<p>Level of evidence: III Strength of recommendation: weak Agreement: 64%</p>
<p>The expert panel recommends that adults presenting with an acute haemorrhage secondary to a CVM be considered for definitive treatment in a centre with neurovascular expertise.</p>	<p>Level of evidence: III Strength of recommendation: strong Agreement: 94%</p>
<p>The expert panel recommends that all other adults with CVMs be referred to a centre with neurovascular expertise to be considered for invasive testing and individualised management. Clinical considerations: The expert panel recognises that asymptomatic CVMs discovered during screening of HHT patients may carry a more favourable natural history. These patients should be managed on an individualised basis. Since some CVMs may carry a favourable natural history, referral to a centre with neurovascular expertise before invasive imaging (catheter angiography) is performed may minimise unnecessary testing.</p>	<p>Level of evidence: III Strength of recommendation: strong Agreement: 84%</p>
<p>The expert panel recommends that pregnant women with suspected or confirmed HHT harbouring an asymptomatic CAVM during pregnancy have definitive treatment of their CAVM deferred until after delivery of the fetus. The expert panel recommends that the delivery of the fetus follow obstetrical principles.</p>	<p>Level of evidence: III Strength of recommendation: weak Agreement: 80%</p>

PULMONARY ARTERIOVENOUS MALFORMATIONS

Background

PAVMs are present in 15–50% of people with HHT and have been associated with life-threatening complications, as previously reviewed.^{81–82} The rationale for screening HHT patients for PAVMs is that screening will detect a treatable PAVM before the development of a life-threatening or debilitating complication. We therefore reviewed the evidence regarding complications of PAVMs, the performance of screening tests, and the effectiveness of treatment for PAVMs.

PAVMs have been shown to be associated with disabling and life-threatening complications, such as stroke, transient ischaemic attack (TIA), cerebral abscess, massive haemoptysis and spontaneous haemothorax^{81–83–86} in retrospective series. The neurological complications are presumed to occur via paradoxical embolisation through PAVMs, whereas the haemorrhagic complications occur due to spontaneous PAVM rupture. These complications have been demonstrated in largely adult series of HHT patients, although they have also been demonstrated in a paediatric HHT series,⁸⁷ albeit smaller in size. There have also been small series reporting these same complications during pregnancy,^{88–89} and the expert panel agreed that the complication risk appears to be greater during pregnancy.

Since clinical symptoms and signs of PAVMs are often absent before the development of complications, a number of screening tests have been studied, including physiological methods of measurement of intrapulmonary shunt as well as multiple different imaging modalities. In the one comparative study (table 3), transthoracic contrast echocardiography with agitated saline (TTCE) has been demonstrated to have the best combination of high sensitivity⁸² and low risk^{90–91} among

screening tests for PAVMs in adults with HHT, when compared with the reference standard tests (CT and pulmonary angiography). There have been no comparative screening studies for PAVMs in children with HHT.

Embolisation has been shown in several non-controlled series^{83–85–92–96} to be efficacious and to have a good safety profile, with only rare PAVM-related complications during 5–10 year follow-up (table 4). In the short term, these studies showed very high rates of immediate technical success and significant improvement in oxygenation (table 4). Longer term after embolisation, reperfusion did occur in up to 15%, and growth of small PAVMs in up to 18% (table 4), but clinical complications were very rare. These series primarily reported outcomes for treatment of PAVMs with feeding artery diameter of 3 mm or greater, although expert experience suggests that embolisation of smaller PAVMs (2–3 mm) has similar outcomes. The safety and efficacy were similar for large PAVMs in adults⁹⁷ as well as for PAVMs in children,⁸⁷ although there is little experience with embolisation of PAVMs in children under the age of 4 years. There is only one small case series of embolisation during pregnancy,⁹⁸ suggesting reasonable safety. Although there is no evidence regarding differences in outcomes according to expertise in embolisation of PAVMs, the expert panel agreed that centres with experience in this procedure are more likely to have better outcomes than inexperienced centres.

The long-term follow-up of PAVMs is described using CT of the thorax. This allows detection of reperfusion by non-involution of the aneurysmal sac ~1 year after embolisation and also detection of growth of small residual PAVMs, which are common in HHT.⁸⁵ TTCE has been shown to be not useful after embolisation, given that it remains positive in ~90% of patients after embolisation.⁹⁹

Recommendations

The expert panel recommends that clinicians screen all patients with possible or confirmed HHT for PAVMs.

Clinical considerations: Screening should be performed at the time of initial clinical evaluation for HHT. Although less evidence exists in children, the expert panel included children in the screening recommendation, since they are also at risk of life-threatening complications, and treatment appears to be similarly effective.

In patients with negative initial screening, repeat screening should be considered after puberty, after pregnancy, within 5 years preceding planned pregnancy, and otherwise every 5–10 years.

The expert panel recommends that clinicians use TTCE as the initial screening test for PAVMs.

Clinical considerations: Screening should be performed by clinicians with significant expertise in HHT, usually in an HHT centre of excellence, to achieve the accuracy and low risks reported in the literature. TTCE is considered positive if there is detection of any bubbles in the left atrium. Positive screening should be confirmed with unenhanced multidetector thoracic CT with thin-cut (eg, 1–2 mm) reconstructions. CT was not recommended as a screening test because of the associated radiation exposure, but could be considered for screening in centres without expertise in TTCE for PAVM screening.

In children, the choice of screening tests should be decided on a case-by-case basis, but may include clinical evaluation (for cyanosis, dyspnoea, clubbing), supine and upright pulse oximetry, chest radiography and/or TTCE.

The expert panel recommends that clinicians treat PAVMs with transcatheter embolotherapy.

Clinical considerations: The recommendation applies to all adults with PAVMs and children with symptomatic PAVMs. The decision to treat in asymptomatic children (no dyspnoea, no exercise intolerance, no growth delay, no cyanosis or clubbing, no previous complication) should be made on a case-by-case basis. The selection of PAVMs for embolisation is based on feeding artery diameter, generally 3 mm or greater, although targeting PAVMs with feeding artery diameter as low as 2 mm may be appropriate.

This procedure should be performed by clinicians with significant expertise in embolising PAVMs, usually in an HHT centre of excellence, to achieve the effectiveness and low risks reported in the literature. This is particularly relevant when considering embolisation in rare or higher risk situations, such as during pregnancy and in patients with mild–moderate pulmonary hypertension. The panel agrees there is no role for surgical management of PAVMs, other than in the management of life-threatening bleeding in a centre where embolisation expertise is unavailable.

The expert panel recommends that clinicians provide the following long-term advice to patients with documented PAVMs (treated or untreated):

1. **Antibiotic prophylaxis for procedures with risk of bacteraemia**
2. **When intravenous access is in place, take extra care to avoid intravenous air**
3. **Avoidance of SCUBA diving**

Clinical considerations: The rationale for recommending prophylactic antibiotics for bacteraemic procedures in people with PAVMs is based on expert opinion that cerebral abscess is common in these patients (~10% before PAVM diagnosis), that cerebral abscess in these patients occurs primarily as a complication of bacteraemic procedures, the fact that cerebral abscess is associated with considerable morbidity and mortality, and that this precaution is low risk. The American Heart Association guidelines for prevention of bacterial endocarditis should be followed for choice of antibiotics.

Similarly, careful avoidance of intravenous air bubbles is recommended to prevent cerebral air embolism, and this could include an in-line filter. There are only theoretical arguments for avoidance of SCUBA diving suggesting that there may be an increased risk of complications of decompression in patients with PAVMs.

These precautions should be followed life-long, regardless of size of PAVMs, even once PAVMs are treated. These precautions should also be considered in HHT patients in whom PAVMs have not been excluded or in whom microscopic PAVMs are suspected (eg, detected on TTCE but not detectable on CT).

The expert panel recommends that clinicians provide long-term follow-up for patients who have PAVMs, in order to detect growth of untreated PAVMs and also reperfusion of treated AVMs.

Clinical considerations: Follow-up allows the identification of embolised PAVMs that have reperfused and other PAVMs that have grown large enough to be considered for embolisation. Multidetector thoracic CT with thin-section reconstruction (1–2 mm) should be undertaken within 6–12 months after embolisation and then approximately every 3 years after embolisation.

For patients with only small untreated PAVMs and in patients with suspected microscopic PAVMs (eg, detected on TTCE but not detectable on CT), the follow-up period should be determined on a case-by-case basis (approximately every 1–5 years) with CT (as above), with consideration for limiting radiation exposure.

Level of evidence: III
Strength of recommendation: strong
Agreement: 96%

Level of evidence: II
Strength of recommendation: weak
Agreement: 96%

Level of evidence: II
Strength of recommendation: strong
Agreement: 96%

Level of evidence: III
Strength of recommendation: weak
Agreement: 87%

Level of evidence: II
Strength of recommendation: strong
Agreement: 100%

GASTROINTESTINAL BLEEDING

Background

Although 80% of patients with HHT have gastric or small intestinal telangiectasia¹⁰⁰ on endoscopy or capsule examination, only 25–30% of patients will develop symptomatic GI bleeding,^{1 2 101 102} which usually does not present until the 5th or 6th decades of life. Patients rarely develop significant GI bleeding before 40 years of age.^{1 2 101 102} Women are affected with GI bleeding in a ratio of 2–3:1.^{103 104}

Patients with HHT and GI bleeding may or may not be symptomatic, as the bleeding is usually in a slow, chronic and intermittent fashion, often without notable melaena. Patients often have few symptoms until they become anaemic. In severe cases, HHT GI bleeding causes morbidity, dependency on blood transfusions, and increased mortality.¹⁰³ Severity of GI bleeding in HHT is generally based on severity of the anaemia. Gastric and duodenal telangiectasias are more common than colonic telangiectasias and contribute more to overall GI bleeding and chronic anaemia in HHT patients.¹⁰⁵

At present, endoscopic evaluation is considered the gold standard test for evaluation of GI bleeding in HHT patients. Although the majority of patients with HHT will have GI telangiectasias, the utility of endoscopic evaluation is in the anaemic or iron-deficient patient. The presence and number of gastric and duodenal telan-

giectasias have been shown to predict the presence and number of jejunal telangiectasias,¹⁰⁴ and therefore, for diagnostic purposes, an oesophagogastroduodenoscopy is sufficient in most cases.

Management of GI bleeding in HHT involves treatment of the iron-deficiency/anaemia and therapies to reduce GI bleeding. Treatment of anaemia and iron deficiency includes aggressive iron replacement and blood transfusions as necessary. There are no studies of iron replacement in HHT, but experts agree that oral iron supplementation may be sufficient in some patients, although consideration of intravenous iron supplementation may be necessary in more severe cases. There have been no studies of erythropoietin therapy in HHT, but it is sometimes considered in severe cases, in combination with iron, in an attempt to accelerate treatment of the anaemia.

Current treatment options to reduce chronic GI bleeding in HHT include hormonal therapy (oestrogen/progesterone preparations or danacrine), antifibrinolytics (aminocaproic acid or tranexamic acid), other medications reported only as isolated case reports (tamoxifen, interferon, thalidomide and sirolimus) and endoscopic therapy. There is one small double-blind placebo-controlled cross-over trial¹⁰⁶ (table 5) of combination hormonal therapy (ethinylestradiol 0.05 mg plus norethisterone 1 mg) versus placebo, each for 6 months, in 10 patients with transfusion-dependent severe GI bleeding. Five of the six HHT patients had no further GI bleeding while receiving treatment,

and, in the overall group, there was a significant decline in transfusion requirements. In a retrospective case series¹⁰³ of 43 HHT patients with GI bleeding, median haemoglobin improved significantly (8.6 to 9.8 mg/dL, $p=0.0018$) for the 23 patients treated with medical therapy (ethinylestradiol/norethindrone in 19, danacrine in two, and aminocaproic acid in two). Although there are only other individual case reports¹⁰⁷ of danacrine in HHT GI bleeding, it may be a reasonable alternative to oestrogen/progesterone therapy in male patients, as it does not have feminising effects. There is only individual case report evidence for antifibrinolytics for HHT-related GI bleeding,¹⁰⁸ but there is expert experience suggesting benefit in these patients. Overall, there is insufficient evidence to recommend any medical treatment as first-line therapy in these patients, given the potential side effects; however, there may be a role for these agents when iron replacement is insufficient to control anaemia.

There are small case series (table 5) and expert experience suggesting that local endoscopic therapy, using argon plasma coagulation (APC) or ND-YAG laser, may be beneficial in reduction of HHT-related GI bleeding. In three small case series^{109–111} of repeated ND-YAG therapy, transfusion requirements declined in more than 50% of patients. The expert panel agreed that, although the reported series were primarily of the use of ND-YAG

laser, APC is the most effective method of endoscopic therapy currently available. Overall, there is insufficient evidence to recommend endoscopic therapy as first-line therapy in HHT-related GI bleeding; however, there may be a role for endoscopic therapy when iron replacement is insufficient to control anaemia. There is no evidence or experience supporting cauterisation of colonic telangiectasia, or for surgery or transcatheter embolotherapy in the routine management of HHT-related GI bleeding. Although there is no evidence regarding differences in outcomes according to expertise in endoscopic management of GI bleeding in HHT, the expert panel agreed that clinicians with experience in HHT-related GI bleeding will better prepared to make decisions about when to treat GI telangiectasia in HHT and are likely to achieve better outcomes for these procedures.

There is no evidence of any benefit from altering nutrition or lifestyle, or screening for *Helicobacter pylori* in patients with HHT-related GI bleeding. HHT patients with GI bleeding should avoid anticoagulants and drugs that alter platelet function. However, when other comorbidities require use of these drugs, expert experience is that these can often be tolerated, especially when doses are kept as low as possible.

Recommendations

The expert panel recommends that all patients over 35 years should have annual measurements of haemoglobin or haematocrit levels because of the increased risk of significant GI bleeding with age. Directed endoscopic evaluation should be undertaken in patients with anaemia disproportionate to epistaxis. The expert panel advises against GI endoscopic investigations in patients with HHT and no evidence of anaemia.

Level of evidence: III
Strength of recommendation: strong
Agreement: 89%

Clinical considerations: A blood test for haemoglobin and ferritin should be drawn as part of the annual physical examination with the family physician. The age of 35 is preferred, as few people begin having problems with GI bleeding before 40 and this allows measurement of baseline haemoglobin to track GI losses. Patients over 50 years of age, particularly women, are considered at higher risk of HHT-related GI bleeding. Of note, fecal occult blood testing can be falsely positive due to GI transit of swallowed epistaxis and therefore this test is not useful. **In HHT patients with suspected GI bleeding, the expert panel recommends that an upper endoscopy be the first diagnostic test. The diagnosis of HHT-related GI bleeding is made in the presence of anaemia and endoscopic visualisation of characteristic GI telangiectasia in combination with clinical judgement.**

Level of evidence: III
Strength of recommendation: strong
Agreement: 90%

Clinical considerations: HHT patients with anaemia should be referred to clinicians with HHT expertise for endoscopic visualisation to identify the source of their GI bleeding. Since the majority of the bleeding occurs in the stomach and proximal small intestine, an upper endoscopy is usually sufficient to diagnose upper GI telangiectasias. The clinician must be aware that the presence of characteristic GI telangiectasias does not necessarily indicate that they are the source of anaemia or GI bleeding and does not preclude other sources of bleeding. Wireless capsule endoscopy may be considered when direct endoscopic visualisation of the GI tract with upper and lower endoscopies does not adequately explain the anaemia. It is not common for the GI telangiectasias in HHT to cause massive, acute GI bleeding. In HHT patients with acute GI bleeding therefore other causes should be considered first as in non-HHT patients.

The expert panel recommends oral and/or intravenous iron supplementation as first-line therapy for mild anaemia and chronic bleeding secondary to HHT-related telangiectasia.

Level of evidence: III
Strength of recommendation: weak
Agreement: 97%

Clinical considerations: For replenishment of iron stores, the clinician can select the oral iron formulation that is best tolerated by the patient, as long as the dosing is adequate. Often patients will require 6–12 months of, for example, ferrous fumarate 300 mg once daily, but the dose and duration are adjusted according to the patient's haemoglobin and ferritin response. If one oral iron preparation is not tolerated, then a trial of another should be considered. If oral iron replacement is insufficient or not tolerated, then intravenous iron, preferably iron sucrose, should next be considered. Haemoglobin and ferritin levels should be monitored regularly, with the frequency depending on the severity of the anaemia, until both the anaemia and iron deficiency are resolved. Some patients may require long-term or life-long iron supplementation. If additional therapy with erythropoietin is considered, patients should be screened and treated for PAVMs before therapy is initiated, because of the thrombogenic risk of erythropoietin.

The expert panel recommends against the use of multiple attempts at local endoscopic therapy because of the additive risk of adverse events without corresponding benefits.

Level of evidence: III
Strength of recommendation: weak
Agreement: 90%

Clinical considerations: The HHT patient with anaemia not responding to iron supplementation should be referred to a clinician with expertise in endoscopic treatment of HHT patients, for consideration of one or two attempts to locally cauterise visible telangiectasias. This is most likely to be beneficial when performed with APC and by an endoscopist with related experience. Since the majority of the bleeding occurs in the stomach and proximal small intestine, cauterisation during upper endoscopy is most likely to be beneficial. If initial endoscopic cauterisation is not beneficial in a given patient, further multiple attempts at endoscopic cauterisation of GI telangiectasias are unlikely to be beneficial and yet will expose the patient to unwarranted risk. Specialised endoscopy, such as enteroscopy, or performing endoscopy during surgery is not routinely used for treatment of HHT-related bleeding, but may be considered in cases where treatment of more distal lesions is being considered (distal to the duodenum and proximal to the terminal ileum).

The expert panel recommends that the clinician consider systemic hormonal or antifibrinolytic therapy in selected HHT patients to limit ongoing GI blood loss.

Level of evidence: III
Strength of recommendation: weak
Agreement: 100%

Clinical considerations: When unable to maintain the haemoglobin at an acceptable level, that is, 9–10 g/dl or higher, with oral and/or intravenous iron, then the clinician should consider hormonal therapy or antifibrinolytic therapy, in patients without contraindications. The usual dosing for hormonal therapy in HHT, based on the one study,¹⁰⁶ is daily ethinylestradiol 0.050 mg and norethisterone 1 mg. Danacrine 200 mg orally twice a day for 6 weeks followed by 200 mg daily in responders may be a beneficial alternative in men, with fewer side effects. Another alternative is antifibrinolytic therapy, with aminocaproic acid or tranexamic acid. Aminocaproic acid is usually started at 500 mg orally four times a day and increased to a maximum of 2500 mg orally four times a day (10 g/day). Tranexamic acid is usually started at 500 mg orally every 8–12 h and increased to 1–1.5 g orally every 8–12 h. Patients should be screened and treated for PAVMs before initiation of either of these systemic therapies, given the thrombogenic risk.

LIVER VASCULAR MALFORMATIONS

Background

Although a consensus guideline had been recently published for the diagnosis and management of liver VMs in HHT,⁴ to be consistent, we elected to include this topic in the present guidelines. As such, we followed the same guidelines process for liver VMs as for other aspects of HHT and reviewed the evidence regarding diagnosis and treatment of liver VMs in HHT. The liver VMs recommendations reported in the present guidelines do not differ significantly from the previous guidelines.⁴

Liver VMs are present in 32–78% of HHT patients^{112–116} (table 6). Although there are no published natural history data regarding liver VMs in HHT, it appears that symptoms occur in only about 8% of the patients with HHT and liver VMs.^{114 117} The clinical presentations of liver VMs include high-output heart failure, portal hypertension and biliary necrosis.¹¹⁸

In patients who have symptoms suggestive of liver VMs,¹¹⁸ it is important to establish the diagnosis of liver VMs for therapeutic and prognostic purposes. The diagnosis of liver VMs may also assist in the clinical diagnosis of HHT, since visceral involvement is one of the clinical diagnostic criteria.¹¹ Several different imaging modalities have been reported and studied for the screening and diagnosis of liver VMs in HHT. From the least invasive to the most invasive, these tests are Doppler ultrasonography, MRI, triphasic spiral CT and mesenteric angiography. Doppler US is the least invasive test, requiring no contrast and being associated with no procedural complications. There is little experience with MRI, which does require MR-contrast administration, but involves no radiation exposure. CT is associated with radiation exposure and risk of contrast allergy. Mesenteric catheter angiography has traditionally been considered the diagnostic gold standard, but is the most invasive, and is rarely used.

Typical angiographic findings have been described in several small case series of HHT patients,^{119–121} including telangiectasias, confluent VMs, hepatic artery dilatation and shunting (arterioportal, arteriovenous and/or portovenous). Triphasic CT findings have been similarly described.^{112 113 117} Several case series of Doppler US in HHT patients have demonstrated hepatic artery dilatation, elevated hepatic artery flow, and

intrahepatic hypervascularity.^{113 114 116 122 123} There have been no well-designed studies reporting sensitivity and specificity of any of these tests, although the positive predictive value of Doppler US appears to be near 100%.^{115 123} Screening studies of HHT patients (table 6) have reported a prevalence of liver VMs of 32–72% with Doppler US^{114–116} and 67–78% with triphasic CT.^{112 113} In none of these studies was a diagnostic gold standard (angiography) uniformly performed; however, these prevalences are all much higher than the symptomatic rate (8%), suggesting that these tests are sensitive. There are no screening studies in children.

Histological diagnosis from liver biopsy tissue, although quite characteristic,¹¹⁸ is unnecessary, given typical imaging findings, and risky in patients with liver VMs. Focal nodular hyperplasia occurs more often in HHT than in the general population,¹²⁴ but can be diagnosed through imaging, without biopsy.

There are three uncontrolled case series (table 7) of treatments of liver VMs, specifically hepatic artery embolisation and liver transplantation. Hepatic artery embolisation has the objective of reducing arteriovenous or arterioportal shunting by embolising branches of the hepatic artery. Embolisation appears to be effective in improving symptoms related to high-output heart failure and mesenteric steal syndrome¹²⁵; however, the effect is transient and symptoms generally recur. More importantly, ischaemic complications (ischaemic cholangitis, ischaemic cholecystitis and/or hepatic necrosis) leading to transplant or death occur in ~30% of the treated cases, including 50% of treated portal hypertension cases.¹²⁵ The 2-year survival with embolisation was ~73%. The expert panel agreed that the risk of post-embolisation ischaemia would probably be greatest in patients with biliary presentation of liver VMs. With liver transplantation, symptoms resolved in the majority of patients.^{126 127} Liver transplantation is associated with high blood transfusion requirements, prolonged hospital stay, and a relatively high rate of postoperative complications. However, the reported 5-year survival rate of 83% in the larger series¹²⁷ compared favourably with overall survival rates for liver transplantation.

Recommendations

The expert panel recommends that in patients with HHT and abnormal liver enzymes and/or a clinical picture suggestive of complications of liver VMs:

- ▶ High output heart failure (exertional dyspnoea, orthopnoea, oedema)
- ▶ Portal hypertension (variceal haemorrhage, ascites)
- ▶ Biliary (jaundice, fever, abdominal pain)
- ▶ Portosystemic encephalopathy
- ▶ Steal syndrome (intestinal ischaemia)
- ▶ Doppler US or CT should be offered as a baseline test to confirm liver VMs

Clinical considerations: The confirmation of the diagnosis of liver VMs in symptomatic patients will help prevent misdiagnosis and allow the clinician to provide appropriate therapy and follow-up. Either Doppler US or CT scan can be used to confirm the diagnosis, although Doppler US is lower risk. In centres where expertise in the interpretation of Doppler US for diagnosis of liver VMs is lacking, triphasic helical CT may be appropriate. Further, more invasive, testing may be performed depending on severity of symptoms and type of clinical presentation. For example, in patients with related heart failure, right heart catheterisation with measurement of cardiac index and pulmonary pressures can help guide therapy and establish baseline values. In those with symptoms of heart failure versus portal hypertension, hepatic vein catheterisation with measurement of hepatic venous pressure gradient can guide therapy. For patients with abdominal pain suggestive of mesenteric ischaemia, angiography might clarify the diagnosis.

To clarify the diagnosis of HHT, the expert panel recommends screening for liver VMs, using Doppler US, in patients with 1 or 2 HHT diagnostic criteria and in whom genetic testing is either inconclusive or unavailable

Clinical considerations: The rationale for recommending screening for liver VMs to clarify the diagnosis of HHT is based on the fact that visceral involvement is one of the diagnostic criteria for HHT, and therefore finding liver VMs in a patient with probable HHT can help further clarify the diagnosis of HHT. When screening is undertaken, it is advisable to screen with the least invasive test, such as Doppler US. Where expertise in Doppler US for liver VMs is lacking, a diagnosis of liver VMs can be made with triphasic CT.

The expert panel recommends that liver biopsy be avoided in any patient with proven or suspected HHT.

Clinical considerations: The rationale for recommending against liver biopsy for diagnosis of liver VMs is that the diagnosis is established with imaging studies, whereas biopsy exposes the patient to an unnecessary risk of haemorrhage.

Level of evidence: III
Strength of recommendation: strong
Agreement: 83%

Level of evidence: III
Strength of recommendation: strong
Agreement: 78%

Level of evidence: III
Strength of recommendation: strong
Agreement: 97%

Continued

Continued

The expert panel recommends that hepatic artery embolisation be avoided in patients with liver VMs as it is only a temporising procedure associated with significant morbidity and mortality

Clinical considerations: Given the elevated risk of post-embolisation necrosis and death, this procedure should not be considered as a first-line therapeutic option. It may be reasonable for the clinician to consider hepatic artery embolisation in certain patients, such as a patient with heart failure who has failed to respond to optimal medical therapy and who does not have biliary ischaemia or portovenous shunting and who is not a transplant candidate. The risks and benefits of embolisation and transplant should be considered on an individualised basis, based on type of shunting, clinical syndrome, patient characteristics and patient preference.

The expert panel recommends that referral for liver transplantation be considered in patients with liver VMs that develop:

- ▶ Ischaemic biliary necrosis
- ▶ Intractable heart failure
- ▶ Intractable portal hypertension

Clinical considerations: Since liver transplantation for liver VMs has a good survival rate, it is a reasonable option for patients with severe complications of liver VMs refractory to medical therapy. Patients who develop biliary necrosis have the highest mortality, particularly those who develop it in the setting of heart failure, and therefore should be prioritised for liver transplant, analogous to post-transplant patients who develop bile duct necrosis.

Level of evidence: III
Strength of recommendation: strong
Agreement: 94%

Level of evidence: III
Strength of recommendation: strong
Agreement: 94%

Author affiliations

¹Division of Respiriology, Department of Medicine, St Michael's Hospital, University of Toronto, Toronto, Ontario, Canada

²Li Ka Shing Knowledge Institute, St Michael's Hospital, University of Toronto, Toronto, Ontario, Canada

³Departments of Medicine, Health Policy, Management and Evaluation, University of Toronto, Toronto, Ontario, Canada

⁴Section of Digestive Diseases, Department of Internal Medicine, Yale University School of Medicine, New Haven, Connecticut, USA

⁵University of the Saarland, Medical Faculty, Homburg/Saar, Germany

⁶Department of Otorhinolaryngology, Holweide Hospital, Hospitals of the City of Cologne, Cologne, Germany

⁷Department of Radiology, University of Utah, Salt Lake City, Utah

⁸Section of Digestive Diseases, Yale University School of Medicine, New Haven, Connecticut, USA

⁹Department of Surgery, St Michael's Hospital, University of Toronto, Toronto, Ontario, Canada

¹⁰Dept of Otolaryngology/Head & Neck Surgery, University of Toronto, Toronto, Ontario, Canada

¹¹UO di Gastroenterologia ed Endoscopia Digestiva, Ospedale Maggiore, Crema, Italy

¹²Portland VA Medical Center, HHT Center of Excellence, Dotter Interventional Institute, Oregon Health & Science University, Portland, Oregon, USA

¹³University of Lyon, Hospices Civils de Lyon, National reference center for rare pulmonary diseases, Lyon, France

¹⁴Department of Genetics, University of Pennsylvania School of Medicine, Philadelphia, Pennsylvania, USA

¹⁵Medical College of Georgia, Augusta, Georgia, USA

¹⁶National Human Genome Research Institute, NIH, Bethesda, Maryland, USA

¹⁷Ontario Newborn Screening Program and Regional Genetics Program, Children's Hospital of Eastern Ontario, Ottawa, ON, Canada

¹⁸Massachusetts General Hospital Gastrointestinal Unit, Boston, Massachusetts, USA

¹⁹St Antonius Hospital, Nieuwegein, The Netherlands

²⁰Interventional Neuroradiology, Hopital de Bicetre, Paris, France

²¹Department of Otolaryngology-Head & Neck Surgery, Washington University School of Medicine, St Louis, Missouri, USA

²²Department of Radiology, Washington University School of Medicine, St Louis, Missouri, USA

²³National Reference Center for HHT Disease, Hotel Dieu Hospital, Hospices Civils de Lyon, Lyon, France

²⁴SE Scotland Genetic Service, Western General Hospital, Edinburgh, Scotland

²⁵University of Pennsylvania School of Medicine, Philadelphia, Pennsylvania, USA

²⁶Department of Surgery, St Vincent's Medical Center, Bridgeport, Connecticut, USA

²⁷Department of Internal Medicine and Public Health, University of Bari, Bari, Italy

²⁸Mayo Clinic Division of Pulmonary & Critical Care Medicine, Rochester, MN, USA

²⁹Division of Pulmonary & Critical Care Medicine, Johns Hopkins University, Baltimore, Maryland, USA

³⁰Division of Neurosurgery, Krembil Neuroscience Centre, University Health Network, Toronto, Ontario, Canada

³¹Yale Vascular Malformation Center, Yale University School of Medicine, New Haven, Connecticut, USA

³²Section of Cardiovascular Medicine, Yale University School of Medicine, New Haven, Connecticut, USA

³³Servicio de Medicina Interna, Unidad HHT, Hospital Sierrallana (Servicio Cántabro de Salud), Torrelavega (Cantabria), Spain

Acknowledgements Many thanks to the following people who contributed at different stages to the HHT Guidelines: Marianne Clancy MPA, Justine Cohen-Silver MD MSc, Sharon Straus MD MSc, Dave Davis MD, Mary Elyn Parker RN, Ana Carvalho, Joyce Fenuta RN BScN MHS, Beth Plahn RN MHA, David Stoner BS RPh,

Keith Williams, Cheryl Wilson MA MS, Jane E Tumpson MAT MBA, Samir Gupta MD MSc, Kevin Sanders MD MSc, Anna R. Gagliardi PhD, Andrew Worster MD and Denise Feig MD MSc.

Funding John Abele on behalf of the Argosy Foundation, HHT Foundation International Inc, Canadian Institutes of Health Research, St Michael's Hospital Department of Medicine. Financial support for MEF: Nelson Arthur Hyland Foundation, Li Ka Shing Knowledge Institute of St Michael's Hospital.

Competing interests VP received an honorarium for attending the HHT Guidelines Conference. DP received a grant (completed) from the Ethek F Donahue Foundation to study hormonal therapy in HHT.

Contributors All of the authors contributed to the guidelines development and the resulting manuscript.

Provenance and peer review Not commissioned; externally peer reviewed.

REFERENCES

- Kjeldsen AD, Vase P, Green A. Hereditary haemorrhagic telangiectasia: a population-based study of prevalence and mortality in Danish patients. *J Intern Med* 1999;**245**:31–9.
- Plauchu H, de Chadarevian JP, Bideau A, Robert JM. Age-related clinical profile of hereditary hemorrhagic telangiectasia in an epidemiologically recruited population. *Am J Med Genet* 1989;**32**:291–7.
- Collaboration TA. Appraisal of Guidelines for Research & Evaluation (AGREE) Instrument. <http://www.agreecollaboration.org/>, 2001.
- Buscarini E, Plauchu H, Garcia Tsao G, White RI Jr, Sabbà C, Miller F, Saurin JC, Pelage JP, Lesca G, Marion MJ, Perna A, Faughnan ME. Liver involvement in hereditary hemorrhagic telangiectasia: consensus recommendations. *Liver Int* 2006;**26**:1040–6.
- Goldbloom R, Battista RN. The periodic health examination: 1. Introduction. *CMAJ* 1986;**134**:721–3.
- Schunemann HJ, Jaeschke R, Cook DJ, Bria WF, El-Solh AA, Ernst A, Fahy BF, Gould MK, Horan KL, Krishnan JA, Manthous CA, Maurer JR, McNicholas WT, Oxman AD, Rubenfeld G, Turino GM, Guyatt G; ATS Documents Development and Implementation Committee. An official ATS statement: grading the quality of evidence and strength of recommendations in ATS guidelines and recommendations. *Am J Respir Crit Care Med* 2006;**174**:605–14.
- Atkins DL, Kenney MA. Automated external defibrillators: safety and efficacy in children and adolescents. *Pediatr Clin North Am* 2004;**51**:1443–62.
- Porteous ME, Burn J, Proctor SJ. Hereditary haemorrhagic telangiectasia: a clinical analysis. *J Med Genet* 1992;**29**:527–30.
- Berg J, Porteous M, Reinhardt D, Gallione C, Holloway S, Umasunthar T, Lux A, McKinnon W, Marchuk D, Guttmacher A. Hereditary haemorrhagic telangiectasia: a questionnaire based study to delineate the different phenotypes caused by endoglin and ALK1 mutations. *J Med Genet* 2003;**40**:585–90.
- Os AA, Friedman CM, White RI Jr. The natural history of epistaxis in hereditary hemorrhagic telangiectasia. *Laryngoscope* 1991;**101**:977–80.
- Shovlin CL, Guttmacher AE, Buscarini E, Faughnan ME, Hyland RH, Westermann CJ, Kjeldsen AD, Plauchu H. Diagnostic criteria for hereditary hemorrhagic telangiectasia (Rendu-Osler-Weber syndrome). *Am J Med Genet* 2000;**91**:66–7.
- Morgan T, McDonald J, Anderson C, Ismail M, Miller F, Mao R, Madan A, Barnes P, Huggins L, Manning M. Intracranial hemorrhage in infants and children with hereditary hemorrhagic telangiectasia (Osler-Weber-Rendu syndrome). *Pediatrics* 2002;**109**:E12.
- Cole SG, Begbie ME, Wallace GM, Shovlin CL. A new locus for hereditary haemorrhagic telangiectasia (HHT3) maps to chromosome 5. *J Med Genet* 2005;**42**:577–82.
- Bayrak-Toydemir P, McDonald J, Akarsu N, Toydemir RM, Calderon F, Tunçali T, Tang W, Miller F, Mao R. A fourth locus for hereditary hemorrhagic telangiectasia maps to chromosome 7. *Am J Med Genet A* 2006;**140**:2155–62.
- Gallione CJ, Repetto GM, Legius E, Rustgi AK, Schelley SL, Tejpar S, Mitchell G, Drouin E, Westermann CJ, Marchuk DA. A combined syndrome of juvenile polyposis and hereditary haemorrhagic telangiectasia associated with mutations in MADH4 (SMAD4). *Lancet* 2004;**363**:852–9.

16. **Bossler AD**, Richards J, George C, Godmilow L, Ganguly A. Novel mutations in ENG and ACVRL1 identified in a series of 200 individuals undergoing clinical genetic testing for hereditary hemorrhagic telangiectasia (HHT): correlation of genotype with phenotype. *Hum Mutat* 2006;**27**:667–75.
17. **Prigoda NL**, Savas S, Abdalla SA, Piovesan B, Rushlow D, Vandezande K, Zhang E, Ozcelik H, Gallie BL, Letarte M. Hereditary haemorrhagic telangiectasia: mutation detection, test sensitivity and novel mutations. *J Med Genet* 2006;**43**:722–8.
18. **Gallione CJ**, Richards JA, Letteboer TG, Rushlow D, Prigoda NL, Leedom TP, Ganguly A, Castells A, Ploos van Amstel JK, Westermann CJ, Pyeritz RE, Marchuk DA. SMAD4 mutations found in unselected HHT patients. *J Med Genet* 2006;**43**:793–7.
19. **Lesca G**, Burnichon N, Raux G, Tosi M, Pinson S, Marion MJ, Babin E, Gilbert-Dussardier B, Rivière S, Goizet C, Faivre L, Plauchu H, Frébourg T, Calender A, Giraud S; French Rendu-Osler Network. Distribution of ENG and ACVRL1 (ALK1) mutations in French HHT patients. *Hum Mutat* 2006;**27**:598.
20. **Kjeldsen AD**, Moller TR, Brusgaard K, Vase P, Andersen PE. Clinical symptoms according to genotype amongst patients with hereditary haemorrhagic telangiectasia. *J Intern Med* 2005;**258**:349–55.
21. **Letteboer TG**, Mager JJ, Snijder RJ, Koeleman BP, Lindhout D, Ploos van Amstel JK, Westermann CJ. Genotype-phenotype relationship in hereditary haemorrhagic telangiectasia. *J Med Genet* 2006;**43**:371–7.
22. **Bayrak-Toydemir P**, McDonald J, Markewitz B, Lewin S, Miller F, Chou LS, Gedge F, Tang W, Coon H, Mao R. Genotype-phenotype correlation in hereditary hemorrhagic telangiectasia: mutations and manifestations. *Am J Med Genet A* 2006;**140**:463–70.
23. **Dunlop MG**. Guidance on gastrointestinal surveillance for hereditary non-polyposis colorectal cancer, familial adenomatous polyposis, juvenile polyposis, and Peutz-Jeghers syndrome. *Gut* 2002;**51**(Suppl 5):V21–7.
24. **Shah RK**, Dhingra JK, Shapshay SM. Hereditary hemorrhagic telangiectasia: a review of 76 cases. *Laryngoscope* 2002;**112**:767–73.
25. **Pasculli G**, Resta F, Guastamacchia E, Di Gennaro L, Suppressa P, Sabba C. Health-related quality of life in a rare disease: hereditary hemorrhagic telangiectasia (HHT) or Rendu-Osler-Weber disease. *Qual Life Res* 2004;**13**:1715–23.
26. **McCaffrey TV**, Kern EB, Lake CF. Management of epistaxis in hereditary hemorrhagic telangiectasia. Review of 80 cases. *Arch Otolaryngol* 1977;**103**:627–30.
27. **McCabe WP**, Kelly AP Jr. Management of epistaxis in Osler-Weber-Rendu disease: recurrence of telangiectases within a nasal skin graft. *Plast Reconstr Surg* 1972;**50**:114–18.
28. **Bergler W**, Sadick H, Gotte K, Riedel F, Hormann K. Topical estrogens combined with argon plasma coagulation in the management of epistaxis in hereditary hemorrhagic telangiectasia. *Ann Otol Rhinol Laryngol* 2002;**111**:222–8.
29. **Klepfish A**, Berrebi A, Schattner A. Intranasal tranexamic acid treatment for severe epistaxis in hereditary hemorrhagic telangiectasia. *Arch Intern Med* 2001;**161**:767.
30. **Mahoney EJ**, Shapshay SM. Nd:YAG laser photocoagulation for epistaxis associated with hereditary hemorrhagic telangiectasia. *Laryngoscope* 2005;**115**:373–5.
31. **Werner JA**, Lippert BM, Geisthoff UW, Rudert H. [Nd:YAG laser therapy of recurrent epistaxis in hereditary hemorrhagic telangiectasia]. *Laryngorhinotologie* 1997;**76**:495–501.
32. **Karantzios I**, Tsimpiris N, Goulis DG, Van Hoeck H, Van Cauwenberge P, Danielides V. Management of epistaxis in hereditary hemorrhagic telangiectasia by Nd:YAG laser and quality of life assessment using the HR-QoL questionnaire. *Eur Arch Otorhinolaryngol* 2005;**262**:830–3.
33. **Bergler W**, Riedel F, Baker-Schreyer A, Juncker C, Hormann K. Argon plasma coagulation for the treatment of hereditary hemorrhagic telangiectasia. *Laryngoscope* 1999;**109**:15–20.
34. **Siegel MB**, Keane WM, Atkins JF Jr, Rosen MR. Control of epistaxis in patients with hereditary hemorrhagic telangiectasia. *Otolaryngol Head Neck Surg* 1991;**105**:675–9.
35. **Fiorella ML**, Ross D, Henderson KJ, White RI Jr. Outcome of septal dermoplasty in patients with hereditary hemorrhagic telangiectasia. *Laryngoscope* 2005;**115**:301–5.
36. **Lund VJ**, Howard DJ. Closure of the nasal cavities in the treatment of refractory hereditary haemorrhagic telangiectasia. *J Laryngol Otol* 1997;**111**:30–3.
37. **Hitchings AE**, Lennox PA, Lund VJ, Howard DJ. The effect of treatment for epistaxis secondary to hereditary hemorrhagic telangiectasia. *Am J Rhinol* 2005;**19**:75–8.
38. **Gluckman JL**, Portugal LG. Modified Young's procedure for refractory epistaxis due to hereditary hemorrhagic telangiectasia. *Laryngoscope* 1994;**104**:1174–7.
39. **Fischer M**, Dietrich U, Labisch C, Zanella FE, Jahnke K. [Critical evaluation of vascular embolization in patients with Rendu-Osler disease] (In German). *Laryngorhinotologie* 1997;**76**:490–4.
40. **Elden L**, Montanera W, Terbrugge K, Willinsky R, Lasjaunias P, Charles D. Angiographic embolization for the treatment of epistaxis: a review of 108 cases. *Otolaryngol Head Neck Surg* 1994;**111**:44–50.
41. **Borsik M**, Herbreteau D, Deffrennes D, Guichard JP, Aymard A, Merland JJ, Tran Ba Huy P. [Treatment of epistaxis in Rendu-Osler disease by intramuscular injection of ethibloc] (In French). *Ann Otolaryngol Chir Cervicofac* 1992;**109**:273–6.
42. **Jankowski R**, Beaudouin E, Kanny G, Wayoff M, Moneret-Vautrin DA. [Hypersensitivity accidents to thrombin following the use of biological glues] (In French). *Ann Otolaryngol Chir Cervicofac* 1992;**109**:95–9.
43. **Vase P**. Estrogen treatment of hereditary hemorrhagic telangiectasia. A double-blind controlled clinical trial. *Acta Med Scand* 1981;**209**:393–6.
44. **Geisthoff UW**. *Clinical Aspects of Hereditary Hemorrhagic Telangiectasia*. [Habilitation thesis]. Homburg/Saar: University of the Saarland, 2006.
45. **Andersen PJ**, Kjeldsen AD, Nepper-Rasmussen J. Selective embolization in the treatment of intractable epistaxis. *Acta Otolaryngol* 2005;**125**:293–7.
46. **Ojemann RG**, Ogilvy CS, Crowell RM, Heros RC. *Surgical Management of Neurovascular Disease*. 3rd edn. Baltimore: Williams and Wilkins, 1995.
47. **Krings T**, Ozanne A, Chng SM, Alvarez H, Rodesch G, Lasjaunias PL. Neurovascular phenotypes in hereditary haemorrhagic telangiectasia patients according to age. Review of 50 consecutive patients aged 1 day-60 years. *Neuroradiology* 2005;**47**:711–20.
48. **Maher CO**, Piepgras DG, Brown RD Jr, Friedman JA, Pollock BE. Cerebrovascular manifestations in 321 cases of hereditary hemorrhagic telangiectasia. *Stroke* 2001;**32**:877–82.
49. **Morgan MK**, Zurin AA, Harrington T, Little N. Changing role for preoperative embolisation in the management of arteriovenous malformations of the brain. *J Clin Neurosci* 2000;**7**:527–30.
50. **Fulbright RK**, Chaloupka JC, Putman CM, Sze GK, Merriam MM, Lee GK, Fayad PB, Awad IA, White RI Jr. MR of hereditary hemorrhagic telangiectasia: prevalence and spectrum of cerebrovascular malformations. *AJNR Am J Neuroradiol* 1998;**19**:477–84.
51. **Willemsse RB**, Mager JJ, Westermann CJ, Overtom TT, Mauser H, Wolbers JG. Bleeding risk of cerebrovascular malformations in hereditary hemorrhagic telangiectasia. *J Neurosurg* 2000;**92**:779–84.
52. **MacDonald RL**, Stoodley M, Weir B. Vascular malformations of the central nervous system. *Neurosurgery Quarterly* December 2001;**11**:231–47.
53. **Matsubara S**, Mandzia JL, ter Brugge K, Willinsky RA, Faughnan ME. Angiographic and clinical characteristics of patients with cerebral arteriovenous malformations associated with hereditary hemorrhagic telangiectasia. *AJNR Am J Neuroradiol* 2000;**21**:1016–20.
54. **Willinsky RA**, Lasjaunias P, Terbrugge K, Burrows P. Multiple cerebral arteriovenous malformations (AVMs). Review of our experience from 203 patients with cerebral vascular lesions. *Neuroradiology* 1990;**32**:207–10.
55. **Cullen S**, Alvarez H, Rodesch G, Lasjaunias P. Spinal arteriovenous shunts presenting before 2 years of age: analysis of 13 cases. *Childs Nerv Syst* 2006;**22**:1103–10.
56. **Berman MF**, Hartmann A, Mast H, Sciacca RR, Mohr JP, Pile-Spellman J, Young WL. Determinants of resource utilization in the treatment of brain arteriovenous malformations. *AJNR Am J Neuroradiol* 1999;**20**:2004–8.
57. **Mei-Zahav M**, Letarte M, Faughnan ME, Abdalla SA, Cymerman U, MacLusky IB. Symptomatic children with hereditary hemorrhagic telangiectasia: a pediatric center experience. *Arch Pediatr Adolesc Med* 2006;**160**:596–601.
58. **Mandzia JL**, terbrugge KG, Faughnan ME, Hyland RH. Spinal cord arteriovenous malformations in two patients with hereditary hemorrhagic telangiectasia. *Childs Nerv Syst* 1999;**15**:80–3.
59. **Leung KM**, Agid R, terbrugge K. Spontaneous regression of a cerebral arteriovenous malformation in a child with hereditary hemorrhagic telangiectasia. Case report. *J Neurosurg* 2006;**105**(5 Suppl):428–31.
60. **Cloft HJ**. Spontaneous regression of cerebral arteriovenous malformation in hereditary hemorrhagic telangiectasia. *AJNR Am J Neuroradiol* 2002;**23**:1049–50.
61. **Willinsky RA**, Taylor SM, Terbrugge K, Farb RI, Tomlinson G, Montanera W. Neurologic complications of cerebral angiography: prospective analysis of 2,899 procedures and review of the literature. *Radiology* 2003;**227**:522–8.
62. **Gauvrit JY**, Oppenheim C, Nataf F, Naggara O, Trystram D, Munier T, Frey D, Pruvo JP, Roux FX, Leclerc X, Meder JF. Three-dimensional dynamic magnetic resonance angiography for the evaluation of radiosurgically treated cerebral arteriovenous malformations. *Eur Radiol* 2006;**16**:583–91.
63. **Mori H**, Aoki S, Okubo T, Hayashi N, Masumoto T, Yoshikawa T, Tago M, Shin M, Kurita H, Abe O, Ohtomo K. Two-dimensional thick-slice MR digital subtraction angiography in the assessment of small to medium-size intracranial arteriovenous malformations. *Neuroradiology* 2003;**45**:27–33.
64. **Mukherji SK**, Quisling RG, Kubilis PS, Finn JP, Friedman WA. Intracranial arteriovenous malformations: quantitative analysis of magnitude contrast MR angiography versus gradient-echo MR imaging versus conventional angiography. *Radiology* 1995;**196**:187–93.
65. **Mast H**, Mohr JP, Thompson JL, Osipov A, Trocio SH, Mayer S, Young WL. Transcranial Doppler ultrasonography in cerebral arteriovenous malformations. Diagnostic sensitivity and association of flow velocity with spontaneous hemorrhage and focal neurological deficit. *Stroke* 1995;**26**:1024–7.
66. **Sommer C**, Mullges W, Ringelstein EB. Noninvasive assessment of intracranial fistulas and other small arteriovenous malformations. *Neurosurgery* 1992;**30**:522–8.
67. **Lundby B**, Gordon P, Hugo F. MRI in children given gadodiamide injection: safety and efficacy in CNS and body indications. *Eur J Radiol* 1996;**23**:190–6.
68. **Haw CS**, terbrugge K, Willinsky R, Tomlinson G. Complications of embolization of arteriovenous malformations of the brain. *J Neurosurg* 2006;**104**:226–32.
69. **Lawton MT**, Du R, Tran MN, Achrol AS, McCulloch CE, Johnston SC, Quinnee NJ, Young WL. Effect of presenting hemorrhage on outcome after microsurgical resection of brain arteriovenous malformations. *Neurosurgery* 2005;**56**:485–93; discussion 485–93.
70. **Lunsford LD**, Kondziolka D, Flickinger JC, Bissonette DJ, Jungreis CA, Maitz AH, Horton JA, Coffey RJ. Stereotactic radiosurgery for arteriovenous malformations of the brain. *J Neurosurg* 1991;**75**:512–24.
71. **Meisel HJ**, Mansmann U, Alvarez H, Rodesch G, Brock M, Lasjaunias P. Cerebral arteriovenous malformations and associated aneurysms: analysis of 305 cases from a series of 662 patients. *Neurosurgery* 2000;**46**:793–800; discussion 800–2.
72. **Pollock BE**, Flickinger JC, Lunsford LD, Bissonette DJ, Kondziolka D. Hemorrhage risk after stereotactic radiosurgery of cerebral arteriovenous malformations. *Neurosurgery* 1996;**38**:652–9; discussion 659–61.

73. **Suzuki J**, Onuma T, Kayama T. Surgical treatment of intracranial arteriovenous malformation. *Neural Res* 1982;**4**:191–207.
74. **Schwartz M**, Sixel K, Young C, Kemeny A, Forster D, Walton L, Franssen E. Prediction of obliteration of arteriovenous malformations after radiosurgery: the obliteration prediction index. *Can J Neural Sci* 1997;**24**:106–9.
75. **Taylor CL**, Dutton K, Rappard G, Pridge GL, Replogle R, Purdy PD, White J, Giller C, Kopitnik TA Jr, Samson DS. Complications of preoperative embolization of cerebral arteriovenous malformations. *J Neurosurg* 2004;**100**:810–12.
76. **Yoshimoto T**, Kayama T, Suzuki J. Treatment of cerebral arteriovenous malformation. *Neurosurg Rev* 1986;**9**:279–85.
77. **Zhao J**, Wang S, Li J, Qi W, Sui D, Zhao Y. Clinical characteristics and surgical results of patients with cerebral arteriovenous malformations. *Surg Neurol* 2005;**63**:156–61; discussion 161.
78. **Spetzler RF**, Martin NA, Carter LP, Flom RA, Raudzens PA, Wilkinson E. Surgical management of large AVM's by staged embolization and operative excision. *J Neurosurg* 1987;**67**:17–28.
79. **Weon YC**, Yoshida Y, Sachet M, Mahadevan J, Alvarez H, Rodesch G, Lasjaunias P. Supratentorial cerebral arteriovenous fistulas (AVFs) in children: review of 41 cases with 63 non choroidal single-hole AVFs. *Acta Neurochir (Wien)* 2005;**147**:17–31; discussion 31.
80. **Yoshida Y**, Weon YC, Sachet M, Mahadevan J, Alvarez H, Rodesch G, Lasjaunias P. Posterior cranial fossa single-hole arteriovenous fistulae in children: 14 consecutive cases. *Neuroradiology* 2004;**46**:474–81.
81. **Gossage JR**, Kanj G. Pulmonary arteriovenous malformations. A state of the art review. *Am J Respir Crit Care Med* 1998;**158**:643–61.
82. **Cottin V**, Plauchu H, Bayle JY, Barthelet M, Revel D, Cordier JF. Pulmonary arteriovenous malformations in patients with hereditary hemorrhagic telangiectasia. *Am J Respir Crit Care Med* 2004;**169**:994–1000.
83. **Mager JJ**, Overtoom TT, Blauw H, Lammers JW, Westermann CJ. Embolotherapy of pulmonary arteriovenous malformations: long-term results in 112 patients. *J Vasc Interv Radiol* 2004;**15**:451–6.
84. **Moussoutas M**, Fayad P, Rosenblatt M, Hashimoto M, Pollak J, Henderson K, Ma TY, White RI. Pulmonary arteriovenous malformations: cerebral ischemia and neurologic manifestations. *Neurology* 2000;**55**:959–64.
85. **Pollak JS**, Saluja S, Thabet A, Henderson KJ, Denbow N, White RI Jr. Clinical and anatomic outcomes after embolotherapy of pulmonary arteriovenous malformations. *J Vasc Interv Radiol* 2006;**17**:35–44; quiz 45.
86. **Swanson KL**, Prakash UB, Stanson AW. Pulmonary arteriovenous fistulas: Mayo Clinic experience, 1982–1997. *Mayo Clin Proc* 1999;**74**:671–80.
87. **Faughnan ME**, Thabet A, Mei-Zahav M, Colombo M, Maclusky I, Hyland RH, Pugash RA, Chait P, Henderson KJ, White RI Jr. Pulmonary arteriovenous malformations in children: outcomes of transcatheter embolotherapy. *J Pediatr* 2004;**145**:826–31.
88. **Shovlin CL**, Winstock AR, Peters AM, Jackson JE, Hughes JM. Medical complications of pregnancy in hereditary haemorrhagic telangiectasia. *QJM* 1995;**88**:879–87.
89. **Ference BA**, Shannon TM, White RI Jr, Zawin M, Burdge CM. Life-threatening pulmonary hemorrhage with pulmonary arteriovenous malformations and hereditary hemorrhagic telangiectasia. *Chest* 1994;**106**:1387–90.
90. **Nanthakumar K**, Graham AT, Robinson TI, Grande P, Pugash RA, Clarke JA, Hutchison SJ, Mandzia JL, Hyland RH, Faughnan ME. Contrast echocardiography for detection of pulmonary arteriovenous malformations. *Am Heart J* 2001;**141**:243–6.
91. **Barzilai B**, Waggoner AD, Spessert C, Picus D, Goodenberger D. Two-dimensional contrast echocardiography in the detection and follow-up of congenital pulmonary arteriovenous malformations. *Am J Cardiol* 1991;**68**:1507–10.
92. **White RI Jr**, Lynch-Nyhan A, Terry P, Buescher PC, Farmlett EJ, Charnas L, Shuman K, Kim W, Kinnison M, Mitchell SE. Pulmonary arteriovenous malformations: techniques and long-term outcome of embolotherapy. *Radiology* 1988;**169**:663–9.
93. **Dutton JA**, Jackson JE, Hughes JM, Whyte MK, Peters AM, Ussov W, Allison DJ. Pulmonary arteriovenous malformations: results of treatment with coil embolization in 53 patients. *AJR Am J Roentgenol* 1995;**165**:1119–25.
94. **Chilvers ER**, Whyte MK, Jackson JE, Allison DJ, Hughes JM. Effect of percutaneous transcatheter embolization on pulmonary function, right-to-left shunt, and arterial oxygenation in patients with pulmonary arteriovenous malformations. *Am Rev Respir Dis* 1990;**142**:420–5.
95. **Gupta P**, Mordin C, Curtis J, Hughes JM, Shovlin CL, Jackson JE. Pulmonary arteriovenous malformations: effect of embolization on right-to-left shunt, hypoxemia, and exercise tolerance in 66 patients. *AJR Am J Roentgenol* 2002;**179**:347–55.
96. **Prasad V**, Chan RP, Faughnan ME. Embolotherapy of pulmonary arteriovenous malformations: efficacy of platinum versus stainless steel coils. *J Vasc Interv Radiol* 2004;**15**:153–60.
97. **Lee DW**, White RI Jr, Egglin TK, Pollak JS, Fayad PB, Wirth JA, Rosenblatt MM, Dickey KW, Burdge CM. Embolotherapy of large pulmonary arteriovenous malformations: long-term results. *Ann Thorac Surg* 1997;**64**:930–9; discussion 939–40.
98. **Gershon AS**, Faughnan ME, Chon KS, Pugash RA, Clark JA, Bohan MJ, Henderson KJ, Hyland RH, White RI Jr. Transcatheter embolotherapy of maternal pulmonary arteriovenous malformations during pregnancy. *Chest* 2001;**119**:470–7.
99. **Lee WL**, Graham AF, Pugash RA, Hutchison SJ, Grande P, Hyland RH, Faughnan ME. Contrast echocardiography remains positive after treatment of pulmonary arteriovenous malformations. *Chest* 2003;**123**:351–8.
100. **Ingresso M**, Sabba C, Pisani A, Principi M, Gallitelli M, Cirulli A, Francavilla A. Evidence of small-bowel involvement in hereditary hemorrhagic telangiectasia: a capsule-endoscopic study. *Endoscopy* 2004;**36**:1074–9.
101. **Kjeldsen AD**, Vase P, Green A. [Hereditary hemorrhagic telangiectasia. A population-based study on prevalence and mortality among Danish HHT patients] (In Danish). *Ugeskr Laeger* 2000;**162**:3597–601.
102. **Vase P**, Grove O. Gastrointestinal lesions in hereditary hemorrhagic telangiectasia. *Gastroenterology* 1986;**91**:1079–83.
103. **Longacre AV**, Gross CP, Gallitelli M, Henderson KJ, White RI Jr, Proctor DD. Diagnosis and management of gastrointestinal bleeding in patients with hereditary hemorrhagic telangiectasia. *Am J Gastroenterol* 2003;**98**:59–65.
104. **Proctor DD**, Henderson KJ, Dziura JD, Longacre AV, White RI Jr. Endoscopic evaluation of the gastrointestinal tract in symptomatic patients with hereditary hemorrhagic telangiectasia. *J Clin Gastroenterol* 2005;**39**:115–19.
105. **Proctor DD**, Price J, Henderson KJ, White RI. Does the number and/or distribution of arteriovenous malformations change with age in patients with hereditary hemorrhagic telangiectasia. *Fourth International HHT Scientific Conference Denmark*, June 2001.
106. **van Cutsem E**, Rutgeerts P, Vantrappen G. Treatment of bleeding gastrointestinal vascular malformations with oestrogen-progesterone. *Lancet* 1990;**335**:953–5.
107. **Haq AU**, Glass J, Netchvolodoff CV, Bowen LM. Hereditary hemorrhagic telangiectasia and danazol. *Ann Intern Med* 1988;**109**:171.
108. **Korzenik JR**, Topazian MD, White R. Treatment of bleeding in hereditary hemorrhagic telangiectasia with aminocaproic acid. *N Engl J Med* 1994;**331**:1236.
109. **Bown SG**, Swain CP, Storey DW, Collins C, Matthewson K, Salmon PR, Clark CG. Endoscopic laser treatment of vascular anomalies of the upper gastrointestinal tract. *Gut* 1985;**26**:1338–48.
110. **Sargeant IR**, Loizou LA, Rampton D, Tulloch M, Bown SG. Laser ablation of upper gastrointestinal vascular ectasias: long term results. *Gut* 1993;**34**:470–5.
111. **Gostout CJ**, Bowyer BA, Ahlquist DA, Viggiano TR, Balm RK. Mucosal vascular malformations of the gastrointestinal tract: clinical observations and results of endoscopic neodymium: yttrium-aluminum-garnet laser therapy. *Mayo Clin Proc* 1988;**63**:993–1003.
112. **Memeo M**, Stabile lanora AA, Scardapane A, Suppressa P, Cirulli A, Sabbà C, Rotondo A, Angelelli G. Hereditary haemorrhagic telangiectasia: study of hepatic vascular alterations with multi-detector row helical CT and reconstruction programs. *Radiol Med* 2005;**109**:125–38.
113. **Ravard G**, Soyer P, Boudiaf M, Terem C, Abitbol M, Yeh JF, Brouard R, Hamzi L, Rymer R. Hepatic involvement in hereditary hemorrhagic telangiectasia: helical computed tomography features in 24 consecutive patients. *J Comput Assist Tomogr* 2004;**28**:488–95.
114. **Buscarini E**, Danesino C, Olivieri C, Lupinacci G, De Grazia F, Reduzzi L, Blotta P, Gazzaniga P, Pagella F, Grosso M, Pongiglione G, Buscarini L, Plauchu H, Zambelli A. Doppler ultrasonographic grading of hepatic vascular malformations in hereditary hemorrhagic telangiectasia—results of extensive screening. *Ultraschall Med* 2004;**25**:348–55.
115. **Buscarini E**, Buscarini L, Danesino C, Piantanida M, Civardi G, Quaretti P, Rossi S, Di Stasi M, Silva M. Hepatic vascular malformations in hereditary hemorrhagic telangiectasia: Doppler sonographic screening in a large family. *J Hepatol* 1997;**26**:111–18.
116. **Ocran K**, Rickes S, Heukamp I, Wermke W. Sonographic findings in hepatic involvement of hereditary haemorrhagic telangiectasia. *Ultraschall Med* 2004;**25**:191–4.
117. **lanora AA**, Memeo M, Sabba C, Cirulli A, Rotondo A, Angelelli G. Hereditary hemorrhagic telangiectasia: multi-detector row helical CT assessment of hepatic involvement. *Radiology* 2004;**230**:250–9.
118. **Garcia-Tsao G**, Korzenik JR, Young L, Piantanida M, Civardi G, Quaretti P, Rossi S, Di Stasi M, Silva M. Liver disease in patients with hereditary hemorrhagic telangiectasia. *N Engl J Med* 2000;**343**:931–6.
119. **Hashimoto M**, Tate E, Nishii T, Watarai J, Shioya T, White RI. Angiography of hepatic vascular malformations associated with hereditary hemorrhagic telangiectasia. *Cardiovasc Intervent Radiol* 2003;**26**:177–80.
120. **Bernard G**, Mion F, Henry L, Plauchu H, Paliard P. Hepatic involvement in hereditary hemorrhagic telangiectasia: clinical, radiological, and hemodynamic studies of 11 cases. *Gastroenterology* 1993;**105**:482–7.
121. **Matsumoto S**, Mori H, Yamada Y, Hayashida T, Hori Y, Kiyosue H. Intrahepatic porto-hepatic venous shunts in Rendu-Osler-Weber disease: imaging demonstration. *Eur Radiol* 2004;**14**:592–6.
122. **Naganuma H**, Ishida H, Niizawa M, Igarashi K, Shioya T, Masamune O. Hepatic involvement in Osler-Weber-Rendu disease: findings on pulsed and color Doppler sonography. *AJR Am J Roentgenol* 1995;**165**:1421–5.
123. **Caselitz M**, Bahr MJ, Bleck JS, Chavan A, Manns MP, Wagner S, Gebel M. Sonographic criteria for the diagnosis of hepatic involvement in hereditary hemorrhagic telangiectasia (HHT). *Hepatology* 2003;**37**:1139–46.
124. **Buscarini E**, Danesino C, Plauchu H, de Fazio C, Olivieri C, Brambilla G, Menozzi F, Reduzzi L, Blotta P, Gazzaniga P, Pagella F, Grosso M, Pongiglione G, Cappiello J, Zambelli A. High prevalence of hepatic focal nodular hyperplasia in subjects with hereditary hemorrhagic telangiectasia. *Ultrasound Med Biol* 2004;**30**:1089–97.
125. **Chavan A**, Caselitz M, Gratz KF, Lotz J, Kirchhoff T, Piso P, Wagner S, Manns M, Galanski M. Hepatic artery embolization for treatment of patients with hereditary hemorrhagic telangiectasia and symptomatic hepatic vascular malformations. *Eur Radiol* 2004;**14**:2079–85.
126. **Azoulay D**, Precetti S, Emile JF, Ichai P, Gillon MC, Duclos-Vallée JC, Visda S, Adam R, Castaing D, Samuel D, Bismuth H. [Liver transplantation for intrahepatic Rendu-Osler-Weber's disease: the Paul Brousse hospital experience] (In French). *Gastroenterol Clin Biol* 2002;**26**:828–34.
127. **Lerut J**, Orlando G, Adam R, Sabbà C, Pfitzmann R, Klempnauer J, Belghiti J, Pirenne J, Thevenot T, Hillert C, Brown CM, Gonze D, Karam V, Boillot O; European Liver Transplant Association. Liver transplantation for hereditary hemorrhagic telangiectasia: Report of the European liver transplant registry. *Ann Surg* 2006;**244**:854–62; discussion 862–4.