

Recessively Inherited Myotonia Congenita

PETER S. HARPER and DOUGLAS M. JOHNSTON

Departments of Medicine and Neurology, The Johns Hopkins School of Medicine, Baltimore, Maryland, USA

The mode of inheritance of myotonia congenita has been considered to be clearly autosomal dominant since the early description by Thomsen (1876) of the disorder occurring in his own family and now bearing his name. A similar dominant form of inheritance has been shown for the other inherited myotonic disorders, including dystrophia myotonica and paramyotonia. However, a recent study of myotonia congenita in Germany by Becker (1961, 1963, and 1966) has suggested that a number of families considered to have the classical myotonia congenita of Thomsen have in fact a myotonic disorder with an autosomal recessive mode of inheritance and certain distinguishing clinical features. This distinction has not been fully recognized outside the German literature, and as far as we can ascertain, Becker's series is the only report of this new form of myotonia congenita. The family reported here is an example of myotonia congenita, closely resembling Thomsen's disease, with a clear autosomal recessive mode of inheritance.

Family Report

The pedigree is shown in Figure 1.

The Propositus (IV.1) was born in 1943 of a normal full-term pregnancy and delivery. Some clumsiness of gait was noted at the age of 3 to 4 years, but medical advice was not sought until the age of 6, when definite stiffness of the leg muscles was present. Muscle hypertrophy and myotonia were found on examination at this time and myotonia congenita was diagnosed. The myotonia gradually became more extensive, and was a considerable hindrance in sports. He was felt by his parents to be weaker than expected from his muscular build. At age 19 he was killed in an automobile accident; the muscles were not studied at necropsy.

IV.2, sister of the propositus, born in 1946 of a full-term normal pregnancy, was first examined at the age of 3 years when the diagnosis was made in the propositus. She was said to have had myotonia at this time, but was symptom-free. Stiffness of the legs was first noted at the age of 6 years and the severity gradually increased until about 12 years of age, from which time it remained un-

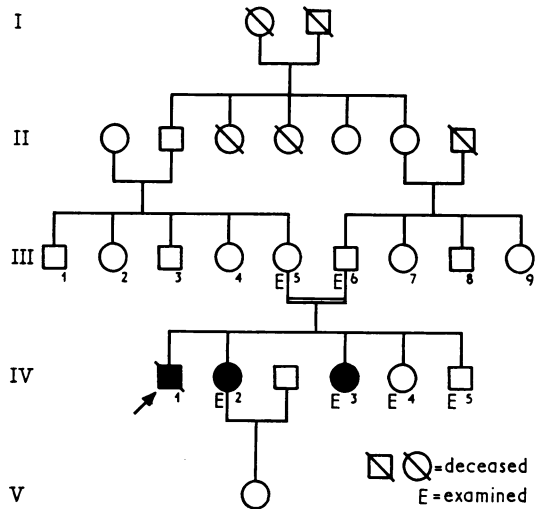


FIG. 1. Pedigree.

changed. She also complained of stiffness of the hands, jaw, and facial muscles, all symptoms being maximal when beginning to use the particular muscle group and diminishing after a few seconds. Symptoms were aggravated by cold; quinine had been tried with only slight improvement. Her general health was good and she specifically denied diabetes, visual symptoms, or menstrual disturbance. Her only child, a daughter born in 1965, was given for adoption in infancy, but was not known to be affected. Examination showed generalized muscular hypertrophy (Figs. 2a and 2b); active and percussion myotonia was present in all muscle groups, in particular the hands, jaw, and lower limbs. The gait was stiff for the first few steps, and there was an exaggerated lumbar lordosis. Slight but definite weakness was present in the sternomastoids, biceps, wrist flexors, small hand muscles, and iliopsoas. Examination was otherwise normal, with no signs to suggest myotonic dystrophy such as hair loss, high-arched palate, or cataract. Slit-lamp examination of the lenses was normal. Electromyogram showed profuse myotonic discharges which obscured individual action potentials.

IV.3, sister of the above, was born in 1950. She was 2 weeks' postmature, but was healthy in infancy, with

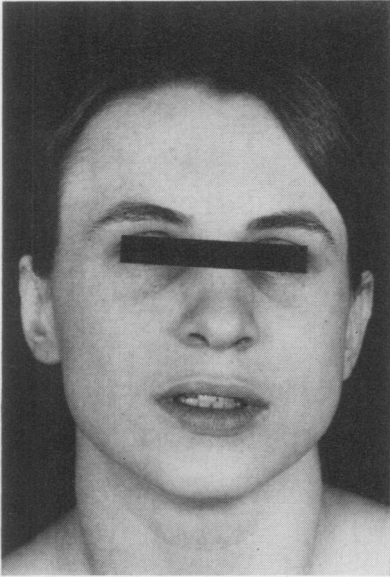


FIG. 2a.

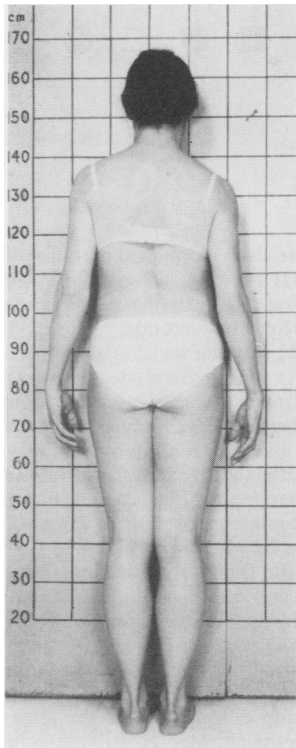


FIG. 2b.

FIG. 2. Patient IV.2 to show: (a) hypertrophy of the masseter and sternomastoid muscles, (b) hypertrophy of the calf muscles.

normal developmental milestones. At age 3 years her parents were suspicious that she might be affected, but no significant symptoms developed until between 6 and 7 years old, when stiffness of the legs appeared, becoming generalized to involve tongue, jaw, face, and hands, and increasing slightly up to the present time. She would trip frequently, and on falling would 'freeze' in a rigid posture.

Examination showed a robustly built and overweight girl with generalized muscular hypertrophy. Myotonia on beginning to walk was pronounced, as was widespread active and percussion myotonia of most muscle groups, though not the orbicularis oculi. There was slight bilateral weakness of iliopsoas, deltoids, biceps, triceps, wrist extensors, and wrist flexors. There was an exaggerated lumbar lordosis. Examination was otherwise normal, and slit-lamp examination of the lenses showed no crystalline opacities. EMG showed profuse myotonic discharges; no myopathic potentials were seen.

Other Family Members. Examination of the two youngest sibs and the parents was entirely normal, with complete absence of myotonia and of weakness. Electromyography and slit-lamp examination were likewise normal in all of them. Serum creatinine phosphokinase was normal in all family members, affected and unaffected, and urinary screening tests for abnormal metabolites, including amino acids and mucopolysaccharides, kindly performed by Dr George Thomas, were negative.

The parents of the propositus and his sibs were first cousins. Four sibs of the father were all without muscle symptoms and in good health, as were all the children of these sibs. The maternal grandparents were alive and well at over 80 years of age. The paternal grandfather died aged 50 of heart disease, but neither he nor his widow had muscle symptoms. Of the common ancestral couple (I.1 and I.2) the husband was of Welsh, the wife of English, descent.

Discussion

The pattern of inheritance of myotonia in this family, with 3 affected children born to normal first-cousin parents, strongly suggests autosomal recessive inheritance, unless some rare event such as gonadal mosaicism has occurred. There is no evidence that this condition is myotonic dystrophy, in view of the widespread myotonia, muscle hypertrophy, lack of wasting, and absence of lens changes or other significant features of the latter disease. There are, however, certain differences from the generally recognized features of myotonia congenita, in particular the absence of symptoms in infancy and early childhood, the progression till at least puberty, and the presence of definite, though mild and apparently non-progressive, weakness.

These features are very similar to those described by Becker as characterizing recessively

inherited myotonia congenita. He also found myotonia to be more severe in this form, and noted both dystrophic potentials on electromyography and scattered dystrophic fibres on muscle biopsy of the forearm. Biopsy was refused by the present family, but no dystrophic potentials could be found on EMG.

Becker's series also suggested that, at least in West Germany, the recessive form appeared to be considerably commoner than the classical dominant form of Thomsen's disease. Of 125 kindreds with non-dystrophic myotonia, only 24 showed presence of the disease in more than one generation, while in 39 kindreds sibs but not parents were affected; 62 other cases were sporadic, a figure close to that expected on the basis of the last 2 groups being due to recessive inheritance. There was a 10-fold increase in first-cousin marriages. It is unlikely that West Germany is significantly different from other countries in this distribution, for Thomsen (1948) had previously collected the cases of myotonia congenita reported in the world literature, and found only 34 out of 157 kindreds with more than one generation affected. He considered the possibility of recessive inheritance, but rejected it because of the lack of convincingly documented families where the parents were both unaffected; he preferred to explain the data by a combination of incomplete penetrance with insufficient study of supposedly unaffected members.

If recessive inheritance is accepted as accounting for a substantial proportion of the families with myotonia congenita, this will have important practical significance in genetic counselling, especially for the sporadic cases previously considered to

be new dominant mutations. At present a 50% risk is usually quoted for the offspring of an affected individual; if recessive inheritance is operating, the risk would be negligible. Clearly there is a need to re-examine myotonia congenita in order to attempt to define more clearly these two forms with differing modes of inheritance.

Summary

A family with myotonia congenita is reported in which 3 out of 5 sibs were affected; the parents were normal clinically and electromyographically, but were first cousins, strongly suggesting autosomal recessive inheritance. It is likely that this condition represents a separate entity from the classical dominantly inherited myotonia congenita, with differences in clinical features as well as inheritance. The importance for genetic counselling of recognizing the existence of the two forms is emphasized.

This work was supported by Muscular Dystrophy Associations of America, from whom P.S.H. received a research fellowship.

REFERENCES

- Becker, P. E. (1961). Heterogeneity of myotonia. In *Excerpta Medica International Congress Series*, No. 32, pp. E79-80. Amsterdam.
- Becker, P. E. (1963). Zur Genetik der Myotonien. *Internist*, **4**, 384-392.
- Becker, P. E. (1966). Zur Genetik der Myotonien. In *Progressive Muskeldystrophie, Myotonie, Myasthenie*, pp. 247-255. Springer Verlag, Berlin.
- Thomsen, E. (1948). *Myotonia*. Universitetsforlaget, Aarhus.
- Thomsen, J. (1876). Tonische Krämpfe in willkürlich beweglichen Muskeln in Folge von ererbter psychischer Disposition (Ataxia muscularis?). *Archiv für Psychiatrie und Nervenkrankheiten, vereinigt mit Zeitschrift für die gesamte Neurologie und Psychiatrie*, **6**, 702-718.