



Editor's choice
Scan to access more
free content

Diagnostic criteria for constitutional mismatch repair deficiency syndrome: suggestions of the European consortium 'Care for CMMRD' (C4CMMRD)

Katharina Wimmer,¹ Christian P Kratz,² Hans F A Vasen,³ Olivier Caron,⁴ Chrystelle Colas,^{5,6,7} Natacha Entz-Werle,⁸ Anne-Marie Gerdes,⁹ Yael Goldberg,¹⁰ Denisa Ilencikova,¹¹ Martine Muleris,^{6,7} Alex Duval,^{6,7} Noémie Lavoine,¹² Clara Ruiz-Ponte,¹³ Irene Slavc,¹⁴ Brigit Burkhardt,¹⁵ Laurence Brugieres,¹² on behalf of the EU-Consortium Care for CMMRD (C4CMMRD)

► Additional material is published online only. To view please visit the journal online (<http://dx.doi.org/10.1136/jmedgenet-2014-102284>).

For numbered affiliations see end of article.

Correspondence to

Dr Katharina Wimmer, Medical University of Innsbruck, Division of Human Genetics, Peter-Mayr-Strasse 1, Innsbruck 6020, Austria; katharina.wimmer@i-med.ac.at

Received 12 January 2014

Revised 18 March 2014

Accepted 23 March 2014

Published Online First

15 April 2014

ABSTRACT

Constitutional mismatch repair deficiency (CMMRD) syndrome is a distinct childhood cancer predisposition syndrome that results from biallelic germline mutations in one of the four MMR genes, *MLH1*, *MSH2*, *MSH6* or *PMS2*. The tumour spectrum is very broad, including mainly haematological, brain and intestinal tract tumours. Patients show a variety of non-malignant features that are indicative of CMMRD. However, currently no criteria that should entail diagnostic evaluation of CMMRD exist. We present a three-point scoring system for the suspected diagnosis CMMRD in a paediatric/young adult cancer patient. Tumours highly specific for CMMRD syndrome are assigned three points, malignancies overrepresented in CMMRD two points and all other malignancies one point. According to their specificity for CMMRD and their frequency in the general population, additional features are weighted with 1–2 points. They include multiple hyperpigmented and hypopigmented skin areas, brain malformations, pilomatricomas, a second childhood malignancy, a Lynch syndrome (LS)-associated tumour in a relative and parental consanguinity. According to the scoring system, CMMRD should be suspected in any cancer patient who reaches a minimum of three points by adding the points of the malignancy and the additional features. The diagnostic steps to confirm or refute the suspected diagnosis are outlined. We expect that application of the suggested strategy for CMMRD diagnosis will increase the number of patients being identified at the time when they develop their first tumour. This will allow adjustment of the treatment modalities, offering surveillance strategies for second malignancies and appropriate counselling of the entire family.

INTRODUCTION

The contribution of defective mismatch repair (MMR) to the cancer development has been acknowledged now for over two decades (for review, see ref. ¹). Heterozygous (monoallelic) germline mutations in the MMR genes *MLH1*, *MSH2*, *MSH6* and *PMS2* cause the autosomal-dominant Lynch syndrome (LS),² which predisposes primarily to colorectal and endometrial cancers but also to cancers of other organs, including the small bowel, urinary tract, stomach, ovaries and brain.^{3 4} Usually, affected individuals develop cancer not before the fourth decade of life. In

LS-associated tumours, MMR deficiency and, consequently, loss of repair mechanisms that protect the genome from DNA damage result from the loss of the wild-type MMR allele through somatic point mutations or loss-of-heterozygosity.

In 1999, two reports described the phenotype of the offspring from consanguineous marriages within LS families who carried homozygous *MLH1* germline mutations.^{5 6} These individuals developed haematological malignancies (and one individual a medulloblastoma) in early childhood (age range 14 months to 6 years). Of note, they also displayed clinical features reminiscent of neurofibromatosis type 1 (NF1). Since then, more than a hundred paediatric and young adult cancer patients have been reported carrying biallelic (homozygous or compound heterozygous) germline mutations in one of the four MMR genes involved in LS. This recessively inherited condition is now recognised as a distinct childhood cancer predisposition syndrome (OMIM #276300). The syndrome is known by different names, among which we consider constitutional MMR deficiency (CMMRD) syndrome^{7 8} the most appropriate one since it refers to the underlying defect. Although molecularly not proven, it is retrospectively most likely that Jacques Turcot in 1959 described the first cases of CMMRD when he reported on two siblings with numerous colorectal adenomatous polyps, colorectal carcinoma and malignant brain tumours.⁹ However, during the following years, patients who should retrospectively be considered CMMRD patients and familial adenomatous polyposis (FAP) patients with brain tumours were lumped together under the term Turcot syndrome.¹⁰ Hence, CMMRD and Turcot syndrome essentially overlap.

Due to the constitutional defect in MMR capacity, individuals with biallelic MMR gene mutations have a high risk of developing a diverse spectrum of malignancies already in childhood and adolescence. The spectrum includes mainly (i) haematological malignancies, (ii) brain/central nervous system (CNS) tumours and (iii) colorectal and other cancers that are typically seen in LS patients at a later age. A variety of other malignancies were seen only in a few or individual CMMRD patients. Many of the CMMRD patients, but not all, showed features reminiscent of NF1, particularly multiple café au lait maculae (CALM).



CrossMark

To cite: Wimmer K, Kratz CP, Vasen HFA, et al. *J Med Genet* 2014;**51**: 355–365.

In addition or alternatively to NF1 features, other non-neoplastic features may be present that are indicative of CMMRD in a paediatric cancer patient. But so far no single clinical criteria diagnostic of CMMRD emerged.

Diagnosis of CMMRD in a paediatric or young adult cancer patient has important implications for the management not only of the patient but also of the entire family. However, diagnosis may often be delayed or even not stated despite the fact that CMMRD is now defined as a distinct cancer predisposition syndrome with more than 60 reports on CMMRD patients already published. The lack of awareness for this rare cancer predisposition syndrome among paediatric haematologists/oncologists may be at least partially due to diagnostic difficulties that result from the lack of clearly disease-specific clinical features in combination with the broad tumour spectrum of CMMRD. A newly established European consortium 'Care for CMMRD' (C4CMMRD) addressed this issue at a workshop held at Saint-Antoine Hospital in Paris on 9 June 2013. The outcome of the discussion held at the workshop and thereafter with additional experts in the field who were not attending the meeting is presented here. Based on the current knowledge on the tumour spectrum and the spectrum of non-neoplastic features, we propose a three-point scoring system for clinical criteria that should raise a high index of suspicion for CMMRD when present in a paediatric/young adult cancer patient and, therefore, should entail diagnostic evaluation. The diagnostic steps that should confirm or refute the suspected diagnosis are outlined.

THE CLINICAL PHENOTYPE OF CMMRD AS DEDUCED FROM THE KNOWN CASES

Collection of the data from the known CMMRD cases

In 2008, all 78 CMMRD patients known at that time were compiled in a table.⁸ Since then, all subsequently published patients with a molecularly confirmed diagnosis of CMMRD were added to this list. Retrospectively, two patients were excluded from the original list because they carried *MLH1* variants with arguable pathogenicity, that is, NM_000243.3:p.Ala441Thr¹¹ and p.Lys618Ala.¹² As of June 2013, the table lists 127 patients from 79 families published in 63 papers (see online supplementary Table S1) as well as 19 so far unpublished patients (12 families). Of these 146 patients, 58% (60% of the families) carried biallelic *PMS2* mutations while the remaining roughly 40% of patients/families are more or less equally distributed among *MSH6* and *MLH1/MSH2* biallelics (see table 1). This distribution is in contrast to LS patients of whom the large majority carry heterozygous *MLH1* or *MSH2* mutations and only a minority heterozygous *PMS2* mutations. In part, this difference may reflect the reduced penetrance of heterozygous *PMS2* mutations. Studies in unselected cohorts of colorectal cancer patient

show that the prevalence of *PMS2*-associated LS is higher than previously thought.^{13 14}

In the following, we will describe the clinical phenotype as it can be deduced from these 146 patients. Data of the so far unpublished patients are also included in the overall analysis presented here, but detailed information on these patients will be published elsewhere. Since nearly all of the patients are described as individual medical case reports, potential selection bias must be kept in mind. To assess the full cancer spectrum and true cancer risk associated with CMMRD natural history, further studies that screen for CMMRD in unselected patients' cohorts are needed. These studies will also uncover the full spectrum and the frequency of non-neoplastic CMMRD features.

Malignancies in CMMRD patients

In almost all (145/146) of the patients reported so far, malignancies or at least premalignancies, that is, mainly bowel adenomas, were reported. Three biallelic mutation carriers who were reported in the original papers to have no tumours^{15–17} developed malignancies under surveillance¹⁸ (Gerdes and Illencikova 2013, unreported data). Although these observations suggest an extraordinary high tumour risk in CMMRD patients, data from a larger number of presymptomatically tested patients followed over a longer period of time are needed to assess the penetrance of CMMRD with respect to cancer development. Premalignancies and benign neoplasms not taken into account, 139 patients developed a total of 223 malignancies. In this calculation, multiple synchronous colon carcinomas were counted as only one malignancy. Table 2 summarises the spectrum and age of diagnosis of these malignancies. Online supplementary table S2 renders more details by splitting the data according to the mutated MMR gene.

In more detail, 48 malignancies of the haematopoietic system were diagnosed in 45 patients. Three patients had two different metachronous malignancies of the haematopoietic system. Within this group, non-Hodgkin's lymphomas (NHL) were the most prevalent tumour entity. Of the 31 NHL, 20 were derived from the T-cell lineage and 4 from B-cell lineage while lineage determination was not available for the remaining. Among the nine acute lymphoblastic leukaemias, four were classified as T-cell acute lymphoblastic leukaemia (T-ALL) while the rest were unclassified ALL. Acute myeloid leukaemia (AML) (five patients) was less common. Classification was difficult in three cases with haematological malignancies reported as atypical chronic myeloid leukaemia, malignant lymphoma and acute leukaemia.

Taken together, a total of 81 brain/CNS tumours were identified in 78 CMMRD patients. Among this tumour entity, the largest group were the high-grade gliomas (58 tumours), including 34 glioblastomas (this also includes two gliomatoses cerebri), 8 anaplastic astrocytomas, 6 oligodendrogliomas and 2 gliosarcomas. Assuming that they were of or eventually developed into high grade, also four unspecified gliomas, three unspecified astrocytomas and one fibrillary astrocytoma WHO II were included in the group of high-grade gliomas. Less common were intracranial embryonal tumours. CNS primitive neuroectodermal tumours (CNS-PNET) developed in eight patients and medulloblastoma in seven patients. Further, there are individual cases with specific brain tumour entities that do not fall into the two main categories (see table 2 and see online supplementary Table S2) and five unspecified brain tumours reported.

Table 1 Summary of 146 CMMR-patients from 91 families

Gene	Number of patients (families)	Mean age at first malignancy (years)	Age range at first malignancy (years)	Per cent of patients with second metachronous malignancy
<i>MLH1/MSH2</i>	32 (19)	7.5	0.4–39	22
<i>MSH6</i>	29 (17)	8	2–31	34
<i>PMS2</i>	85 (55)	10	1–28	42

Table 2 Malignancies in 146 CMMRD patients

Malignancies	Number of tumours	Median age at diagnosis in years	Age range at diagnosis in years
Haematological malignancies			
Non-Hodgkin's lymphoma	31	5	0.4–17
Lymphoid leukaemia	9	6	2–21
Acute myeloid leukaemia	5	9.5	6–17
Malignant lymphoma	1	15	
Atypical chronic myeloid leukaemia	1	1	
Acute leukaemia	1	2	
Total	48	6	0.4–21
Malignant brain and central nervous system tumours			
High-grade gliomas	58	9.5	2–40
sPNET	8	8	4–17
Medulloblastoma	7	7	4–12
Infiltrating cerebral angiosarcoma	1	2	
Cerebral anaplastic ganglioma	1	9	
Papillary ganglioneural tumour	1	11	
Not specified brain tumour	5	8	4–24
Total	81	9	2–40
LS-associated carcinomas			
Colon/rectum*	59	16	8–48
Duodenum/jejunum/ileum	18	28	11–42
Endometrium	6	28	23–44
Bladder/ureter (papillary transitional cells)	2	20	19 & 21
Ureter/renal pelvis (unspecified)	2	19	15 & 22
Ovaries	1	17	
Total	88	17	8–48
Others			
Neuroblastoma	1	13	
Nephroblastoma (Wilms tumour)	1	4	
Ovarian neuroectodermal tumour	1	21	
Infantile myofibromatosis	1	1	
Rhabdomyosarcoma	1	4	
Basal cell carcinoma	1	n.r.	
Muco-epidermoid ca. of parotis	1	11	
Osteosarcoma	1	24	
Total	8		

*Multiple synchronous bowel carcinomas were counted as one malignancy.

CMMRD, constitutional mismatch repair deficiency; LS, Lynch syndrome; sPNET, supratentorial primitive neuroectodermal tumours.

A total of 88 LS-associated malignancies developed in 59 patients. The vast majority were colorectal cancers (CRC). Six patients developed metachronous CRC and at least 16 patients presented with synchronous CRC. Because the exact number of synchronous carcinomas was not always given, we counted multiple synchronous CRC as only one malignancy, but the metachronous carcinomas each individually. Calculating by this way, a total of 59 CRC were found in 53 patients (table 2 and online supplementary table S2). Other LS-associated tumours were less frequent. A total of 12 patients developed 18 independent metachronous cancers of the small bowel (duodenum, jejunum, ileum), 6 patients endometrium cancer, 4 cancer of the urethral tract and 1 an ovarian cancer.

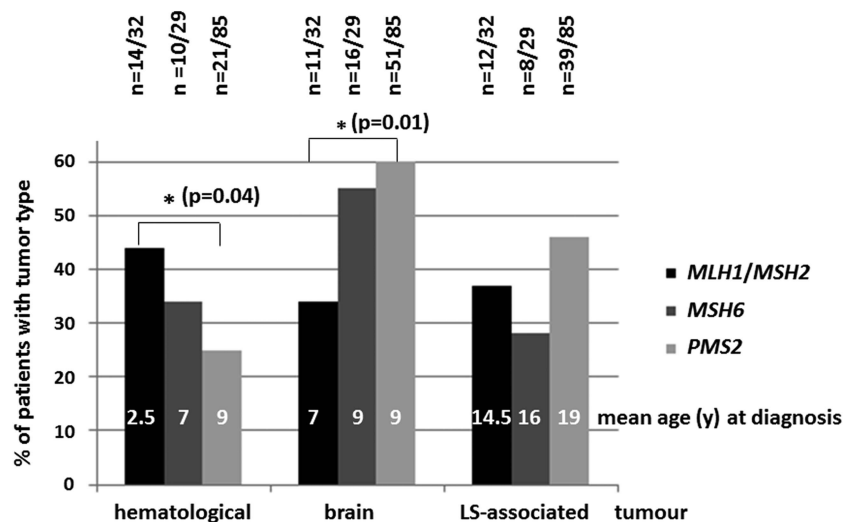
As can be deduced from table 2, the distribution of age at diagnosis was broad in each of the three main tumour groups. Nevertheless, there is clearly a trend of haematological tumours developing at earlier age (mean age at diagnosis 6 years) than brain/CNS tumours (mean age at diagnosis 9 years) and LS-associated tumours (mean age at diagnosis 17 years). The youngest patient with colon cancer was 8 years at diagnosis, while the youngest patient with a NHL was only a few months

old, and brain tumours were diagnosed in three patients already at the age of 2 years.

Figure 1 illustrates the differences in the prevalence of these three main tumour groups in CMMRD patients with biallelic *MLH1/MSH2* mutations compared with those with *MSH6* and *PMS2* biallelic mutations, respectively. Brain tumours were significantly more prevalent in *PMS2* mutation carriers than in *MLH1/MSH2* biallelics ($p=0.01$), and there was a trend of them being more prevalent also in *MSH6* than in *MLH1/MSH2* biallelics. Haematological malignancies are significantly more prevalent in *MLH1/MSH2* than *PMS2* biallelics ($p=0.04$). Also, haematological malignancies were more often the primary tumour in *MLH1/MSH2* mutation carriers comprising 38% of the cases (vs 25% and 16% of the *MSH6* and *PMS2* mutation carriers, respectively). In contrast, 50 and 60% of the *PMS2* and *MSH6* mutation carriers, respectively, but only 30% of the *MLH1/MSH2* biallelics developed a brain tumour as first malignancy. No substantial differences for the prevalence of LS-associated tumours were observed between the groups.

Looking at the mean age at diagnosis of the malignancy, *MLH1/MSH2* biallelics tend to develop each tumour entity at

Figure 1 Differences in the prevalence of the three main tumour types, that is, haematological, brain and LS associated, in CMMRD patients with the three different genotypes, that is, *MLH1* or *MSH2* (*MLH1/MSH2*), *MSH6* and *PMS2* biallelic mutations, are shown. The number of patients with the respective tumour type within the genotype group is given above the representative bar, and the mean age at tumour diagnosis is given in years (y) within each of the bars. Statistically significant differences in the prevalence of the tumour types between the genotypes are indicated. χ^2 testing was used for statistical analysis.



lower age than *MSH6* and *PMS2* biallelics (figure 1 and see online supplementary table S2). This trend is also reflected in an overall lower mean age at diagnosis of the first malignancy in CMMRD patients with *MLH1/MSH2* mutations than in *MSH6* and, particularly, *PMS2* biallelics (see table 1). However, the latter numbers are not very different (7.5 years in *MLH1/MSH2* biallelic vs 8 and 10 years in *MSH6* and *PMS2* biallelics, respectively). This may be partly due to the fact that the group of *MLH1/MSH2* biallelics contains two siblings compound heterozygous for the hypomorphic *MSH2* mutation c.1A>G and a deletion encompassing exons 1–6 of this gene (c.1-?_1076+? del). These patients developed multiple LS-associated tumours in their fourth and fifth decades of life.¹⁹ Excluding these two siblings, the differences between the genetic groups are more obvious (5 vs 8 and 10 years). The percentage of biallelic mutation carriers with more than one malignancy was lowest in *MLH1/MSH2* and highest in *PMS2* biallelics (see table 1). This may indicate that the chance to survive the first tumour and develop a second metachronous malignancy is better in *PMS2* biallelic mutation carriers than in *MLH1/MSH2* biallelics. This observation adds to the notion that patients with biallelic *MLH1/MSH2* mutations show overall a more severe phenotype than those with biallelic *MSH6* and *PMS2* mutations.

There were also a number of additional malignancies that do not fall into the three main tumour categories and that were diagnosed each in so far only one genetically proven CMMRD patient. These malignancies included embryonal tumours and sarcomas. Apart from the genetically proven CMMRD patient listed in table 2, rhabdomyosarcomas were also reported in two

patients with an inferred diagnosis of CMMRD.^{6 20} Rhabdomyosarcoma, the most common soft tissue sarcoma in children, is discussed to be associated with NF1.²¹ Given the phenotypic overlap of CMMRD with NF1, CMMRD patients with rhabdomyosarcoma and signs of NF1 may have been misdiagnosed in the past. Hence, there is evidence that the frequency of CMMRD among patients with rhabdomyosarcoma may be higher. Also, there is so far unreported evidence that osteosarcoma may be a tumour entity that is more frequent in CMMRD than previously thought (Brugières for the French CMMRD consortium unreported).

Premalignancies and non-malignant tumours in CMMRD patients

The spectrum of tumours found in CMMRD patients includes also premalignancies and non-malignant tumours (see table 3). A high percentage of the published CMMRD patients developed adenomas of the gastrointestinal tract, which are considered the premalignant lesions from which gastrointestinal cancers develop. Adenomas of the colon and rectum were reported in 52 (36%) of the patients, and many of them developed multiple synchronous adenomas ranging from a few to up to 100 polyps²² reminiscent of (attenuated) FAP.^{23 24} In eight patients, adenomas of the small bowel were reported. At least one patient developed gastric polyps.

Hepatic adenomas were found in three patients with a genetically confirmed diagnosis of CMMRD,²⁵ as well as in one of the siblings from the original Turcot family¹⁰ and in one so far unreported CMMRD patient. The latter two cases are not

Table 3 Premalignancies and non-malignant tumours in 146 CMMRD patients

Type of neoplasia	Number of patients	Median age at first diagnosis in years	Age range at first diagnosis in years
Adenomas/polyps of colon and rectum	52	14	6–46
Duodenal adenomas/polyps	8	14	10–32
Gastric polyps	1	n.r.	n.r.
Hepatic adenomas	3	9	–
Neurofibromas	7	n.r.	n.r.
Optic glioma	1	3	–
Pilomatricomas (epithelioma of Malherbe)	2	2 years 8 months	–
Polyps of vocal cord	1	in infancy	–

CMMRD, constitutional mismatch repair deficiency; n.r., not reported.

included in table 3 because the patient reported by Turcot was never molecularly confirmed and the unreported patient was found to be homozygous for a so far unknown *PMS2* missense variant and, hence, his molecular diagnosis could not be confirmed unambiguously.

Benign cutaneous or plexiform neurofibromas were reported in eight patients and one patient had an optic glioma.²⁶ The latter might be a sign of (mosaic) NF1 in this CMMRD patient who also had six CALMs and freckling and, therefore, met the diagnostic criteria of NF1. This WHO grade I tumour is not listed in table 1 as it is not considered a malignant brain tumour. But it is noteworthy that Ostergaard and colleagues²⁷ report a patient with a brain tumour of the left parieto-occipital area, which initially showed the histology of a pilocytic astrocytoma. This tumour recurred within 6 months, then characterised as anaplastic astrocytoma.

Pilomatricomas, also termed calcifying epithelioma of Malherbe, are benign tumours of the hair follicles. In two patients with genetically confirmed CMMRD syndrome, multiple pilomatricomas were reported. The authors proposed that the presence of multiple pilomatricomas that is seen very rarely in otherwise healthy individuals should raise a suspicion for an underlying MMR repair defect when observed in a paediatric cancer patient.²⁸ Of note, there may also be an association of multiple pilomatricomas with *MUTYH*-associated polyposis,²⁹ a polyposis syndrome that has certain phenotypical and pathomechanistic overlap with CMMRD since both recessively inherited tumour predisposition syndromes are caused by DNA repair defects leading to attenuated polyposis although usually in different age groups.

One patient had polyps of the vocal cord in infancy; the link of this latter sign with CMMRD is not proven yet.

Non-neoplastic features of CMMRD

The most prevalent non-neoplastic features seen in CMMRD patients are CALMs and other pigmentary alterations. More than 60% (91/146) of the CMMRD patients were reported to show at least one CALM or hyperpigmented skin area (table 4) and only four published^{19 30–32} and one so far unpublished patient have been explicitly reported to lack these pigmentary alterations. The vast majority of these patients had multiple (two or more) CALMs, but they did not always reach the critical number of ≥ 6 , which is needed to be a diagnostic criteria of

NF1. Several authors stress that the degree of pigmentation and the shape of these hyperpigmented skin macules often differed from the CALMs typically seen in NF1 patients. Nevertheless, several patients showed classical NF1-associated CALMs. Twenty-seven patients showed (often in addition to CALMs) other features diagnostic for NF1. These features included freckling in 14, neurofibromas in 8, Lisch nodules in 5 and tibia pseudarthrosis, sphenoid wing dysplasia and optic glioma each in 1 patient. Also, 3 of the 27 patients were reported to have a NF1 phenotype, but the signs were not specified.^{13 33} Because several patients showed a segmental/regional distribution of NF1 signs^{6 34} and a postzygotic *NF1* mutation was found in one patient,³⁵ it is thought that classical CALMs and other typical NF1 signs in CMMRD patients result from postzygotic *NF1* mutations present in a segmental or mosaic status. Another pigmentary abnormality reported in at least nine CMMRD patients are areas of skin hypopigmentation, also reported as 'ash leaf spots' or 'vitiligo' (table 4).

An analysis of three patients with biallelic *PMS2* and eight with biallelic *MSH6* mutations has shown that constitutional deficiency of these MMR genes leads to impaired immunoglobulin (Ig) class switch recombination characterised by a decrease or absence of IgG2, IgG4 and IgA concomitant (particularly in young patients) with increased IgM levels, that is, hyper-IgM syndrome.^{36 37} IgA deficiency indicative of this humoral defect was also observed in a patient with a homozygous *MSH2* mutation.³⁸ Hence, in total 12 CMMRD patients were reported to show defects in Ig class switch. In most of the other CMMRD patients, this parameter was not tested since an increased susceptibility to severe and persistent infection that would be indicative of an immune defect was noticed only in very few CMMRD patients.

Eight CMMRD patients had congenital malformations. Agenesis of the corpus callosum (ACC) is reported so far in four patients, and in three of these patients grey matter heterotopia was also detected.^{30 39} Baas and colleagues³⁰ render evidence that these features are seen more frequently in CMMRD than in the general population. Therefore, it was suggested that ACC with or without grey matter heterotopia is associated with CMMRD and should raise the suspicion of this disorder in a paediatric cancer patient. It was speculated that these isolated and largely asymptomatic brain malformations in CMMRD patients result from early embryonic somatic mutations in one or more of the genes implicated in the callosal development. Equally, it may be speculated that somatic mutations in developmental genes (presumed to occur more frequently in CMMRD) could be responsible also for other malformations that were observed in CMMRD patients. Non-therapy-induced brain cavernomas were seen in two published patients^{25 40} and one so far unreported patient. The combination of congenital asplenia, left isomerism and a ventricular septum defect was observed in one patient.²³ It will be worthwhile to systematically analyse whether these and other malformations are also found at a higher frequency in CMMRD patients than in the general population.

Furthermore, two patients developed lupus erythematosus^{31 41} and two haemangioma of the skin.^{30 42}

SUGGESTIONS OF THE EUROPEAN CONSORTIUM 'CARE FOR CMMRD'

Diagnostic criteria that should raise the suspicion of CMMRD syndrome in a cancer patient

An early and definite diagnosis of CMMRD in a paediatric and young adult cancer patient is desired for several reasons. (1)

Table 4 Non-neoplastic features in 146 CMMRD patients

Feature	Number of individuals
Café au lait spots or area of skin hyperpigmentation	91
Café au lait spots and other signs reminiscent of NF1	27
Area of skin hypopigmentation	9
Mild defects in immunoglobulin class switch recombination: IgG2↓ and/or IgG4↓ and/or IgA↓ and/or IgM↑	12
Agenesis of the corpus callosum with and without grey matter heterotopia	4
Cavernous brain haemangioma	3
Capillary haemangioma of skin	2
Combination of congenital malformations (asplenia, left isomerism, ventricle septum defect)	1
Lupus erythematosus	2

CMMRD, constitutional mismatch repair deficiency.

Although the true cancer risk of CMMRD is currently not known (and may be overestimated since we have to rely on a potentially biased cohort of patients), the available data from the published patients with this rare disorder suggest that it is extraordinarily high. CMMRD patients who survive their first malignancy or in whom a premalignancy has been removed have a high risk of developing a second often different (pre-) malignancy. To improve the prognosis, surveillance should be offered at least for bowel cancer and brain tumours as recently proposed by the European consortium.⁴³ (2) Early and definite diagnosis may also be a prerequisite in the future to adjust treatment to the underlying MMR defect and the high risk of a secondary malignancy. Currently, no information is available regarding the optimal treatment for CMMRD patients. But careful attention should be given to a possibly reduced efficacy and increased cytotoxicity of certain chemotherapeutic agents due to constitutionally impaired mutation repair.^{7 44} Since MMR-deficient cells are profoundly resistant to O⁶ methylators such as temozolomide,^{45 46} the risk of therapy failure may be increased in CMMRD patients treated with this drug. Furthermore, these drugs may increase the risk of second primary tumours by accelerating the rate of unrepaired mutations. (3) Siblings of a CMMRD patient have a 25% risk of having inherited the same genotype and, hence, equally a high risk for childhood cancer. (4) The parents of CMMRD patients and 50% of their siblings as well as other more distantly related family members are heterozygous for the MMR mutation(s) and, therefore, have an increased risk for LS-associated tumours in adulthood. A definite molecular diagnosis is needed to offer the families of CMMRD patients appropriate counselling and

discuss with them the options of predictive testing as well as prenatal/preimplantation diagnostics if this is desired.

It might be considered desirable to establish a diagnosis before the development of the first malignancy in a biallelic MMR gene mutation carrier. Currently, however, this seems to be only achievable for siblings of a tumour patient with a molecularly confirmed diagnosis. The non-neoplastic features of CMMRD may be too subtle and unspecific to raise the suspicion in a child without a malignancy if there is no family history of CMMRD or diagnosis of LS in the family. Therefore, it was decided at the first meeting of the C4CMMRD consortium that, at the time being, the group will only propose clinical criteria that should raise the suspicion of CMMRD when present in a cancer patient. Questions that were discussed among the group were

- Which tumour entities should raise a suspicion?
- What is the age limit for a patient with a specific tumour entity to be suspected?
- Which non-neoplastic feature should be considered a diagnostic criterion?

Ad A): The spectrum of malignancies in CMMRD is very broad (see table 2). Therefore, any malignancy in a paediatric (young adult) patient could be a CMMRD-associated one. Nevertheless, the index of suspicion should be higher in tumour entities that are overrepresented in CMMRD patients compared with their proportion in all tumours of the general population. Taking this into account, we developed a scoring system for the suspected diagnosis of CMMRD. Tumours assigned three points are highly specific for CMMRD syndrome. A diagnosis of CMMRD should be suspected in patients with these tumour entities no matter whether they show additional (non-neoplastic) features of CMMRD or not. Malignancies assigned two points are overrepresented in CMMRD but less specific. Additional features or tumours that add up to three points need to be present in patients with these malignancies to suspect CMMRD. All other malignancies are assigned one point, and additional tumours or features strongly pointing into the direction of CMMRD need to be present to raise a suspicion that should entail further diagnostic steps.

Colorectal or other cancers of the LS spectrum are extremely rare below the age of 25 years even in LS and FAP. Because they are highly suggestive for CMMRD, which phenotypically presents in several cases as a very early onset form of LS, three points are assigned to these tumours.

Multiple bowel adenomas are a frequent finding in CMMRD, which hence shows clinical overlap also with (attenuated) FAP. Herkert *et al*²³ proposed that in the absence of proven *APC* or *MUTYH* germline mutations, patients with childhood-onset adenomatous polyposis should be considered for MMR gene mutation testing, especially when they have features of NF1. In CMMRD, both the adenoma formation and the adenoma carcinoma transition may be accelerated due to the greatly enhanced mutation rate in neoplastic and non-neoplastic tissue. In agreement with this notion, most (35/52) of the CMMRD patients with adenomas showed high-grade dysplasia in at least one of them or had synchronous bowel cancer. Therefore, CMMRD syndrome should be considered as a differential diagnosis also in a patient under the age of 25 years (for considerations concerning the age limit of 25 years, see ad (B)) with (i) multiple adenomas if a heterozygous *APC* mutation or biallelic *MUTYH* mutations are absent (exclusion of *POLD1* and *POLE* hotspot mutations may also be considered⁴⁷) or (ii) in a patient with a single adenoma with high-grade dysplasia. Consequently, multiple bowel adenomas and absence of an *APC/MUTYH*

Table 5 Indication criteria for CMMRD testing in cancer patients

Indication for CMMRD testing in a cancer patient	≥3 points
Malignancies/premalignancies: one is mandatory; if more than one is present in the patient, add the points	
Carcinoma from the LS spectrum* at age <25 years	3 points
Multiple bowel adenomas at age <25 years and absence of <i>APC/MUTYH</i> mutation(s) or a single high-grade dysplasia adenoma at age <25 years	3 points
WHO grade III or IV glioma at age <25 years	2 points
NHL of T-cell lineage or sPNET at age <18 years	2 points
Any malignancy at age <18 years	1 point
Additional features: optional; if more than one of the following is present, add the points	
Clinical sign of NF1 and/or ≥2 hyperpigmented and/or hypopigmented skin alterations Ø>1 cm in the patient	2 points
Diagnosis of LS in a first-degree or second-degree relative	2 points
Carcinoma from LS spectrum* before the age of 60 in first-degree, second-degree, and third-degree relative	1 point
A sibling with carcinoma from the LS spectrum*, high-grade glioma, sPNET or NHL	2 points
A sibling with any type of childhood malignancy	1 point
Multiple pilomatricomas in the patient	2 points
One pilomatricoma in the patient	1 point
Agenesis of the corpus callosum or non-therapy-induced cavernoma in the patient	1 point
Consanguineous parents	1 point
Deficiency/reduced levels of IgG2/4 and/or IgA	1 point

*Colorectal, endometrial, small bowel, ureter, renal pelvis, biliary tract, stomach, bladder carcinoma.
CMMRD, constitutional mismatch repair deficiency; LS, Lynch syndrome; NHL, non-Hodgkin's lymphomas; sPNET, supratentorial primitive neuroectodermal tumours.

mutation and/or one adenoma with high-grade dysplasia under the age of 25 have a score of three points.

High-grade gliomas, including glioblastoma, gliosarcoma, anaplastic astrocytoma, oligodendroglioma and others, are rare tumours in childhood and adolescence. According to the data of the French Brain Tumour Data Bank⁴⁸ and the German childhood cancer register (<http://www.kinderkrebsregister.de>), they represent 15% of all brain/CNS tumours in childhood and adolescence. Hence, assuming that a quarter of all tumours in childhood are brain/CNS tumours, high-grade gliomas represent less than 5% of all tumours in childhood/adolescence. In contrast, 26% of all malignancies so far seen in CMMRD patients are high-grade gliomas. Equally, CNS-PNET constituting 3.5% of all so far reported malignancies in CMMRD (vs 0.5% of all childhood tumours in the general population) are overrepresented in CMMRD. Among the haematological tumours, NHL are overrepresented in CMMRD. NHL constitute ~5–7% of all childhood tumours but 14% of all CMMRD-associated malignancies. Of note, at least 65% (20/31) of the CMMRD-associated NHL were from the T-cell lineage and at least 42% (13/31) were T-cell lymphoblastic lymphomas. This is in contrast to the distribution in the general population where ~65% are from the B-cell lineage and more than 50% are mature B-NHL.⁴⁹ Hence, NHL of the T-cell lineage mainly account for the overrepresentation of NHL in CMMRD. Taken together, T-NHL, high-grade gliomas and CNS-PNET are considered malignancies typical for CMMRD and are assigned two points in the scoring system.

Ad B): The age at diagnosis of the first malignancy ranges from 0.4 to 39 years in CMMRD patients (table 1). However, the vast majority, that is, 120 of the 146 CMMRD patients, were younger than 18 years of age when their first tumour was diagnosed. Only 17 patients were between 18 and 25 years when they developed their first tumour, which was a CRC in 11 patients, a glioblastoma in 1 patient and an oligodendroglioma in 1 patient. The remaining four patients had colorectal adenomas when they were young adults. Only four patients were older than 25 years when they were diagnosed with their first tumour; in all four cases a CRC.^{13 19 41} These four patients carried at least one allele a likely hypomorphic *MSH2*, *MSH6* and *PMS2* mutation, respectively, and, therefore, may genetically as well as clinically represent an intermediate phenotype between CMMRD and LS. Based on the observations in the patients reported so far, we set the age limit at diagnosis of the first tumour at 25 years for patients with CRC, colorectal adenomas and malignant gliomas. For all other patients with malignancies, the age limit is <18 years (see table 5).

Ad C): Non-neoplastic features are weighted according to their specificity for CMMRD and their frequency in the general population with one point or two points.

Presence of (segmental) NF1 signs, primarily multiple (≥ 6) CALMs and freckling, is so far the most commonly reported non-neoplastic feature associated with CMMRD, and it has been stressed already in several reports that presence of one or more of these signs should raise the suspicion of CMMRD in any paediatric cancer patient with the exception of children/young adults with clearly NF1-associated malignancies, such as a peripheral nerve sheath tumour (MPNST) or a juvenile myelomonocytic leukaemia (JMML) or with a parent who is also diagnosed with NF1. Hence, this highly specific feature is weighted two points.

Although many CMMRD patients came to attention through the presence of NF1 signs, our analysis of the reported cases clearly indicates that limiting suspicion to patients showing

classical NF1 signs will miss a number of patients. In several CMMRD patients, the number of CALMs has been reported to be below six, which is the necessary number to be diagnostic for NF1. Furthermore, several CMMRD patients do not show classical NF1-associated CALMs but have different kinds of skin hyperpigmentation and hypopigmentation. As an isolated finding these alterations are frequent in the general population. A study assessing the frequency of CALMs among school children aged 4–11 years showed that ~20% (146/732) had one CALM. However, only 4.1% (30/732) and 1.2% (9/732) had two and three CALMs, respectively.⁵⁰ Merks and colleagues⁵¹ report a slightly lower frequency of solitary and multiple CALM in 13% and 3.3% of school children, respectively. Hence, the likelihood of having a childhood malignancy and two or more CALMs (hyperpigmented macules) by pure chance is very low. The same is likely the case for hypopigmented macules. Therefore, the presence of two or more skin areas of hyperpigmentation or hypopigmentation with a minimum diameter of 1 cm should be another feature that should raise the suspicion of CMMRD. This feature is also weighted two points.

Brain malformations such as agenesis of corpus callosum and non-therapy-induced cavernoma as well as pilomatricomas/epitheliomas of the Malherbe are rare in the general population. But they seem to have a higher incidence in CMMRD patients (see sections 'Premalignancies and non-malignant tumours in CMMRD patients' and 'Non-neoplastic features of CMMRD'). Therefore, these features should also raise the suspicion of CMMRD when present in a childhood cancer patient and are, thus, weighted depending on their frequency in the general population 1–2 points. The frequency of brain malformations in CMMRD patients still needs to be evaluated prospectively. As long as they have not been shown to be more frequent, we do not advocate performing cranial MRI unless required for other clinical reasons to test for these features only in order to confirm the diagnosis CMMRD in a cancer patient. The brain malformations add one point to the score of a cancer patient. *Multiple* pilomatricomas, which are extremely rare and always indicate an underlying genetic defect, add two points. A single pilomatricoma adds only one point.

Consanguinity of the parents and/or homozygosity for one (founder) mutation is observed in 46 of the 91 so far reported families with CMMRD patients. However, consanguineous marriages are common in several ethnic and religious groups of the European population. Therefore, we decided that consanguinity should add one point and raise the suspicion of CMMRD in a patient with a paediatric cancer that is overrepresented in CMMRD syndrome and in any other paediatric cancer patient who has one of the other features.

Due to the impaired class switch recombination, reduced IgG2/4 and/or IgA levels could be observed in several CMMRD patients. But this feature is neither very specific for CMMRD nor particularly rare in the general population. Hence, it is also assigned one point.

Other criteria for suspecting CMMRD in a child with a malignancy are (i) a sibling with a malignancy and (ii) the molecular diagnosis of LS or an LS-associated tumour before the age of 60 years in a first-degree, second-degree or third-degree relative of the patient. When assigning points to these criteria, it was taken into consideration that typical CMMRD tumours in a sibling should raise a higher index of suspicion (two points) than any other tumour in a sibling (one point). Equally, a definite diagnosis of LS in the family is assigned two points, whereas an LS-associated tumour before the age of 60 years in a first-degree, second-degree or third-degree relative

of the patient is scored only one point. A LS-associated tumour in a relative that has been shown to be microsatellite stable, and hence, is very likely a sporadic tumour should not be taken into account.

According to the three-point scoring system summarised in table 5, CMMRD syndrome should be suspected in an individual who reaches a score of minimum three points. The points should be counted by adding the points assigned to the malignancy/malignancies and those assigned to additional features. When using this system, it has to be kept in mind that several of these features listed in table 5 may be present also in a patient with a different (childhood) cancer predisposition syndrome, like Fanconi anaemia, ataxia telangiectasia, Bloom syndrome, Peutz–Jeghers syndrome, tuberous sclerosis and others. These syndromes are usually associated with characteristic anomalies that are not listed in table 5. Therefore, patients with signs specific for another cancer predisposition syndrome except for NF1 should first be tested for the other cancer predisposition syndrome. Patients who have clearly NF1-associated malignancies such as JMML or MPNST and signs reminiscent of NF1 should be first tested for a *NF1* mutation. There is also an overlap of CMMRD with Li Fraumeni syndrome (LFS). The tumour spectrum of the latter encompasses brain tumours and, to a lesser extent, haematological neoplasms. In families fulfilling Chompret's criteria,⁵² a *TP53* germline mutation should be ruled out first.

Diagnostic steps to substantiate the diagnosis CMMRD

Patients reaching a score of three points should be further analysed to confirm or refute the suspected diagnosis of CMMRD syndrome. The diagnostic steps in these patients largely follow the protocols developed for LS, which involves analysis of microsatellite instability (MSI) and/or immunohistochemical (IHC) staining of the four MMR proteins.

IHC analysis to assess the expression loss of the affected MMR protein can be effectively employed in all solid tumours of CMMRD patients and has the advantage to guide subsequent mutation analysis in the four MMR genes. In general, biallelic truncating mutations in *PMS2* or *MSH6* will result in isolated loss of these proteins, whereas mutations in *MLH1* or *MSH2* will lead to concurrent loss of *MLH1/PMS2* or *MSH2/MSH6*, respectively, since *MLH1* and *MSH2* are the obligatory partners in the formation of *MLH1/PMS2* and *MSH2/MSH6* heterodimers. Of note, in the case of an underlying missense mutation, IHC may show normal expression of the affected MMR gene, which may be a possible pitfall when using IHC analysis to confirm suspected CMMRD. In contrast to LS where expression loss is observed only in neoplastic cells, in CMMRD patients IHC detects expression loss of one (or two) of the MMR proteins in both neoplastic and non-neoplastic tissues. Hence, negative IHC staining in neoplastic and surrounding normal cells should not be interpreted as a failure of proper staining and care should be taken to use a (on slide) staining control from a different individual. In principle, expression loss of one of the MMR genes can also be demonstrated in blood lymphocytes of CMMRD patients, as shown by western blotting³⁷ but possibly also by IHC staining on cytospin preparations.

MSI tests for small misalignments, that is, insertion–deletion loops (IDL), which arise during DNA replication and remain uncorrected in the absence of a functional MMR system. It takes advantage of the fact that repeated-sequence motifs consisting of units of one, two or a few more nucleotides, that is, microsatellites, are frequent targets of IDL errors that result in shortening or lengthening of these sequence motifs, a

phenomenon termed MSI. In tissues derived from clonally proliferating MMR-deficient cells, that is, neoplastic cells, MSI is easily detected by PCR amplification and fragment analysis of a set of microsatellite markers.⁵³ MSI analysis following the current protocols for LS uses a panel of 5–6 dinucleotide⁵⁴ and/or mononucleotide⁵⁵ repeat markers. This approach is a reliable tool to diagnose MMR deficiency in gastrointestinal and other LS-associated tumours of CMMRD patients. However, standard MSI analysis as applied in LS frequently fails to show MSI in brain tumours^{42 56 57} and other malignancies.³⁰ Currently, the reasons for this observation are unknown, but it has been shown that more subtle shifts (shortening or lengthening) of microsatellite alleles can be observed also in brain tumours and may be indicative of CMMRD.⁵⁸ Furthermore, it might be worth testing whether a different panel of microsatellite markers would be more sensitive in brain and other tumours of CMMRD patients.

In principle, MSI can be observed also in DNA from normal, that is, non-neoplastic, cells of CMMRD patients. However, because altered microsatellite alleles are present only in a small proportion of the cells from normal tissue, so far most approaches used technically demanding single-molecule analyses (eg, small-pool PCR) to show MSI in normal tissue, that is, germline MSI (gMSI).⁵⁹ Recently, a much more simple method to detect gMSI was presented.⁶⁰ This assay relies on the analysis of 'stutter' peaks typically associated with microsatellite PCR products. When quantified by a novel publicly available software application, the relative peak height of the 'stutter' peaks of selected dinucleotide microsatellites significantly increases in DNA of CMMRD patients compared with normal controls as has been confirmed also in a larger cohort of samples (Bodo *et al.*, in preparation). The main limitation of this assay is that the relative peak height is not altered in patients with CMMRD due to biallelic *MSH6* mutations. Nevertheless, if this assay shows in a larger cohort of samples that it is a reliable, simple and rapid tool to detect CMMRD at least in patients with *PMS2*, *MLH1* or *MSH2* mutations, it would be a good screening tool and an alternative to IHC in cases where appropriate tissue is not available.

Taken together, both IHC staining of the MMR genes and MSI analysis are diagnostic methods to substantiate the suspected diagnosis. Since IHC will also guide target-gene mutation analysis and has been shown to render reliable results in most solid tumours, it is considered the preferred method. But as outlined, both methods have potential pitfalls and may fail to confirm the suspected diagnosis. Therefore, we recommend combining both assays if needed. The final confirmation of the diagnosis CMMRD should come from the determination of the causative biallelic mutations in the patient.

Counselling and genetic testing

According to the recommendations of national and international human genetic societies and the legislation of most European countries, genetic counselling must be offered to the patients and/or their parents prior to performing mutation analysis in the affected child. Patients and/or their parents should be informed by a team of paediatric oncologists and medical geneticists about the suspected diagnosis if this is substantiated by MSI and/or IHC analysis. Considering the burden of this syndrome, psychological support should systematically be proposed to families. The family has to be informed of potential therapeutic implications of the test result and also of the high risk for a second malignancy in a patient with a positive test result. Genetic counselling must also include information on the

potential 25% recurrence risk in a sibling and on the risks for LS-associated cancer in possible heterozygous mutation carriers, particularly both parents.

With the informed consent of the patient and/or the parents, mutation analysis will be initiated. Reliable and robust comprehensive analysis exists for all four MMR genes now including the historically difficult *PMS2* gene. However, when analysing *PMS2*, which is the affected gene in more than 50% of CMMRD patients, special care has to be taken to avoid pitfalls that arise from high prevalence of hybrid alleles that result from sequence exchange of the functional gene with its pseudogene *PMS2CL*.^{33 61–66}

Preferentially, targeted gene mutation analysis is performed. However, in cases where tumour tissue is not available for IHC analysis or the results are inconclusive, mutation analysis of all four MMR genes can be considered. It is expected that with the implementation of next-generation sequencing techniques this may be possible at reasonable costs in many laboratories in the near future.

CONCLUDING REMARKS

The earlier presented diagnostic criteria to suspect the diagnosis of CMMRD in a paediatric/young adult cancer patient are based on the findings of 146 patients. They are developed so that nearly all of these patients have ≥ 3 points according to the scoring system presented in table 5. The only exception are four patients who developed colon carcinomas as first malignancy at an age >25 years and who were earlier discussed to have a genotype and phenotype that represents an intermediate between LS and CMMRD (see ‘Diagnostic criteria that should raise the suspicion of CMMRD syndrome in a cancer patient’ ad (B)). Indication of CMMRD in such patients will come from IHC analysis of tumour tissue that will show loss of the affected protein not only in neoplastic but also normal mucosa cells. We tested the criteria also in an independent cohort of 23 patients of the French cohort who are to the largest part unreported. For all these patients, we obtained 9–13 points suggesting that the scoring system is highly sensitive. However, selection bias has to be kept in mind also for this cohort since also most of these patients were not selected using the proposed criteria but were identified because they had multiple malignancies and/or siblings with malignancies and/or colorectal carcinoma at an exceptionally young age. Hence, prospective studies are needed to evaluate the specificity as well as the sensitivity of the presented criteria.

Nevertheless, it is reasonable to expect that application of the suggested clinical criteria for CMMRD diagnosis will increase the number of patients being identified at the time when they develop their first tumour. This will allow to adjust treatment modalities and to offer surveillance strategies for (second) malignancies not only to the patient but also to siblings who carry also a biallelic MMR gene mutation. Still many of these patients will die from cancer. But a systematic collection and evaluation of all clinical data will help to improve the management in CMMRD. Therefore, patients, their siblings and parents should be asked to be included in an EU registry that will be established by the C4CMMRD consortium. Data analysis of these patients and also their siblings and parents will allow determining the true cancer risk and tumour spectrum of CMMRD.

Author affiliations

¹Division of Human Genetics, Medical University Innsbruck, Innsbruck, Austria
²Department of Pediatric Hematology & Oncology, Hannover Medical School, Hannover, Germany

³Department of Gastroenterology & Hepatology, Leiden University Medical Centre, Leiden, The Netherlands
⁴Department of Medical Oncology, Gustave Roussy Cancer Institute, Villejuif, France
⁵Department of Genetics, Pitié Salpêtrière Hospital, AP-HP, Paris, France
⁶INSERM, UMR_S 938, CDR Saint-Antoine, Paris, France
⁷Sorbonne Universités, UPMC Univ Paris 06, UMR_S 938, CDR Saint-Antoine, Paris, France
⁸Pédiatrie Onco-Hématologie—Pédiatrie III—CHRU Hautepierre UdS—EA 3430, Strasbourg, France
⁹Department of Clinical Genetics, Copenhagen University Hospital Rigshospital, Copenhagen, Denmark
¹⁰Department of Oncology, Sharret Institute, Hadassah—Hebrew University Medical Center, Jerusalem, Israel
¹¹2nd Pediatric Department of Children University Hospital, Comenius University, Bratislava, Slovakia
¹²Department of Children and Adolescents Oncology, Gustave Roussy Cancer Institute, Villejuif, France
¹³Fundación Pública Galega de Medicina Xenómica (FPGMX) SERGAS, Grupo de Medicina Xenómica, IDIS, Centro de Investigación Biomédica en Red de Enfermedades Raras (CIBERer), Santiago de Compostela, Spain
¹⁴Department of Pediatrics, Medical University of Vienna, Vienna, Austria
¹⁵Department of Pediatric Hematology and Oncology, University Children’s Hospital, Münster, Germany

Contributors All authors provided data (updates) of patients analysed in this study and/or contributed to the discussion that led to the recommendations for the clinical suspected diagnosis on CMMR D. All authors read and revised the manuscript and approved the content of the submitted manuscript.

Competing interests None.

Provenance and peer review Not commissioned; externally peer reviewed.

REFERENCES

- Peltomaki P. Role of DNA mismatch repair defects in the pathogenesis of human cancer. *J Clin Oncol* 2003;21:1174–9.
- Aaltonen LA, Peltomaki P, Leach FS, Sistonen P, Pylkkanen L, Mecklin JP, Jarvinen H, Powell SM, Jen J, Hamilton SR, Petersen G, Kinzler KW, Vogelstein B, de la Chapelle A. Clues to the pathogenesis of familial colorectal cancer. *Science* 1993;260:812–16.
- Lynch HT, de la Chapelle A. Hereditary colorectal cancer. *N Engl J Med* 2003;348:919–32.
- Lynch HT, Lynch JF, Attard TA. Diagnosis and management of hereditary colorectal cancer syndromes: Lynch syndrome as a model. *CMAJ* 2009;181:273–80.
- Ricciardone MD, Ozcelik T, Cevher B, Ozdag H, Tuncer M, Gurgey A, Uzunalimoglu O, Cetinkaya H, Tanyeli A, Erken E, Ozturk M. Human MLH1 deficiency predisposes to hematological malignancy and neurofibromatosis type 1. *Cancer Res* 1999;59:290–3.
- Wang Q, Lasset C, Desseigne F, Frappaz D, Bergeron C, Navarro C, Ruano E, Puisieux A. Neurofibromatosis and early onset of cancers in hMLH1-deficient children. *Cancer Res* 1999;59:294–7.
- Scott RH, Mansour S, Pritchard-Jones K, Kumar D, MacSweeney F, Rahman N. Medulloblastoma, acute myelocytic leukemia and colonic carcinomas in a child with biallelic MSH6 mutations. *Nat Clin Pract Oncol* 2007;4:130–4.
- Wimmer K, Etzler J. Constitutional mismatch repair-deficiency syndrome: have we so far seen only the tip of an iceberg? *Hum Genet* 2008;124:105–22.
- Turcot J, Despres JP, St Pierre F. Malignant tumors of the central nervous system associated with familial polyposis of the colon: report of two cases. *Dis Colon Rectum* 1959;2:465–8.
- Hamilton SR, Liu B, Parsons RE, Papadopoulos N, Jen J, Powell SM, Krush AJ, Berk T, Cohen Z, Tetu B, Burger PC, Wood PA, Taqi F, Booker SV, Petersen GM, Offerhaus GJA, Tersmette AC, Giardiello FM, Vogelstein B, Kinzler KW. The molecular basis of Turcot’s syndrome. *N Engl J Med* 1995;332:839–47.
- Hackman P, Tannergard P, Osei-Mensa S, Chen J, Kane MF, Kolodner R, Lambert B, Hellgren D, Lindblom A. A human compound heterozygote for two MLH1 missense mutations. *Nat Genet* 1997;17:135–6.
- Liu T, Tannergard P, Hackman P, Rubio C, Kressner U, Lindmark G, Hellgren D, Lambert B, Lindblom A. Missense mutations in hMLH1 associated with colorectal cancer. *Hum Genet* 1999;105:437–41.
- Senter L, Clendenning M, Sotamaa K, Hampel H, Green J, Potter JD, Lindblom A, Lagerstedt K, Thibodeau SN, Lindor NM, Young J, Winship I, Dowty JG, White DM, Hopper JL, Baglietto L, Jenkins MA, de la Chapelle A. The clinical phenotype of Lynch syndrome due to germ-line *PMS2* mutations. *Gastroenterology* 2008;135:419–28.
- Truningher K, Menigatti M, Luz J, Russell A, Haider R, Gebbers JO, Bannwart F, Yurtsever H, Neuweiler J, Riehle HM, Cattaruzza MS, Heinemann K, Schar P,

- Jiricny J, Marra G. Immunohistochemical analysis reveals high frequency of PMS2 defects in colorectal cancer. *Gastroenterology* 2005;128:1160–71.
- 15 Gallinger S, Aronson M, Shayan K, Ratcliffe EM, Gerstle JT, Parkin PC, Rothenmund H, Croitoru M, Baumann E, Durie PR, Weksberg R, Pollett A, Riddell RH, Ngan BY, Cutz E, Lagarde AE, Chan HS. Gastrointestinal cancers and neurofibromatosis type 1 features in children with a germline homozygous MLH1 mutation. *Gastroenterology* 2004;126:576–85.
- 16 Ilencikova D, Sejnova D, Jindrova J, Babal P. High-grade brain tumors in siblings with biallelic MSH6 mutations. *Pediatr Blood Cancer* 2011;57:1067–70.
- 17 Raevaara TE, Gerdes AM, Lonnqvist KE, Tybjaerg-Hansen A, Abdel-Rahman WM, Kariola R, Peltomaki P, Nystrom-Lahti M. HNPCC mutation MLH1 P648S makes the functional protein unstable, and homozygosity predisposes to mild neurofibromatosis type 1. *Genes Chromosomes Cancer* 2004;40:261–5.
- 18 Durno CA, Aronson M, Tabori U, Malkin D, Gallinger S, Chan HS. Oncologic surveillance for subjects with biallelic mismatch repair gene mutations: 10 year follow-up of a kindred. *Pediatr Blood Cancer* 2012;59:652–6.
- 19 Kets CM, Hoogerbrugge N, van Krieken JH, Goossens M, Brunner HG, Ligtenberg MJ. Compound heterozygosity for two MSH2 mutations suggests mild consequences of the initiation codon variant c.1A>G of MSH2. *Eur J Hum Genet* 2009;17:159–64.
- 20 Kratz CP, Holter S, Etzler J, Lauten M, Pollett A, Niemeyer CM, Gallinger S, Wimmer K. Rhabdomyosarcoma in patients with constitutional mismatch-repair-deficiency syndrome. *J Med Genet* 2009;46:418–20.
- 21 Sung L, Anderson JR, Arndt C, Raney RB, Meyer WH, Pappo AS. Neurofibromatosis in children with Rhabdomyosarcoma: a report from the Intergroup Rhabdomyosarcoma study IV. *J Pediatr* 2004;144:666–8.
- 22 Toledano H, Goldberg Y, Kedar-Barnes I, Baris H, Porat RM, Shochat C, Bercovich D, Pikarsky E, Lerer I, Yaniv I, Abeliovich D, Peretz T. Homozygosity of MSH2 c.1906G->C germline mutation is associated with childhood colon cancer, astrocytoma and signs of Neurofibromatosis type I. *Fam Cancer* 2009;8:187–94.
- 23 Herkert JC, Niessen RC, Olderde-Berends MJ, Veenstra-Knol HE, Vos YJ, van der Klift HM, Scheenstra R, Tops CM, Karrenbeld A, Peters FT, Hofstra RM, Kleibeuker JH, Sijmons RH. Paediatric intestinal cancer and polyposis due to bi-allelic PMS2 mutations: case series, review and follow-up guidelines. *Eur J Cancer* 2011;47:965–82.
- 24 Jasperson KW, Samowitz WS, Burt RW. Constitutional mismatch repair-deficiency syndrome presenting as colonic adenomatous polyposis: clues from the skin. *Clin Genet* 2011;80:394–7.
- 25 Holter S, Pollett A, Zogopoulos G, Kim H, Schwenter F, Asai K, Gallinger S, Clendenning M, Steinbach G, Jacobson A, Boycott KM. Hepatic adenomas caused by somatic HNF1A mutations in children with biallelic mismatch repair gene mutations. *Gastroenterology* 2011;140:735–6.
- 26 Yeung JT, Pollack IF, Shah S, Jaffe R, Nikiforova M, Jakacki RI. Optic pathway glioma as part of a constitutional mismatch-repair deficiency syndrome in a patient meeting the criteria for neurofibromatosis type 1. *Pediatr Blood Cancer* 2013;60:137–9.
- 27 Ostergaard JR, Sunde L, Okkels H. Neurofibromatosis von Recklinghausen type I phenotype and early onset of cancers in siblings compound heterozygous for mutations in MSH6. *Am J Med Genet A* 2005;139:96–105; discussion 96.
- 28 Chmara M, Wernstedt A, Wasag B, Peeters H, Renard M, Beert E, Brems H, Giner T, Bieber I, Hamm H, Sciôt R, Wimmer K, Legius E. Multiple pilomatricomas with somatic CTNNB1 mutations in children with constitutive mismatch repair deficiency. *Genes Chromosomes Cancer* 2013;52:656–64.
- 29 Baglioni S, Melean G, Gensini F, Santucci M, Scatizzi M, Papi L, Genuardi M. A kindred with MYH-associated polyposis and pilomatricomas. *Am J Med Genet A* 2005;134A:212–14.
- 30 Baas AF, Gabbett M, Rimac M, Kansikas M, Raphael M, Nievelstein RA, Nicholls W, Offerhaus J, Bodmer D, Wernstedt A, Krabichler B, Strasser U, Nystrom M, Zschocke J, Robertson SP, van Haelst MM, Wimmer K. Agenesis of the corpus callosum and gray matter heterotopia in three patients with constitutional mismatch repair deficiency syndrome. *Eur J Hum Genet* 2013;21:55–61.
- 31 Rahner N, Hoefler G, Hogenauer C, Lackner C, Steinke V, Sengteller M, Friedl W, Aretz S, Propping P, Mangold E, Walldorf C. Compound heterozygosity for two MSH6 mutations in a patient with early onset colorectal cancer, vitiligo and systemic lupus erythematosus. *Am J Med Genet A* 2008;146A:1314–19.
- 32 Sijmons RH, Bjernevoll I, Engebretsen LF, Fjelland K, Halvorsen T, Myrvold HE. A homozygote splice site PMS2 mutation as cause of Turcot syndrome gives rise to two different abnormal transcripts. *Fam Cancer* 2009;8:179–86.
- 33 Vaughn CP, Hart KJ, Samowitz WS, Swensen JJ. Avoidance of pseudogene interference in the detection of 3' deletions in PMS2. *Human mutation* 2011;32:1063–71.
- 34 Auclair J, Leroux D, Desseigne F, Lasset C, Saurin JC, Joly MO, Pinson S, Xu XL, Montmain G, Ruano E, Navarro C, Puisieux A, Wang Q. Novel biallelic mutations in MSH6 and PMS2 genes: gene conversion as a likely cause of PMS2 gene inactivation. *Hum Mutat* 2007;28:1084–90.
- 35 Alotaibi H, Ricciardone MD, Ozturk M. Homozygosity at variant MLH1 can lead to secondary mutation in NF1, neurofibromatosis type I and early onset leukemia. *Mutat Res* 2008;637:209–14.
- 36 Gardes P, Forveille M, Alyanikian MA, Aucouturier P, Ilencikova D, Leroux D, Rahner N, Mazerolles F, Fischer A, Kracker S, Durandy A. Human MSH6 Deficiency Is Associated with Impaired Antibody Maturation. *J Immunol* 2012;188:2023–9.
- 37 Peron S, Metin A, Gardes P, Alyanikian MA, Sheridan E, Kratz CP, Fischer A, Durandy A. Human PMS2 deficiency is associated with impaired immunoglobulin class switch recombination. *J Exp Med* 2008;205:2465–72.
- 38 Whiteside D, McLeod R, Graham G, Steckley JL, Booth K, Somerville MJ, Andrew SE. A homozygous germ-line mutation in the human MSH2 gene predisposes to hematological malignancy and multiple cafe-au-lait spots. *Cancer Res* 2002;62:359–62.
- 39 Gururangan S, Frankel W, Broadus R, Clendenning M, Senter L, McDonald M, Eastwood J, Reardon D, Vredenburg J, Quinn J, Friedman HS. Multifocal anaplastic astrocytoma in a patient with hereditary colorectal cancer, transcobalamin II deficiency, agenesis of the corpus callosum, mental retardation, and inherited PMS2 mutation. *Neuro-oncology* 2008;10:93–7.
- 40 Furlanetti LL, Santos MV, Valera ET, Brassesco MS, de Oliveira RS. Metachronous occurrence of nonradiation-induced brain cavernous hemangioma and medulloblastoma in a child with neurofibromatosis type I phenotype. *J Pediatr Neurosci* 2012;7:43–6.
- 41 Plaschke J, Linnebacher M, Kloor M, Gebert J, Cremer FW, Tinschert S, Aust DE, von Knebel Doeberitz M, Schackert HK. Compound heterozygosity for two MSH6 mutations in a patient with early onset of HNPCC-associated cancers, but without hematological malignancy and brain tumor. *Eur J Hum Genet* 2006;14:561–6.
- 42 Leenen C, Geurts-Giele W, Dubbink H, Reddingius R, van den Ouweland A, Tops C, van de Klift H, Kuipers E, van Leerdaam M, Dinjens W, Wagner A. Pitfalls in molecular analysis for mismatch repair deficiency in a family with biallelic pms2 germline mutations. *Clin Genet* 2011;80:558–65.
- 43 Vasen HF, Ghorbanoghli Z, Bourdeaut F, Cabaret O, Caron O, Duval A, Entz-Werle N, Goldberg Y, Ilencikova D, Kratz CP, Lavoine N, Loeffen J, Menko FH, Muleris M, Sebille G, Colas C, Burkhardt B, Brugieres L, Wimmer K; on behalf of the EUConsortium C4CMRD. Guidelines for surveillance of individuals with constitutional mismatch repair-deficiency proposed by the European Consortium "Care for CMMR-D" (C4CMRD-D). *J Med Genet* 2014. [Epub ahead of print].
- 44 Scott RH, Homfray T, Huxter NL, Mitton SG, Nash R, Potter MN, Lancaster D, Rahman N. Familial T-cell non-Hodgkin lymphoma caused by biallelic MSH2 mutations. *J Med Genet* 2007;44:e83.
- 45 Allan JM, Travis LB. Mechanisms of therapy-related carcinogenesis. *Nat Rev Cancer* 2005;5:943–55.
- 46 Fedier A, Fink D. Mutations in DNA mismatch repair genes: implications for DNA damage signaling and drug sensitivity (review). *Int J Oncol* 2004;24:1039–47.
- 47 Palles C, Cazier JB, Howarth KM, Domingo E, Jones AM, Broderick P, Kemp Z, Spain SL, Guarino E, Salguero I, Sherborne A, Chubb D, Carvajal-Carmona LG, Ma Y, Kaur K, Dobbins S, Barclay E, Gorman M, Martin L, Kovac MB, Humphray S, Consortium C, Consortium WGS, Lucassen A, Holmes CC, Bentley D, Donnelly P, Taylor J, Petridis C, Roylance R, Sawyer EJ, Kerr DJ, Clark S, Grimes J, Kearsey SE, Thomas HJ, McVean G, Houlston RS, Tomlinson I. Germline mutations affecting the proofreading domains of POLE and POLD1 predispose to colorectal adenomas and carcinomas. *Nat Genet* 2013;45:136–44.
- 48 Bauchet L, Rigau V, Mathieu-Daude H, Fabbro-Peray P, Palenzuela G, Figarella-Branger D, Moritz J, Puget S, Bauchet F, Pallusseau L, Duffau H, Coubes P, Tretarre B, Labrousse F, Dhellemmes P; Societe Francaise de Neurochirurgie P, Societe Francaise de N, Societe Francaise de N, Association des Neuro-Oncologues d'Expression F. Clinical epidemiology for childhood primary central nervous system tumors. *J Neurooncol* 2009;92:87–98.
- 49 Burkhardt B, Zimmermann M, Oschlies I, Niggli F, Mann G, Parwaresch R, Riehm H, Schrappe M, Reiter A, Group BFM. The impact of age and gender on biology, clinical features and treatment outcome of non-Hodgkin lymphoma in childhood and adolescence. *Br J Haematol* 2005;131:39–49.
- 50 Burwell RG, James NJ, Johnston DI. Cafe-au-lait spots in schoolchildren. *Arch Dis Child* 1982;57:631–2.
- 51 Merks JH, Ozgen HM, Cluitmans TL, van der Burg-van Rijn JM, Cobben JM, van Leeuwen FE, Hennekam RC. Normal values for morphological abnormalities in school children. *Am J Med Genet A* 2006;140:2091–109.
- 52 Tinat J, Bougeard G, Baert-Desurmont S, Vasseur S, Martin C, Bouvignies E, Caron O, Bressac-de Paillerets B, Berthet P, Dugast C, Bonaiti-Pellie C, Stoppa-Lyonnet D, Frebourg T. 2009 version of the Chompret criteria for Li Fraumeni syndrome. *J Clin Oncol* 2009;27:e108–9; author reply e110.
- 53 Boland CR, Thibodeau SN, Hamilton SR, Sidransky D, Eshleman JR, Burt RW, Meltzer SJ, Rodriguez-Bigas MA, Fodde R, Ranzani GN, Srivastava S. A National Cancer Institute workshop on microsatellite instability for cancer detection and familial predisposition: development of international criteria for the determination of microsatellite instability in colorectal cancer. *Cancer Res* 1998;58:5248–57.
- 54 Umar A, Boland CR, Terdiman JP, Syngal S, de la Chapelle A, Ruschoff J, Fishel R, Lindor NM, Burgart LJ, Hamelin R, Hamilton SR, Hiatt RA, Jass J, Lindblom A, Lynch HT, Peltomaki P, Ramsey SD, Rodriguez-Bigas MA, Vasen HF, Hawk ET, Barrett JC, Freedman AN, Srivastava S. Revised Bethesda Guidelines for hereditary nonpolyposis colorectal cancer (Lynch syndrome) and microsatellite instability. *J Natl Cancer Inst* 2004;96:261–8.

- 55 Goel A, Nagasaka T, Hamelin R, Boland CR. An optimized pentaplex PCR for detecting DNA mismatch repair-deficient colorectal cancers. *PLoS ONE* 2010;5:e9393.
- 56 Bougeard G, Charbonnier F, Moerman A, Martin C, Ruchoux MM, Drouot N, Frebourg T. Early onset brain tumor and lymphoma in MSH2-deficient children. *Am J Hum Genet* 2003;72:213–16.
- 57 Poley JW, Wagner A, Hoogmans MM, Menko FH, Tops C, Kros JM, Reddingius RE, Meijers-Heijboer H, Kuipers EJ, Dinjens WN. Biallelic germline mutations of mismatch-repair genes: a possible cause for multiple pediatric malignancies. *Cancer* 2007;109:2349–56.
- 58 Giunti L, Cetica V, Ricci U, Giglio S, Sardi I, Paglierani M, Andreucci E, Sanzo M, Forni M, Buccoliero AM, Genitori L, Genuardi M. Type A microsatellite instability in pediatric gliomas as an indicator of Turcot syndrome. *Eur J Hum Genet* 2009;17:919–27.
- 59 Parsons R, Myeroff LL, Liu B, Willson JK, Markowitz SD, Kinzler KW, Vogelstein B. Microsatellite instability and mutations of the transforming growth factor beta type II receptor gene in colorectal cancer. *Cancer Res* 1995;55:5548–50.
- 60 Ingham D, Diggle CP, Berry I, Bristow CA, Hayward BE, Rahman N, Markham AF, Sheridan EG, Bonthron DT, Carr IM. Simple detection of germline microsatellite instability for diagnosis of constitutional mismatch repair cancer syndrome. *Hum Mutat* 2013;34:847–52.
- 61 Etzler J, Peyrl A, Zatkova A, Schildhaus HU, Ficek A, Merkelbach-Bruse S, Kratz CP, Attarbaschi A, Hainfellner JA, Yao S, Messiaen L, Slavic I, Wimmer K. RNA-based mutation analysis identifies an unusual MSH6 splicing defect and circumvents PMS2 pseudogene interference. *Hum Mutat* 2008;29:299–305.
- 62 Ganster C, Wernstedt A, Kehrer-Sawatzki H, Messiaen L, Schmidt K, Rahner N, Heinemann K, Fonatsch C, Zschocke J, Wimmer K. Functional PMS2 hybrid alleles containing a pseudogene-specific missense variant trace back to a single ancient intrachromosomal recombination event. *Hum Mutat* 2010;31:552–60.
- 63 Hayward BE, De Vos M, Valleley EM, Charlton RS, Taylor GR, Sheridan E, Bonthron DT. Extensive gene conversion at the PMS2 DNA mismatch repair locus. *Hum Mutat* 2007;28:424–30.
- 64 van der Klift HM, Tops CM, Bik EC, Boogaard MW, Borgstein AM, Hansson KB, Ausems MG, Gomez Garcia E, Green A, Hes FJ, Izatt L, van Hest LP, Alonso AM, Vriends AH, Wagner A, van Zelst-Stams WA, Vasen HF, Morreau H, Devilee P, Wijnen JT. Quantification of sequence exchange events between PMS2 and PMS2CL provides a basis for improved mutation scanning of Lynch syndrome patients. *Hum Mutat* 2010;31:578–87.
- 65 Vaughn CP, Robles J, Swensen JJ, Miller CE, Lyon E, Mao R, Bayrak-Toydemir P, Samowitz WS. Clinical analysis of PMS2: mutation detection and avoidance of pseudogenes. *Hum Mutat* 2010;31:588–93.
- 66 Wernstedt A, Valtorta E, Armelao F, Togni R, Girlando S, Baudis M, Heinemann K, Messiaen L, Staehli N, Zschocke J, Marra G, Wimmer K. Improved multiplex ligation-dependent probe amplification analysis identifies a deleterious PMS2 allele generated by recombination with crossover between PMS2 and PMS2CL. *Genes Chromosomes Cancer* 2012;51:819–31.

Supplementary Table S1: Publications reporting of CMMR-D patients

Authors, year	PMID no.	no. families	no. patients	patients also published by	PMID #
Ricciardone et al., 1999	9927033	1	3	Alotaibi et al., 2008	17889038
Wang et al., 1999	9927034	1	2		
Miyaki et al., 1997	9419979	1	1		
Hamilton et al., 1995,	7661930	1	2	Taylor et al., 1999, De Vos et al., 2004	10223463 15077197
De Rosa et al., 2000	10763829	1	2		
Trimbath et al., 2001	14574005	1	3	Shalon et al., 1997	9252914
Vilkki et al., 2001	11389087	1	1		
Whiteside et al., 2002	11809679	1	1		
Bougeard et al., 2003	12549480	1	2		
Raevaara et al., 2004	15139004	1	1		
Gallinger et al., 2004	14762794	1	3	Durno et al., 2005 Durno et al., 2011 Holter et al., 2011	15845562 22180144 21182953
Rey et al., 2004	15571801	1	1		
De Vos et al., 2004	15077197	1	4	Durno et al., 2005,	15845562
Menko et al., 2004	15340263	1	1		
Hegde et al., 2005	16000562	1	2		
Ostergaard et al., 2005	16283678	1	2		
Agostini et al., 2005	16144131	1	1		
Müller et al., 2006	16372347	1	2		
Marcos et al., 2006	16769400	1	1		
			10		
De Vos et al., 2006	16507833	5	(1+2+3+3+1)		
Plaschke et al., 2006	16418736	2	2 (1+1)		
Scott et al., 2007b	17259933	1	1		
Will et al., 2007	17258725	1	1		
Auclair et al., 2007	17557300	2	4(2+2)		
Poley et al., 2007	17440981	1	1	Wagner et al., 2003, Fam Cancer 2(Suppl 1):57	
Scott et al., 2007a	17601929	1	3		
Toledano et al., 2008	19101824	1	2		
Kratz et al., 2008	18007577	1	2		
Etzler et al., 2008	18030674	2	3 (2+1)		
Rahner et al., 2008	18409202	1	1		
Krüger et al., 2008	17851451	2	6 (4+2)	Gottschling et al., 2008	17851451
Gururangan et al., 2008	17993636	1	2		
Tan et al., 2008	18376293	1	2		
Jackson et al., 2008	18273873	1	1	Holter et al., 2011	21182953

Senter et al., 2008	18602922	5	5 (1+1+1+1+1)	Roy et al., 2009	19283792
Sjursen et al., 2008	19039682	1	2		
Kets et al., 2009	18781192	1	2		
Kratz et al. 2009	19293170	1	1		
Giunti et al., 2009	19156169	2	5 (2+3)		
Peters et al. 2009	19194194	1	1		
Ripperger et al., 2010	20015892	1	1		
Vaughn et al. 2010	20205264	5	5 (1+1+1+1+1)		
Jaspersen et al. 2010	21039432	1	2		
Holter et al., 2011	21182953	1	1		
Ilencikova et al., 2011	21674763	1	3		
Vaughn et al. 2011	21618646	1	1		
Plon et al., 2011	21356188	1	2		
Herkert et al., 2011	21376568	4	5 (1+2+1+1)		
Johannesma et al., 2011	21261604	1	2		
Leenen et al. 2011	21204794	1	2		
Yeung et al. 2012	22848017	1	1		
Baas et al. 2012	22692065	3	3 (1+1+1)		
Vasovcak et al. 2012	22608206	1	1		
Furlanetti et al. 2012*	22837778	1	2		
Chmara et al. 2013	23629955	2	3 (1+2)		
Lindsay et al. 2013	23582141	1	1		
total		79	127		
Unpublished patients data collected by Austrian, French, Israeli and Spanish consortium members **					
		12	19		
total (published and unpublished cases)		91	146		

* diagnosis in this patient was confirmed by identification of a homozygous MSH6 germ line mutation (Wimmer & Furlanetti unpublished results)

Supplementary Table S2: Malignancies in 146 CMMR-D patients separated by genotype

Malignancies	Number of tumors	Median age at diagnosis in years	Age range at diagnosis in years	Number of tumors	Median age at diagnosis in years	Age range at diagnosis in years	Number of tumors	Median age at diagnosis in years	Age range at diagnosis in years	Number of tumors	Median age at diagnosis in years	Age range at diagnosis in years
	total			MLH1/MSH2			MSH6			PMS2		
Haematological malignancies												
non-Hodgkin's lymphoma	31	5	0.4 - 17	10	2.5	0.4 - 10	7	6	3 - 11	14	9	3 - 17
lymphoid leukemia	9	6	2 - 21	1	2		1	6		7	6	2 - 21
acute myeloid leukemia	5	9.5	6 - 17	2	2	2 & n.k.	2	9.5	9 & 10	1	17	
malignant lymphoma	1	15		0			0			1	15	
atypical chronic myeloid leukemia	1	1		1	1		0			0		
acute leukemia	1	2		1	2		0			0		
total	48	6	0.4 - 21	15	2,5	0.4 - 10	10	7	3 - 11	23	9	2 - 21
Malignant brain and central nervous system tumour												
high grade gliomas	58	9.5	2 - 40	10	8	3 - 14	14	9	2 - 16	34	10	2 - 40
sPNET	8	8	4 - 17	0			0			8	8	4 - 17
medulloblastoma	7	7	4 - 12	2	7	7 & n.k.	3	6	4 - 7	2	9.5	7 & 12
infiltrating cerebral angiosarcoma	1	2		0			0			1	2	
cerebral anaplastic glioma	1	9		0			0			1	9	
papillary ganglioneural tumor	1	11		0			0			1	11	
not specified brain tumor	5	8	4 - 24	0			0			5	8	4 - 24
total	81	9	2 - 40	12	7	3 - 14	17	9	2 - 16	52	9	2 - 40
LS-associated carcinomas												
colon/rectum *	59	16	8 - 48	12	13	9 - 48	8	14.5	8 - 31	39	16	9 - 32
duodenum/jejunum/ileum	18	28	11 - 42	3	16	11 - 39	0			15	30	15 - 42
endometrium	6	28	23 - 44	1	44		1	24		4	27.5	23 - 35
bladder/ureter (papillary transitional cells)	2	20	19 & 21	0			0			2	20	19 & 21
ureter/renal pelvis (unspecified)	2	19	15 & 22	0			0			2	19	15 & 22
ovaries	1	17		0			0			1	17	
total	88	17	8 - 48	16	14.5	9 - 48	9	16	8 - 31	63	19	9 - 42
Others												
neuroblastoma	1	13		0			0			1	13	
nephroblastoma (Wilms tumour)	1	4		1	4		0			0		
ovarian neuroectodermal tumour	1	21		0			0			1	21	
infantile myofibromatosis	1	1		0			0			1	1	
rhabdomyosarcoma	1	4		0			0			1	4	
basal cell carcinoma	1	n.r.		0			0			1	n.r.	
muco-epidermoid ca. of parotis	1	11		0			0			1	11	
osteosarcoma	1	24		0			0			1	24	
total	8			1			8			7		

* multiple synchronous bowel carcinomas were counted as one malignancy; n.k. = not known