

Hemizygous mutations in SNAP29 unmask autosomal recessive conditions and contribute to atypical findings in patients with 22q11.2DS

Donna M McDonald-McGinn,¹ Somayyeh Fahiminiya,² Timothée Revil,² Beata A Nowakowska,³ Joshua Suhl,⁴ Alice Bailey,¹ Elisabeth Mlynarski,¹ David R Lynch,⁵ Albert C Yan,⁶ Larissa T Bilaniuk,⁷ Kathleen E Sullivan,⁸ Stephen T Warren,⁴ Beverly S Emanuel,^{1,9} Joris R Vermeesch,¹⁰ Elaine H Zackai,^{1,9} Loydie A Jerome-Majewska^{2,11}

► Additional supplementary data are published online only. To view these files please visit the journal online (<http://dx.doi.org/10.1136/jmedgenet-2012-101320>).

For numbered affiliations see end of article

Correspondence to

Dr Loydie A Jerome-Majewska, Department of Pediatrics and Human Genetics, McGill University Research Institute, Place Toulon, 4060 Ste Catherine West PT 420, Montreal, QC H3Z 2Z3, Canada; loydie.majewska@mcgill.ca

DMM-M and SF contributed equally to this work

Received 24 September 2012
Revised 10 November 2012
Accepted 13 November 2012
Published Online First
11 December 2012

ABSTRACT

Background 22q11.2 deletion syndrome (22q11.2DS) is the most common microdeletion disorder, affecting an estimated 1 : 2000–4000 live births. Patients with 22q11.2DS have a broad spectrum of phenotypic abnormalities which generally includes congenital cardiac abnormalities, palatal anomalies, and immunodeficiency. Additional findings, such as skeletal anomalies and autoimmune disorders, can confer significant morbidity in a subset of patients. 22q11.2DS is a contiguous gene DS and over 40 genes are deleted in patients; thus deletion of several genes within this region contributes to the clinical features. Mutations outside or on the remaining 22q11.2 allele are also known to modify the phenotype.

Methods We utilised whole exome, targeted exome and/or Sanger sequencing to examine the genome of 17 patients with 22q11.2 deletions and phenotypic features found in <10% of affected individuals.

Results and conclusions In four unrelated patients, we identified three novel mutations in *SNAP29*, the gene implicated in the autosomal recessive condition cerebral dysgenesis, neuropathy, ichthyosis and keratoderma (CEDNIK). *SNAP29* maps to 22q11.2 and encodes a soluble SNARE protein that is predicted to mediate vesicle fusion at the endoplasmic reticulum or Golgi membranes. This work confirms that the phenotypic variability observed in a subset of patients with 22q11.2DS is due to mutations on the non-deleted chromosome, which leads to unmasking of autosomal recessive conditions such as CEDNIK, Kousseff, and a potentially autosomal recessive form of Opitz G/BBB syndrome. Furthermore, our work implicates *SNAP29* as a major modifier of variable expressivity in 22q11.2 DS patients.

INTRODUCTION

Although clinically under-recognised, the 22q11.2 deletion syndrome (22q11.2DS) is the most common microdeletion disorder with an estimated prevalence of 1 in 2000–4000 live births. Individuals with 22q11.2DS most often have a classically associated 3 MB deletion. However, smaller atypical nested deletions have been reported, all of which result in a broad spectrum of phenotypic abnormalities.^{1–2} The occurrences of deletions in this region are related to

the architecture of chromosome 22q11.2 and are associated with a non-allelic homologous recombination between chromosome specific low copy repeats (LCRs) or segmental duplications.³ The larger 3 MB deletion is associated with recombination between LCRs-A and D. Furthermore, although the smaller atypical nested deletions are predominantly mediated by LCRs A-B, they also include deletions involving LCRs B-D or C-D. In general, the associated clinical findings include: congenital cardiac abnormalities, palatal anomalies, and immunodeficiency in about three-quarters of patients; hypoparathyroidism in approximately half; and gastrointestinal and renal anomalies in about one-third.^{4–6} Additional findings can confer significant morbidity, such as autoimmune disease and skeletal anomalies, but are generally identified in only a subset of patients.⁷ Lastly, developmental delay, intellectual deficits, and psychiatric disorders such as schizophrenia are important features of this diagnosis.⁸

Although as many as 40 genes are deleted in patients with 22q11.2DS, mouse models of 22q11.2DS support a strong role for haploinsufficiency of *TBX1*, a T-Box gene in the A-B deleted region. *TBX1* has been implicated in association with several clinical findings, in particular congenital heart disease.⁹ In patients with atypical deletions that do not include *TBX1*, the adaptor protein *CRKL* has emerged as a strong candidate for additional associated features.¹⁰ In addition, a significant number of patients with 22q11.2DS have less common findings such as polymicrogyria, myelomeningocele, cleft lip, and genitourinary abnormalities that cannot be explained solely by haploinsufficiency for *TBX1* and/or *CRKL*. However, 22q11.2DS is considered a contiguous gene deletion syndrome as it has been proposed that loss of several or all genes within the region may contribute to the broad phenotype observed in patients.¹¹

Next-generation sequencing advances, such as whole exome sequencing, enables identification of rare variants that may be damaging and therefore disease producing.¹² This new technology permits examination of the genome including the non-deleted allele for mutations that may contribute to variable phenotypic expression in deletion syndromes. Thus, we utilised whole or targeted exome

To cite: McDonald-McGinn DM, Fahiminiya S, Revil T, et al. *J Med Genet* 2013;**50**:80–90.

sequencing in patients with a 22q11.2 deletion and phenotypic features found in <10% of affected individuals and identified damaging mutations in *SNAP29*, the gene implicated in the autosomal recessive condition cerebral dysgenesis, neuropathy, ichthyosis and keratoderma (CEDNIK).^{13–14} *SNAP29* is located within the C-D region on chromosome 22q11.2. Heterozygous mutations of *SNAP29* have also been reported in association with cryptorchidism and hypospadias.¹⁵ Furthermore, single nucleotide polymorphisms (SNPs) in the promoter of *SNAP29* have been associated with schizophrenia.¹⁶

SNAP29 (synaptosomal associated protein 29KDa) is a soluble SNARE protein that is predicted to mediate vesicle fusion at the endoplasmic reticulum or Golgi membranes.¹⁷ *SNAP29* was shown to be highly expressed in myelinating glia¹⁸ and is required for lamellar body formation in the skin. It is also indirectly required for $\beta 1$ integrin endocytosis and cell migration.¹⁹ We report that hemizygous deletions of 22q11.2, combined with damaging mutations in *SNAP29*, contribute to atypical clinical findings in patients with 22q11.2DS. Specifically, this combination unmasks one previously described autosomal recessive condition (CEDNIK), and may unmask and confirm another condition previously debated in the literature (Kousseff syndrome). It also may provide an explanation for overlapping features with a third heterogeneous condition (Opitz G/BBB syndrome).

PATIENTS AND METHODS

The study was approved by the Institutional Review Board of the Children's Hospital of Philadelphia (07-005352) with appropriate informed consent obtained on all subjects. In addition, the study data were handled in compliance with HIPAA (Health Insurance Portability and Accountability Act) regulations. We recruited individuals from The '22q and You' Center at The Children's Hospital of Philadelphia, a large comprehensive multidisciplinary programme for patients with 22q11.2DS, for inclusion in a study of atypical clinical findings (present in <10% of overall cohort) at McGill University in Montreal, Canada and the University of Leuven in Leuven, Belgium. These findings initially included laryngo-tracheal-oesophageal abnormalities and limb differences, but were later expanded to include polymicrogyria, myelomeningocele, cleft lip, and genitourinary abnormalities. In total, 17 individuals with 22q11.2DS were studied (table 1). Whole exome sequencing was performed on four patients (patients 1, 5–7); targeted exome sequencing was performed on patient 4 and Sanger sequencing was used to screen for the presence of mutations within the gene *SNAP29* in 12 patients. A detailed synopsis of the clinical findings in the patients with mutations in *SNAP29* is provided in the supplementary data (patients 1–4).

Whole exome sequencing and variant analysis

Whole exome capture was performed using the TruSeq Exome Enrichment Kit (Illumina, San Diego, California, USA), which targets 62 Mb of exonic sequences including 5' untranslated region (UTR), 3'UTR, microRNA and other non-coding RNAs. The targeted exons were sequenced using paired-end technology (Illumina HiSeq sequencer) with read lengths of 100 bp. The generated exome sequencing data were analysed using our optimised bioinformatics pipeline as previously described.²⁰ Briefly, the high quality trimmed paired-end sequences were aligned to the human reference genome (hg19) using Burrows-Wheeler Aligner (BWA) (v.0.5.9)²¹ Unmapped reads, reads mapping to multiple locations and PCR duplicates (PICARD V1.48) were discarded in further analyses. A mean coverage of 66X (patient

1), 91X (patient 5), 78X (patient 6), and 76X (patient 7) was obtained for all consensus coding sequence exons.

The variant positions on the reference genome were determined using Samtools (v.0.1.17),²² mpileup and varFilter with the base alignment quality adjustment disabled, leading to the identification of approximately 299K (patient 1), 286K (patient 5), 265K (patient 6), and 269K (patient 7) variants. Additional filters were applied to narrow down the list of candidate rare variants. First, a minimum of two variant reads and >20% single nucleotide variants or >15% indels (small insertions or deletions) variant reads were considered for each called position. In order to remove systematic false positives and common polymorphisms, the variants were filtered against our in-house exome database (>350 exomes) and removed from further analysis if seen in more than five control exomes.

Subsequently, ANNOVAR²³ was used to annotate the remaining variants according to the type of mutation, whether the variant was present in dbSNP132, minor allele frequency in the 1000 Genomes project, exome variant server (EVS), SIFT, PolyPhen-2 and PFASTCONS scores. Based on the assumption that the potential damaging variants are rare, the variants were kept in the final list if they had an allele frequency <0.05 in the 1000 Genomes database and predicted to be non-synonymous, that is, missense, nonsense, frameshift, or canonical splice site changes. A summary of the data obtained from each step of exome sequencing analysis is presented in supplementary table 1.

Targeted exome sequencing and analysis

The mutation in patient 4 was identified using a custom Agilent SureSelect XT target enrichment system to capture the ~3 Mb interval of the intact chr22q11.2. Sequencing was performed using the Illumina HiScan SQ platform with 50 bp paired end reads. The reads were mapped and annotated using the Emory Mapper (Cutler and Zwick, unpublished data) and the results were bioinformatically filtered to help ensure a low level of false-positive nucleotide calls.

Sanger sequencing and analysis

To screen the *SNAP29* gene, genomic DNA was extracted from whole blood using the Wizard Genomic DNA Purification Kit (Promega), following the manufacturer's instructions. All sequences, with the exception of exon 1, were amplified using 50 ng of genomic DNA and Platinum Taq Hifi DNA polymerase (Invitrogen), using the standard protocol and a T^m of 58°C. Exon 1 was amplified using Platinum Pfx DNA polymerase (Invitrogen), with a final concentration of 2× PCR_XEnhancer Solution and a T^m of 55°C. Sanger sequencing was performed at the McGill University and Génome Québec Innovation Centre, using the forward primer on the unpurified PCR products. Resulting sequences were compared using BioEdit (<http://www.mbio.ncsu.edu/bioedit/bioedit.html>). Primers were designed by web-based Primer 3 (<http://primer3.sourceforge.net/>).

To determine the impact of novel amino acid substitutions on the *SNAP29* protein, the PolyPhen-2 and MutationTaster tools were used.^{24–25}

RESULTS

To identify additional mutations that contribute to atypical clinical findings in patients with 22q11.2DS, we used whole exome sequencing to analyse the genome of four patients presenting with laryngo-tracheal-oesophageal and limb abnormalities (table 1, patients 1, 5–7). Homozygous 22q11.2-associated variants were identified in one of the four patients sequenced. In patient 1, we identified 539 variants that passed all the filters after whole exome

Table 1 A brief description of patients in this study

Patient	CNS	Cardiac	Craniofacial	Immune	Eye/Ear	Respiratory	GI	Dermatologic	GU	Other	E/S	SNAP29M
1	PMG Microcephaly	PDA	SMCP ASCF	CI requiring IVIG IgG and IgM deficiency	ONH Nystagmus and esotropia Hypertelorism SNHL	LTM OSA Chronic peribronchial thickening with lung hyperinflation	Dysphagia and G-tube Constipation FTT	Palmoplantar keratoderma Atopic dermatitis hypohidrosis	Cryptorchid Inguinal hernia Idiopathic nephrocalcinosis Hypercalciuria	–	E,S	c.388_389insGA
2	PMG Microcephaly	–	Preauricular tags	–	ONH Amblyopia and esotropia Relative hypertelorism SNHL	Tracheomalacia	Dysphagia and G-tube Constipation	Palmoplantar keratoderma Atopic dermatitis hypohidrosis	Hypospadias	Type I DM Scoliosis	S	c.28_32delCCGTT
3	Myelo Hydrocephalus Microcephaly	TOF with PA	CP ASCF	CI	Hypertelorism Astigmatism SNHL	Subglottic stenosis Tracheostomy Asthma	Dysphagia and G-tube GORD Constipation	–	Hydronephrosis Neurogenic bladder	Hypocalcaemia Clinodactyly	S	c.265G>A
4	–	ASD/PFO	BLCLP	Low T cells	Hypertelorism CDHL	–	–	–	–	Hypocalcaemia Hypermobility joints Camptodactyly	E	c.268C>T
5	Migraines	Valvar pulmonic stenosis	VPI	COM	–	Asthma	Dysphagia and G-tube GORD Constipation	–	–	–	E	–
6	Microcephaly Migraines Seizures	Syncopal event	Lambdoidal craniosynostosis Bifid uvula	CI Low IgM	Hypertelorism Lacrimal duct stenosis	Laryngeal web Sleep apnoea Asthma	GORD Abdominal migraines IBS	–	–	Short stature Scoliosis Hip dysplasia Adducted thumbs C-spine anomalies	E	–
7	Hypotonia	–	–	COM	–	OSA Asthma	Dysphagia and NG tube FTT	–	–	Short stature/low growth factors Camptodactyly Hypermobility joints	E	–
8	Heterotopias Seizures	BAV AI Heart block	ASCF NR	Haemolytic anaemia ITP COM	Hypertelorism	–	Dysphagia GORD Constipation	–	Hydrocele Inguinal hernia	Hypocalcaemia Postaxial 4 extremity polydactyly	S	–
9	PMG Hypotonia	TA	–	CI	–	–	Dysphagia G-tube GORD	–	–	Hypocalcaemia	S	–
10	Myelo Hydrocephalus Seizures	TOF with PA	NR	COM	CDHL	Recurrent aspiration	Dysphagia and G-tube	–	–	–	S	–

Continued

Table 1 Continued

Patient	CNS	Cardiac	Craniofacial	Immune	Eye/Ear	Respiratory	GI	Dermatologic	GU	Other	E/S	SNAP29M
11	PMG	VSD and PDA	NR	COM and URIs	Eustachian tube dysfunction	Asthma	Dysphagia and NG tube GERD Constipation	Mild atopic dermatitis Cutis aplasia on scalp	–	Short stature Chronic leg pain	S	–
12	PMG Hypotonia Seizures Central apnoea	RAA ARSA ASD	ASCF	FUO MRSA	CDHL	LTM OSA Asthma	Dysphagia and G-tube GORD Constipation FTT	–	Solitary kidney	Club foot Hypermobile joints	S	–
13	PMG Subarachnoid cyst Hemiplegia	–	ASCF Nasal regurgitation	Low T cells	–	Asthma	Dysphagia Constipation	–	–	Hypocalcaemia Thyroid disease Hypermobile joints Anaemia	S	–
14	PMG Seizures	ARSA	–	–	–	Subglottic stenosis Laryngeal web	Imperforate anus Dysphagia G-tube GORD	–	Hypoplastic kidney Vesicoureteral reflux Hypospadias and chordee Penile scrotal transposition Inguinal hernia	Hip dysplasia	S	–
15	PMG Hemiparesis	Vascular ring ASD	ASCF Retrognathia	–	Astigmatism CDHL	OSA	Dysphagia FTT	–	–	Growth hormone deficiency C-spine stenosis	S	–
16	Heterotopias Seizures	ASD/PFO PDA ARSA	SMCP	JRA	SNHL	–	–	–	Duplicated collecting system	Scoliosis	S	–
17	Heterotopias Seizures Hypotonia Migraines	RAA PFO	VPI	COM IgM deficiency Pancytopenia	–	OSA Sinusitis	Dysphagia GORD Constipation	–	–	Hypothyroid Obesity Cervical spine fusion	S	–

Note: all airway abnormalities were verified and found to be independent of vascular anomalies.

ASD, atrial septal defect; AI, aortic insufficiency; ARSA, aberrant right subclavian artery; ASCF, asymmetric crying facies; BAV, bicuspid aortic valve; BLCLP, bilateral cleft lip and palate; CP, cleft palate; CI, chronic infection; COM, chronic otitis media; CDHL, conductive hearing loss; C-spine, cervical spine; DM, diabetes mellitus; E/S, Exome (E) or Sanger (S) sequenced; FUO, fever of unknown origin; G-tube, gastrostomy tube; FTT, failure to thrive; GORD, gastro-oesophageal reflux disease; IVIG, intravenous immunoglobulins; ITP, idiopathic thrombocytopenia; IBS, irritable bowel syndrome; JRA, juvenile rheumatoid arthritis; LTM, laryngotracheomalacia; Myelo, myelomeningocele; MRSA, methicillin resistant *Staphylococcus aureus*; NR, nasal regurgitation; NG, nasogastric tube; OSA, obstructive sleep apnoea; ONH, optic nerve hypoplasia; PMG, polymicrogyria; PDA, patent ductus arteriosus; PA, pulmonary atresia; PFO, patent foramen ovale; RAA, right aortic arch; SMCP, submucosal cleft palate; SNHL, sensorineural hearing loss; SNAP29M, SNAP29 mutation present or absent; TOF, tetralogy of Fallot; TA, truncus arteriosus; URIs, upper respiratory infections; VSD, ventricular septal defect; VPI, velopharyngeal incompetence.

sequencing analysis, 14 of which were located on chromosome 22. Two variants out of the 14 were homozygous within the candidate region of 22q11.2: one frameshift insertion within the gene *SNAP29*, and one non-synonymous variant in the gene *CLTCL1*. Although a significant number of variants were identified in the remaining three patients (13 homozygous variants in the exome of patients 5; 17 in the exome of patient 6; and 45 in the exome of patient 7), none were in the 22q11.2 region (see supplementary table 1).

Patient 1 presented with a history of laryngotracheomalacia, a small patent ductus arteriosus, gastro-oesophageal reflux disease, failure to thrive and feeding difficulty requiring G-tube placement, chronic infection, polymicrogyria, and dysmorphic features including hypertelorism. In addition, he had: microcephaly, strabismus, optic nerve hypoplasia, bilateral sensorineural hearing loss, obstructive sleep apnoea, immunoglobulin G (IgG) and IgM deficiency, a unilateral inguinal hernia and undescended testis. More recently, he was noted to have palmoplantar keratoderma and ichthyosis, (figure 1: 1A–F). The homozygous frameshift insertion within *SNAP29*, c.388_389insGA (p.T130fs), has not previously been seen in dbSNP, 1000 Genomes Project or EVS, and was subsequently confirmed by Sanger sequencing (figure 2A–C). Sanger sequencing of parental blood DNA revealed a heterozygous insertion in the father at the same position (figure 2C), suggesting that the proband was hemizygous for the 22q11.2 chromosome, as determined by fluorescence *in situ* hybridisation (FISH), and inherited a non-functional *SNAP29* gene from the father and by inference a *de novo* deletion on the 22q11.2 chromosome inherited from his mother. Truncating mutations in *SNAP29* are associated with CEDNIK syndrome, an autosomal recessive condition characterised by cerebral dysgenesis, neuropathy, ichthyosis, and keratoderma.^{14 15} The frameshift mutation identified in *SNAP29* is predicted to result in a truncated protein with 129 amino acids of the *SNAP29* protein, and insertion of 17 novel amino acids before a premature stop (figure 2C).

In light of this finding, we concluded that the *SNAP29* mutation, in conjunction with the 22q11.2 deletion, unmasked the symptoms of CEDNIK syndrome in this patient, including diffuse polymicrogyria (similar to the 2011 Fuchs-Telem *et al* report¹⁴), an ichthyosiform dermatitis with secondary hypohidrosis, atopic dermatitis, and palmoplantar keratoderma. To determine if other patients with 22q11.2DS and similar atypical findings might also have mutations in this gene, we screened the coding exons 5' and 3' splice sites of *SNAP29* in 12 additional patients by Sanger sequencing. Thereafter, we identified a 5 bp deletion in exon 1 (c.28_32delCCGTT, p.P10fs) in patient 2 (figure 3B). Atypical findings in patient 2 included features consistent with CEDNIK syndrome, as well as with patient 1: microcephaly, polymicrogyria (similar to the structural differences reported by Sprecher *et al*¹³), optic nerve hypoplasia, hypertelorism, sensorineural hearing loss, palmoplantar keratoderma, and ichthyosis; additional findings also included a preauricular tag, amblyopia, hypospadias, and type 1 diabetes (figure 1: 2A–F and supplementary data). Sanger sequencing of DNA from the parents of this patient revealed the c.28_32delCCGTT mutation in the mother's DNA (figure 3B). This deletion is predicted to result in a frameshift insertion of 42 novel amino acids before a premature stop in the *SNAP29* protein (figure 3B). In addition, these studies also revealed a heterozygous A to G transition (c.317A>G) that would generate a missense (p.Q106R) mutation in the father (see supplementary figure 1). Parent of origin studies, using microsatellite markers, revealed that the proband shares the D22S264 allele with his mother, indicating the 22q11.2 deletion was paternal in origin, consistent with the *SNAP29* findings.

In a third patient (patient 3) with subglottic stenosis post-tracheostomy, cleft palate, sacral myelomeningocele, bilateral sensorineural hearing loss, tetralogy of Fallot with pulmonary atresia, hypocalcaemia, severe gastro-oesophageal reflux disease with feeding difficulty necessitating G-tube placement, asymmetric crying facies, hypocalcaemia, microcephaly, hypertelorism, clinodactyly, and hydronephrosis (figure 1: 3A,B), we identified a homozygous mutation (c.265G>A) which resulted in a missense (p.E89K) mutation in a conserved glutamic acid. This mutation was not predicted to be damaging after PolyPhen-2 analysis with a score of 0.021. However, this specific mutation was predicted to be damaging by MutationTaster (p=0.94) and has been reported to be associated with genitourinary abnormalities in a previous study by Zhang *et al*.¹⁵

A fourth patient (patient 4) presented with a bilateral cleft lip and palate and pseudoexotropia secondary to hypertelorism as the only atypical features. Additional findings included an atrial septal defect, mild to moderate conductive hearing loss, hypocalcaemia, and hyperextensible joints (figure 1: 4A,B). Targeted exome sequencing identified and Sanger sequencing confirmed a second point mutation in the coiled-coil domain which resulted in a missense (c.268C>T; p.R90C) mutation. This amino acid is highly conserved in all mammals but one, rodent (see supplementary figure 2), and is predicted to be damaging by MutationTaster (p=0.99) and possibly damaging by PolyPhen2, with a score of 0.890.

DISCUSSION

Recurrent structural rearrangements in the human genome are responsible for a large number of human disorders associated with congenital abnormalities. Human deletion syndromes occur at a combined frequency of 1 in 1000 live births. Some examples include Prader-Willi,²⁶ Phelan-McDermid,²⁷ Williams-Bueren²⁸ and 22q11.2DS.^{3 11 29} In many of these disorders, the recurrent deletion regions are defined within a certain range, the phenotypic defects constitute continuous spectra, there are a large number of genes contained within the candidate intervals, and it is unclear which gene(s) are primarily responsible for the observed phenotypic features.³⁰ Moreover, the phenotypic spectra are often broad, and many patients present with atypical or extreme phenotypes. Previously, identifying the breakpoints of the deletions and the genes contained within the structural rearrangements constituted the limit of resolution in determining the extent of genetic involvement. This resulted in numerous unanswered questions and speculation regarding the involvement of modifier genes and epigenetic effects as possible explanations for this phenotypic variability. However, as has been recently demonstrated in the case of Van den Ende Gupta syndrome,^{12 31} large deletions may unmask the deleterious effect of mutations on the homologous allele, resulting in loss of function.

Likewise, in 1995, we described the association of Bernard-Soulier syndrome,³² an autosomal recessive condition involving thrombocytopenia and increased megakaryocytes, in a patient with 22q11.2DS, who was noted to have notably decreased ristocetin-induced platelet aggregation and GP1bB on the platelet surface by flow cytometry. Later, this was explained by a secondary mutation in the promoter region of the *GP1BB* gene on the remaining 22q11.2 allele that altered a GATA binding consensus site.^{32 33} This mutation, in combination with the 22q11.2 deletion as is the case with the *SNAP29* abnormalities observed in patients 1 and 2 and their features of CEDNIK syndrome, essentially unmasked an autosomal recessive condition. Thus, our ability to identify such events will have a great impact on understanding the causative genes underlying human deletion syndromes, as well as

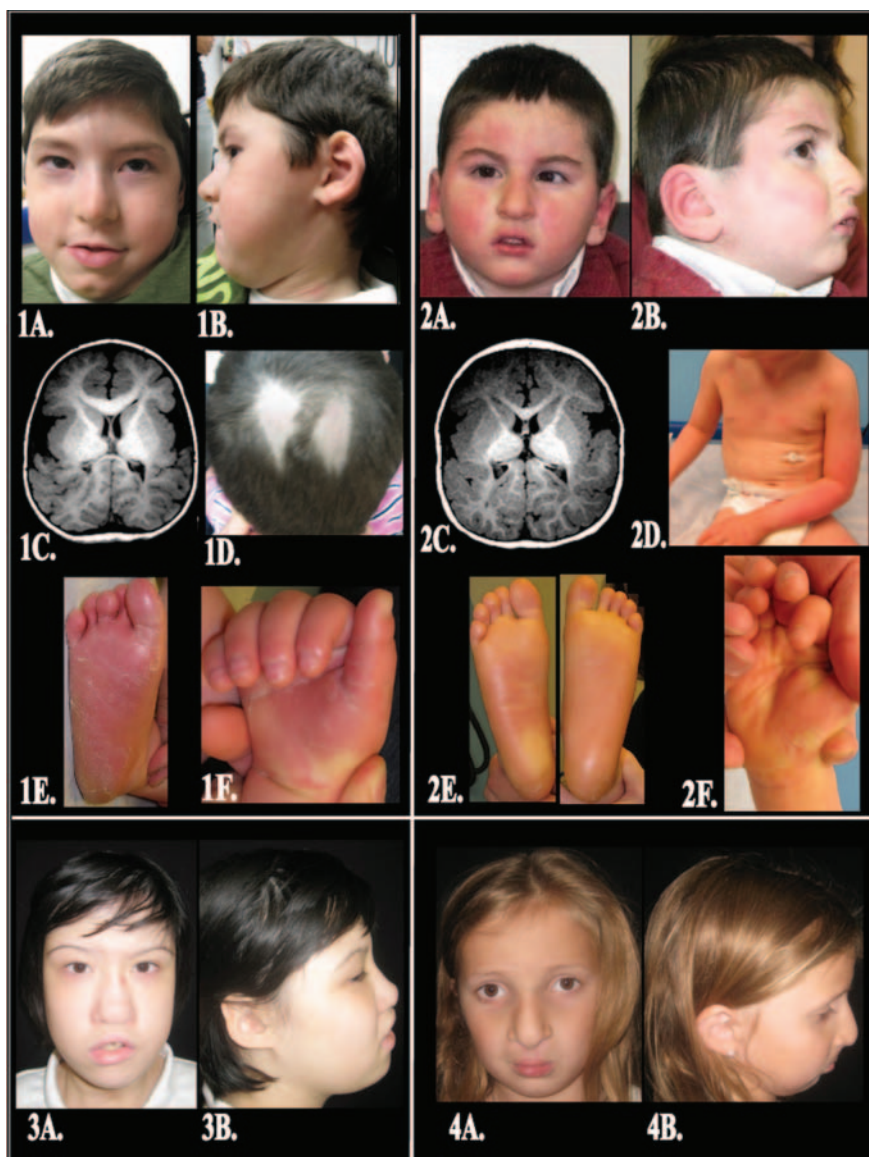
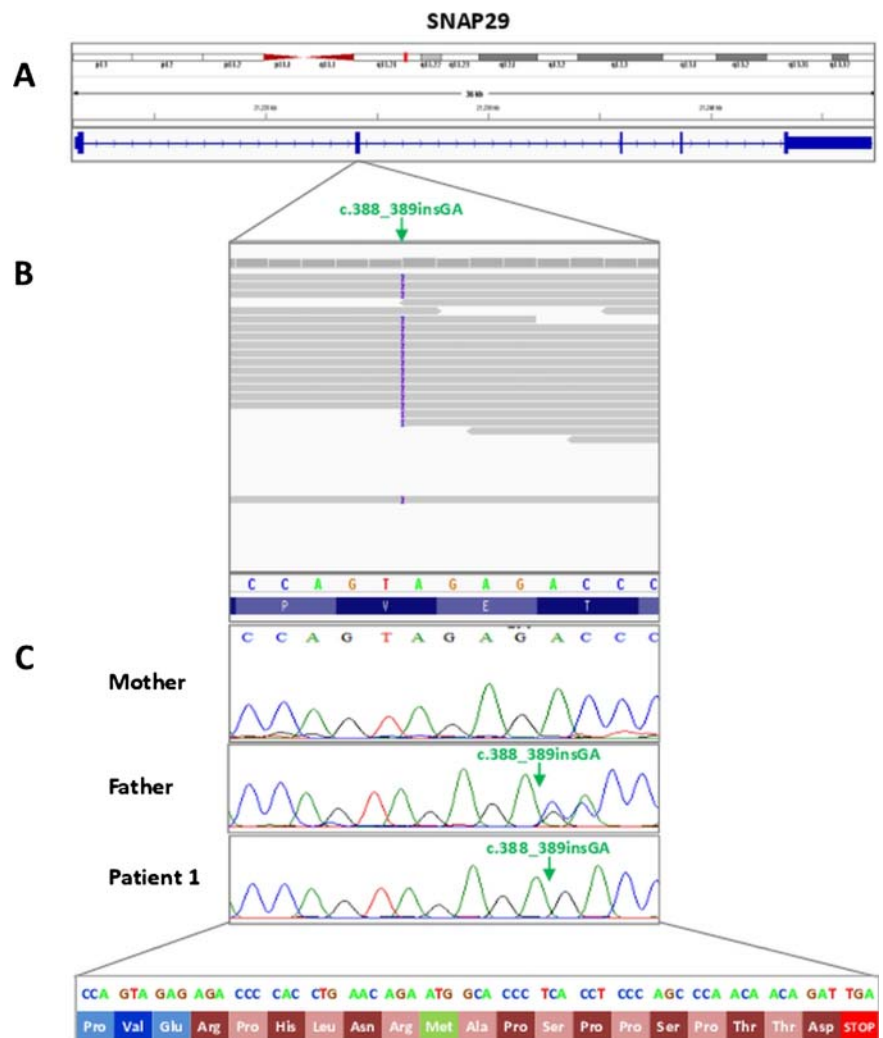


Figure 1 Patient description. (1A) Patient 1—Anteroposterior (AP) photo demonstrating upslanting palpebral fissures with hooded eyelids and hypertelorism; malar flatness; a bulbous nasal tip with hypoplastic alae nasi; and a mandibular cleft. (1B) Lateral photo demonstrating auricular anomalies including thick crumpled helices with attached lobes. (1C) A 2 mm thick T1 axial image of the brain reveals pronounced under-opercularisation with very wide Sylvian fissures and bilateral thick finely nodular cortex, consistent with polymicrogyria, throughout the brain but being particularly thick in the insular regions. There is abnormal brain morphology with some gyri being small and some wide. Also, there is diminished white matter and there are multiple anomalous deep fissures in both parieto-occipital regions that extend near to and deform the atria of the lateral ventricles, particularly on the right. The *genu* of the corpus callosum is unusually thick and the splenium is very thin. (1D) A focal area of frictional alopecia on the vertex. (1E) Right foot displays a diffuse keratoderma with erythema and thick desquamating hyperkeratotic sheets localised to the plantar surface of the foot and toes. (1F) Right hand shows diffuse keratoderma with erythema and overlying desquamation on the palmar surface, notably sparing the dorsal aspects of the fingers and nails. Accentuated skin markings can be appreciated on the volar wrist. (2A) Patient 2—AP photo demonstrating mild upslanting palpebral fissures on the left and a bulbous nasal tip with hypoplastic alae nasi. (2B) Lateral photo demonstrating normally formed ears with attached lobes; a nasal dimple; and micrognathia. (2C) A 0.9 mm thick axial T1 weighted image at the level of the insulae shows pronounced under-opercularisation with open Sylvian fissures and bilateral extensive thick nodular cortex representing polymicrogyria in all lobes of the brain, but most prominent in the insulae and the brain posterior to them. There is diminished white matter and abnormal gyral pattern throughout the brain. Also noted are anomalous deep fissures lined by the thick nodular cortex extending near to the ventricular atria and deforming them, more on the right. The *genu* of the corpus callosum is seen and the splenium, being very thin, is not included on this section. (2D) Anterior trunk showing diffuse xerosis and a fine, powdery, ichthyosiform scale which is accentuated on the arms. (2E) Bilateral plantar feet reveal a diffuse, glossy, yellowish keratoderma (thickening of the skin) with decreased skin markings and focal areas of desquamation on the heels. (2F) Right hand shows a diffuse, yellow-orange keratoderma with focal areas of desquamation on the palms and fingertips. (3A) Patient 3—AP photo demonstrating upslanting palpebral fissures with hypertelorism; malar flatness; a bulbous nasal tip with hypoplastic alae nasi, a blunted nasal tip with a dimple; asymmetric crying facies; and a healed tracheostomy scar. (3B) Lateral photo demonstrating auricular anomalies including crumpled helices with attached lobes and micrognathia. (4A) Patient 4—AP photo demonstrating hypertelorism; malar flatness; a bulbous nasal tip with hypoplastic alae nasi; and a repaired bilateral cleft lip and palate. (4B) Lateral photo demonstrating attached ear lobes and micrognathia.

Figure 2 Identification of a homozygous 2 bp frameshift insertion within the gene *SNAP29* by exome and Sanger sequencing. (A) The *SNAP29* gene is located on the long arm of chromosome 22 at position 22q11.2. It is 32 kb in size and is composed of five exons. (B) The grey horizontal arrows depict the 100 bp paired-end reads aligned to the positive strand of human genome (hg19) and cover the 2 bp 'GA' homozygous insertion at position 388_389 in exon 2. Of 19 unique reads mapped at the genomic position chr22:21224770, 17 reads displayed the 2 bp homozygous insertion. Note that the BWA (Burrows-Wheeler Aligner) placed the insertion at position c.383_384, whereas the correct HGVS (Human Genome Variation Society) notation is c.387_388dup. (C) Chromatograms show the result of Sanger sequencing in patient 1 and his parents. Patient 1 carries a homozygous 2 bp insertion resulting in a frameshift and a premature stop codon 17 amino acids downstream (p. T130fs). The father is a heterozygous carrier for the 2 bp insertion at the same position. The position of the insertion is indicated by the green arrow on the chromatograms of patient 1 and his father. In the lower part of figure, the frameshift DNA sequence and the respective translation into protein are given.



understanding the function of previously uncharacterised genes which contribute to the unusual and extreme phenotypes observed in a subset of patients with 22q11.2DS.

Mutations in *SNAP29* are associated with CEDNIK syndrome and genitourinary malformations, and SNPs in the 5' region have been associated with schizophrenia.¹⁶ Four different mutations were previously reported in *SNAP29*: a homozygous c.486insA insertion which results in production of a truncated protein (p. S163fs);¹⁴ a 1 bp deletion (c.220delG) which was predicted to also result in a truncated protein (p.V75fs) and was shown to result in loss of the protein by Western blot analysis;¹³ and two heterozygous mutations, c.487A>G and c.265G>A of unknown status.¹⁵ In this study, we report three novel mutations (c.388_389insGA, c.28_32delCCGTT, and c.268C>T) in *SNAP29* that contribute to atypical findings in 22q11.2 patients as well as one previously reported mutation (c.265G>A) (figure 3A).

SNAP29 is a ubiquitous member of the t-SNARE proteins that forms a 4-helices bundle with *SNAP23*, *SNAP25*, and *SNAP47* during vesicle docking at the plasma membrane.³⁴ *SNAP29* has also been shown to complex with several other proteins involved in vesicle secretion such as clathrin, alpha adaptin, APAP2, EHD1, and RAB3A.³⁴⁻³⁵ Loss of function mutations in this gene are associated with delayed maturation and secretion of lamellar granules that are involved in the transport of lipids and proteases to the epidermis.³⁶ More recently, *SNAP29* mutant cells were also shown

to have abnormal endocytosis of β 1-integrin, suggesting that abnormal cell migration may be contributing to the polymicrogyria phenotype found in patients.¹⁹ Intriguingly, four of the seven mutations identified in this gene are before or in the coiled-coil domain of *SNAP29* (figure 3A). This is a *SNAP29* specific coiled-coil domain that is not shared by other related t-SNARE members. Since these domains are normally used for protein-protein interaction it is intriguing to postulate that mutations in this domain interfere with the efficiency of the interaction of *SNAP29* with other SNARE proteins. This interference may result in abnormal interaction with specific associated SNAREs in a tissue dependent manner, thus explaining the variability in phenotypes found. In addition, although the E89K mutation is predicted to not be damaging by PolyPhen-2, this mutation is of an amino acid that is conserved in all primates and placental mammals. We postulate that this mutation is damaging as predicted by MutationTaster and thus likely to perturb *SNAP29* function.

Two of the four patients described herein (patients 1 and 2) share a number of common clinical features: (1) an early-onset ichthyosiform presentation; (2) eventual development of palmo-plantar keratoderma between 1–2 years of age that is accentuated at sites predisposed to pressure or friction; (3) features consistent with mild to moderate atopic dermatitis; and (4) hypohidrosis with associated heat intolerance (but without other features associated with hypohidrotic ectodermal

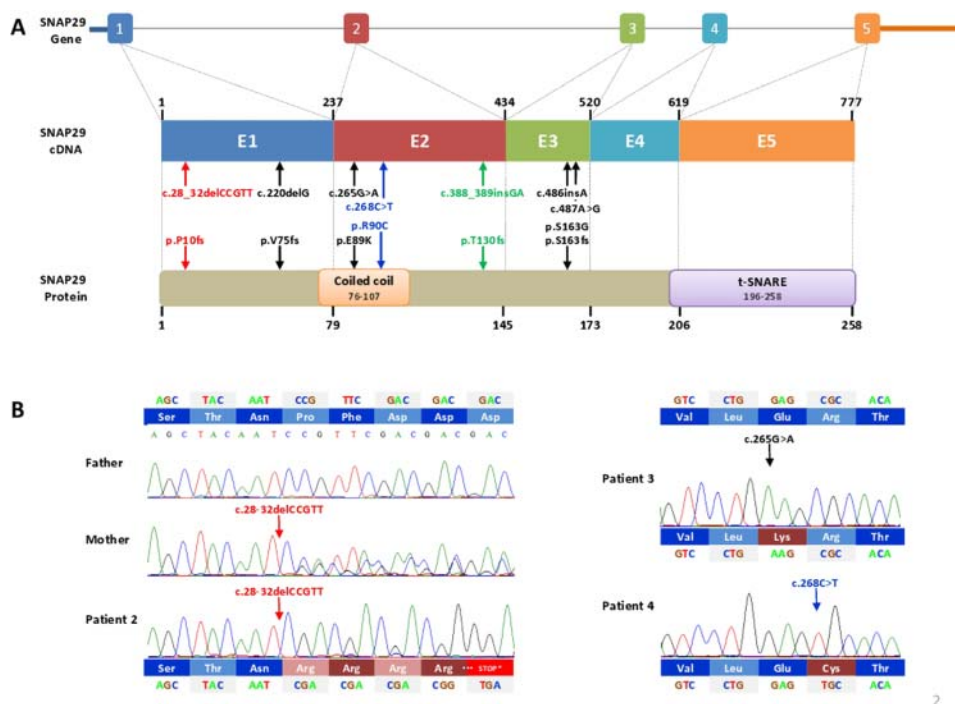


Figure 3 Schematic representation of *SNAP29* gene, cDNA and protein structure. (A) Upper panel is genomic structure of the *SNAP29* gene, comprises five exons (numbered 1–5) and 5' and 3' untranslated regions (UTRs). Introns are represented by a straight grey line. The structure of 777 bp *SNAP29* cDNA is shown in the middle panel. Numbers above the cDNA diagram show the exons (named E1–E5) boundary nucleotide. The vertical dashed grey lines align the location of each exon to the regions of *SNAP29* protein that each exon encodes. Numbers below the protein diagram show the contribution of each exon to the amino acid sequence. The *SNAP29* protein has a length of 258 amino acid residues and is composed of two domains: coiled-coil (orange box) and t-SNARE (purple box). The position of seven mutations identified in *SNAP29* is shown by arrows on cDNA and protein levels. The three mutations identified in this study are coloured in green for insertion and in red for deletion. Black arrows show the position of four previously reported *SNAP29* mutations, associated with cerebral dysgenesis, neuropathy, ichthyosis and keratoderma syndrome. (B) Sanger sequencing confirmed all of the mutations identified in this study. Patient 2 and his mother are homozygous for a 5 bp deletion (c.28_32delCCGTT) resulting in a frameshift (p.P10fs) and a premature stop codon 42 amino acids downstream. Patient 3 and 4 carry a homozygous sequence variant resulting in glutamic acid to lysine (p.E89K) and arginine to cysteine (p.R90C) changes, respectively.

dysplasia). The ichthyosiform skin changes and palmoplantar keratoderma are likely related to deficiency of the SNARE protein which plays a central role in Golgi function and synaptic vesicle recycling. The combination of the 22q11.2 deletion with a mutation in the remaining *SNAP29* allele encoding the SNARE protein presumably leads to significantly decreased expression of SNARE. As a result, the normal release of lipids and proteases from lamellar granules into the extracellular spaces of the cornified cell layer is likely impaired, resulting in defective desquamation and barrier formation. Defective barrier function may then lead to epicutaneous sensitisation and, secondarily, features of atopic dermatitis. Although the specific mechanism behind the hypohidrosis seen in both patients and the enamel hypoplasia in one of the two is unknown, these suggest that patients with these genetic changes may share features overlapping those of ectodermal dysplasia. In addition they both have polymicrogyria, hypertelorism/relative hypertelorism, bilateral sensorineural hearing loss, and significant feeding, swallowing and airway difficulties.

Patient 3 has several significant atypical findings including subglottic stenosis, bilateral sensorineural hearing loss, cleft palate, hypertelorism, a sacral myelomeningocele, and clinodactyly, in addition to classically associated features of 22q11.2DS such as tetralogy of Fallot with pulmonary atresia, asymmetric crying facies, and hypocalcaemia. This is notable because in 1984, Kousseff³⁷ reported the association of sacral meningocele, conotruncal cardiac anomalies, unilateral renal agenesis, and

dysmorphic features in three siblings and suggested autosomal recessive inheritance. Toriello *et al*³⁸ reported a similar isolated case in 1985 and coined the term Kousseff syndrome. In 2002, Forrester *et al*³⁹ restudied the family reported by Kousseff and identified a 22q11.2 deletion in the proband and his father, thereby attributing the sacral myelomeningoceles to the 22q11.2DS. Thereafter, the existence of Kousseff syndrome as a distinct entity was called into question. However, in 2004, Maclean *et al*⁴⁰ subsequently reported two patients with Kousseff syndrome, one with a 22q11.2 deletion and the other without a deletion, both of which were performed by FISH, and concluded that Kousseff syndrome is causally heterogeneous. Perhaps the features in our patient 3 also represent the unmasking of an autosomal recessive condition, Kousseff, in the same manner as CEDNIK, with a deletion of 22q11.2 on one chromosome and a mutation in *SNAP29* on the other. Thus, we postulate that deletion of 22q11.2 on one chromosome associated with mutation(s) in *SNAP29* may also explain the presence of myelomeningoceles, a typically uncommon associated feature in 22q11.2DS, in a subset of Kousseff³⁷ patients.

Patient 4, presenting with a bilateral cleft lip and palate and hypertelorism also warrants further discussion as both features are reported in association with the 22q11.2 deletion, but infrequently. However it is notable that the combination of cleft lip and palate, hypertelorism, laryngotracheoesophageal anomalies and hypospadias has been described in individuals with the heterogeneous Opitz G/BBB syndrome,⁴¹ where an

X-linked form – due to mutations in *MID1* and an autosomal dominant form with linkage to 22q11.2, and an association with the 22q11.2 deletion syndrome have all been reported previously.^{42–46} These individuals typically present with laryngo-tracheal-oesophageal abnormalities, as seen in three of our four patients reported here with *SNAP29* mutations in combination with a 22q11.2 deletion, as well as: cleft lip and palate in one of four; hypertelorism in all four; severe swallowing difficulties/oesophageal dysmotility in three of four; and genitourinary abnormalities such as hypospadias in one of the two males and cryptorchidism in the other. Thus, *SNAP29* mutations in association with a 22q11.2 deletion may also elicit a set of symptoms previously described in association with Opitz G/BBB syndrome, and perhaps unmask an autosomal recessive phenocopy. This might also explain the child with ‘apparent G syndrome’ reported by Williams and Frias,⁴⁷ as well as isolated case reports such as the female described by Neri *et al.*⁴⁸ Furthermore, although *SNAP29* is known to be associated with schizophrenia we could not assess this condition in our patients. In fact, three of our four patients are below the age of onset, and the fourth patient, a young teen, is likely too impaired cognitively to assess for this phenotype.

In addition, in one patient (patient 1) we also identified a homozygous mutation in the *CLTCL1* gene that is predicted to be damaging. This variant in *CLTCL1* has previously been seen in the dbSNP, 1000 Genomes and three unrelated exome samples sequenced at our centre. *CLTCL1* encodes clathrin heavy chain-like 1, a major component of coated vesicles.⁴⁹ *CLTCL1* is not found in rodents and is predicted to function species-specifically in Glut4 transport in muscle cells, although it may also have functions in other tissues. Intriguingly, although the majority of abnormalities found in patient 1 can be explained by the mutation identified in *SNAP29*, this patient also had an unusual B cell immunity that may more likely be the result of the mutation in *CLTCL1*. Sequencing of additional patients will allow us to determine if the mutation in *CLTCL1* is associated with B cell abnormalities. However, since an atypical deletion that includes *SNAP29*, *LZTR1* and *P2RX1* was recently found associated with immune deficiency, it remains possible that the mutations that we identified are responsible for this phenotype.⁵⁰

In conclusion, we have found that mutations in a single gene, in unrelated patients, contribute to the phenotype of patients with a microdeletion syndrome, implicating *SNAP29* as a major modifier of variable expressivity in 22q11.2DS patients. Our work confirms that the phenotypic variability observed in patients with 22q11.2DS may be due to additional mutations on the non-deleted chromosome, which in some instances unmask a previously described autosomal recessive condition such as the CEDNIK and potentially Kousseff syndromes, and in other cases simply contributes to the presence of atypical findings. In fact, the majority of our patients did not have mutations in *SNAP29*, suggesting that non-coding mutations in *SNAP29*, and mutations in additional genes in the 22q11.2 region or on other chromosomes, are contributing to atypical findings in those patients, as previously suggested by Stalmans *et al.*⁵¹ Future work is focused on identifying these additional mutations in the hope of stratifying patients for optimal treatment and genetic counselling.

Author affiliations

¹Division of Human Genetics, The Children’s Hospital of Philadelphia, University of Pennsylvania Perelman School of Medicine, Philadelphia, Pennsylvania, USA

²Department of Human Genetics, McGill University, Montreal, Quebec, Canada

³Department of Medical Genetics, Institute of Mother and Child, Warsaw, Poland

⁴Department of Human Genetics, Emory University School of Medicine, Atlanta, USA

⁵Departments of Neurology and Pediatrics, The Children’s Hospital of Philadelphia, University of Pennsylvania Perelman School of Medicine, Philadelphia, Pennsylvania, USA

⁶Division of Dermatology, The Children’s Hospital of Philadelphia, University of Pennsylvania Perelman School of Medicine, Philadelphia, Pennsylvania, USA

⁷Division of Neuroradiology, The Children’s Hospital of Philadelphia, University of Pennsylvania Perelman School of Medicine, Philadelphia, Pennsylvania, USA

⁸Division of Allergy Immunology, The Children’s Hospital of Philadelphia, University of Pennsylvania Perelman School of Medicine, Philadelphia, Pennsylvania, USA

⁹Department of Pediatrics, University of Pennsylvania Perelman School of Medicine, Philadelphia, Pennsylvania, USA

¹⁰Center for Human Genetics, Catholic University Leuven, University Hospital Gasthuisberg, Leuven, Belgium

¹¹Department of Pediatrics, McGill University, Montreal Children’s Hospital, Montreal, Quebec, Canada

Acknowledgements We would like to acknowledge Patrick McMahon MD for his help in assessing and documenting the dermatologic findings in patients 1 and 2; Elizabeth Bratton for assistance with clinical data collection in the ‘22q and You’ Center; Piotr Jurgielewicz for assistance with gathering reference materials; Colleen Franconi for technical assistance in the laboratory of Dr Beverly S Emanuel, all at the Children’s Hospital of Philadelphia. We also wish to acknowledge the contribution of the high-throughput sequencing platform of the McGill University and Genome Québec Innovation Centre (Montréal, Canada) and Dr Jacek Majewski for his help in analysing the exome data.

Funding This work was supported by a grant from the Canadian Institutes of Health Research (#MOP-102666) to LJM, and NIH support (HL84410, MH87636 and HD070454) to BSE, DMM-M and EHZ. BAN is supported by KOLUMB fellowship from the Foundation for Polish Science. The Charles EH Upham Chair to BSE provided funds for this research at the Children’s Hospital of Philadelphia. JV was supported by the Jerome Lejeune Foundation and LJM is a member of the Research Institute of the McGill University Health Centre, which is supported in part by the FRSQ.

Contributors DMM-M liaised with the collaborative investigators, selected and recruited subjects for participation in the research study, oversaw sample and data collection, participated in scientific discussions surrounding the laboratory results, wrote the clinical sections of the paper including table 1, figure 1, and the respective figure legends, and drafted and revised the paper. SF performed exome sequencing data analysis, designed the primers, assembled the figures on the molecular findings, drafted and revised the paper. TR performed Sanger sequencing analysis of 14 patients, reviewed the draft and revised the paper. BAN performed chromosome 22q11.2 exome capture analysis, reviewed the draft and revised the paper. JS performed chromosome 22q11.2 exome capture analysis, reviewed the draft and revised the paper. AB arranged for sample collection and distribution, monitored data collection, obtained informed study consent, obtained parental photo consent, obtained photographs, drafted table 1 and revised the drafted paper. EM performed Sanger sequence confirmation, reviewed the draft and revised the paper. DRL participated in scientific discussions surrounding the laboratory results and clinical findings, reviewed the neurologic data on patients 1, 2 and 3, wrote the discussion on the associated neurologic phenotype, participated in scientific discussions surrounding the laboratory results, and reviewed the drafted and revised paper. AY participated in scientific discussions surrounding the laboratory results and clinical findings, reviewed the dermatologic sections of the paper, submitted dermatologic photographs on patients 1 and 2, wrote the clinical descriptions and discussion on the dermatologic section and figure 1, and reviewed the drafted and revised paper. LB reviewed the neuroimaging data on patients 1, 2 and 3, selected the brain images for figure 1, wrote the description for the MRI findings, and reviewed the drafted and revised paper. KES participated in scientific discussions surrounding the laboratory results and clinical findings, reviewed the immunologic data on all patients, wrote the postulate for the immune findings in patient 2, and reviewed the draft and revised paper. STW supervised the exome 22q11.2 capture experiments at Emory University. BSE participated in the planning and execution of the study design, participated in scientific discussions surrounding molecular findings, and reviewed the draft and revised paper. JRV supervised the exome 22q11.2 capture experiments performed by BAN, participated in discussion of the molecular findings and reviewed the draft and revised paper. EHZ initiated the collaborative project, participated in the planning and execution of the study design including subject selection, participated in scientific discussions surrounding the laboratory results and clinical findings, and reviewed the draft and revised paper. LAJ-M designed the study, liaised with the collaborative investigators, supervised the exome and Sanger sequence data collection and analysis at McGill University, participated in scientific discussions surrounding the molecular results, and drafted and revised the paper.

REFERENCES

- 1 Lindsay EA. Chromosomal microdeletions: dissecting del22q11 syndrome. *Nat Rev Genet* 2001;2:858–68.
- 2 Devriendt K, Fryns JP, Mortier G, van Thienen MN, Keymolen K. The annual incidence of DiGeorge/velocardiofacial syndrome. *J Med Genet* 1998;35:789–90.
- 3 Shaikh TH, Kurahashi H, Saïta SC, O'Hare AM, Hu P, Roe BA, Driscoll DA, McDonald-McGinn DM, Zackai EH, Budarf ML, Emanuel BS. Chromosome 22-specific low copy repeats and the 22q11.2 deletion syndrome: genomic organization and deletion endpoint analysis. *Hum Mol Genet* 2000;9:489–501.
- 4 McDonald-McGinn DM, Kirschner R, Goldmuntz E, Sullivan K, Eicher P, Gerdes M, Moss E, Solot C, Wang P, Jacobs I, Handler S, Knightly C, Heher K, Wilson M, Ming JE, Grace K, Driscoll D, Pasquariello P, Randall P, Larossa D, Emanuel BS, Zackai EH. The Philadelphia story: the 22q11.2 deletion: report on 250 patients. *Genet Couns* 1999;10:11–24.
- 5 McDonald-McGinn DM, Tonnesen MK, Laufer-Cahana A, Finucane B, Driscoll DA, Emanuel BS, Zackai EH. Phenotype of the 22q11.2 deletion in individuals identified through an affected relative: cast a wide FISHing net! *Genet Med* 2001;3:23–9.
- 6 McDonald-McGinn DM, Zackai EH. Genetic counseling for the 22q11.2 deletion. *Dev Disabil Res Rev* 2008;14:69–74.
- 7 Bassett AS, McDonald-McGinn DM, Devriendt K, Digilio MC, Goldenberg P, Habel A, Marino B, Oskarsdottir S, Philip N, Sullivan K, Swillen A, Vorstman J. Practical guidelines for managing patients with 22q11.2 deletion syndrome. *J Pediatr* 2011;159:332–9 e1.
- 8 Philip N, Bassett A. Cognitive, behavioural and psychiatric phenotype in 22q11.2 deletion syndrome. *Behav Genet* 2011;41:403–12.
- 9 Baldini A. DiGeorge syndrome: an update. *Curr Opin Cardiol* 2004;19:201–4.
- 10 Guris DL, Fantes J, Tara D, Druker BJ, Imamoto A. Mice lacking the homologue of the human 22q11.2 gene CRKL phenocopy neurocristopathies of DiGeorge syndrome. *Nat Genet* 2001;27:293–8.
- 11 Baldini A. The 22q11.2 deletion syndrome: a gene dosage perspective. *ScientificWorldJournal* 2006;6:1881–7.
- 12 Anastasio N, Ben-Omran T, Teebi A, Ha KC, Lalonde E, Ali R, Almureikhi M, Der Kaloustian VM, Liu J, Rosenblatt DS, Majewski J, Jerome-Majewska LA. Mutations in SCARF2 are responsible for Van Den Ende-Gupta syndrome. *Am J Hum Genet* 2010;87:553–9.
- 13 Sprecher E, Ishida-Yamamoto A, Mizrahi-Koren M, Rapaport D, Goldsher D, Indelman M, Topaz O, Chefetz I, Keren H, O'Brien TJ, Bercovich D, Shalev S, Geiger D, Bergman R, Horowitz M, Mandel H. A mutation in SNAP29, coding for a SNARE protein involved in intracellular trafficking, causes a novel neurocutaneous syndrome characterized by cerebral dysgenesis, neuropathy, ichthyosis, and palmoplantar keratoderma. *Am J Hum Genet* 2005;77:242–51.
- 14 Fuchs-Telem D, Stewart H, Rapaport D, Nousbeck J, Gat A, Gini M, Lugassy Y, Emmert S, Eckl K, Hennies HC, Sarig O, Goldsher D, Meilik B, Ishida-Yamamoto A, Horowitz M, Sprecher E. CEDNIK syndrome results from loss-of-function mutations in SNAP29. *Brit J Dermatol* 2011;164:610–16.
- 15 Zhang JS, Fu Y, Zhao YH, Li F, Qian AL, Wu B, Li-Ling J. (Genetic analysis of genitourinary malformations). *Chin J Med Genet* 2009;26:134–8.
- 16 Saito T, Guan F, Papolos DF, Rajouria N, Fann CSJ, Lachman HM. Polymorphism in SNAP29 gene promoter region associated with schizophrenia. *Mol Psychiatr* 2001;6:193–201.
- 17 Newman AP, Shim J, Ferronovick S. Bet1, Bos1, and Sec22 are members of a group of interacting yeast genes required for transport from the endoplasmic-reticulum to the golgi-complex. *Mol Cell Biol* 1990;10:3405–14.
- 18 Schardt A, Brinkmann BG, Mitkovski M, Sereda MW, Werner HB, Nave KA. The SNARE protein SNAP-29 interacts with the GTPase Rab3A: implications for membrane trafficking in myelinating glia. *J Neurosci Res* 2009;87:3465–79.
- 19 Proux-Gillardeaux V, Galli T. Tetanus neurotoxin-mediated cleavage of cellubrevin impairs epithelial cell migration and integrin-dependent cell adhesion. *M S-Med Sci* 2005;21:789–90.
- 20 Schwartzentruber J, Korshunov A, Liu XY, Jones DTW, Pfaff E, Jacob K, Sturm D, Fontebasso AM, Quang DAK, Tonjes M, Hovestadt V, Albrecht S, Kool M, Nantel A, Konermann C, Lindroth A, Jager N, Rausch T, Ryzhova M, Korbel JO, Hielscher T, Hauser P, Garami M, Klekner A, Bogner L, Ebinger M, Schuhmann MU, Scheurlen W, Pekrun A, Fruhwald MC, Roggendorf W, Kramm C, Durken M, Atkinson J, Lepage P, Montpetit A, Zakrzewska M, Zakrzewski K, Liberski PP, Dong ZF, Siegel P, Kulozik AE, Zapotka M, Guha A, Malkin D, Felsberg J, Reifemberger G, von Deimling A, Ichimura K, Collins VP, Witt H, Milde T, Witt O, Zhang C, Castelo-Branco P, Lichter P, Faury D, Tabori U, Plass C, Majewski J, Pfister SM, Jabado N. Driver mutations in histone H3.3 and chromatin remodelling genes in paediatric glioblastoma (vol 482, pg 226, 2012). *Nature* 2012;484:130.
- 21 Li H, Durbin R. Fast and accurate short read alignment with Burrows-Wheeler transform. *Bioinformatics* 2009;25:1754–60.
- 22 Li H, Handsaker B, Wysoker A, Fennell T, Ruan J, Homer N, Marth G, Abecasis G, Durbin R. The Sequence Alignment/Map format and SAMtools. *Bioinformatics* 2009;25:2078–9.
- 23 Wang K, Li M, Hakonarson H. ANNOVAR: functional annotation of genetic variants from high-throughput sequencing data. *Nucleic Acids Res* 2010;38:e164.
- 24 Adzhubei IA, Schmidt S, Peshkin L, Ramensky VE, Gerasimova A, Bork P, Kondrashov AS, Sunyaev SR. A method and server for predicting damaging missense mutations. *Nat Methods* 2010;7:248–9.
- 25 Schwarz JM, Rodelsperger C, Schuelke M, Seelow D. MutationTaster evaluates disease-causing potential of sequence alterations. *Nat Methods* 2010;7:575–6.
- 26 Cassidy SB, Schwartz S, Miller JL, Driscoll DJ. Prader-Willi syndrome. *Genet Med* 2012;14:10–26.
- 27 Phelan K, McDermid HE. The 22q13.3 deletion syndrome (Phelan-McDermid Syndrome). *Mol Syndromol* 2012;2:186–201.
- 28 Dutra RL, Pieri Pde C, Teixeira AC, Honjo RS, Bertola DR, Kim CA. Detection of deletions at 7q11.23 in Williams-Beuren syndrome by polymorphic markers. *Clinics (Sao Paulo)* 2011;66:959–64.
- 29 Kelly RG, Jerome-Majewska LA, Papaioannou VE. The del22q11.2 candidate gene Tbx1 regulates branchiomeric myogenesis. *Hum Mol Genet* 2004;13:2829–40.
- 30 Vissers LE, Stankiewicz P. Microdeletion and microduplication syndromes. *Methods Mol Biol* 2012;838:29–75.
- 31 Bedeschi MF, Colombo L, Mari F, Hofmann K, Rauch A, Gentilin B, Renieri A, Clerici D. Unmasking of a recessive SCARF2 mutation by a 22q11.2 de novo deletion in a patient with Van den Ende-Gupta syndrome. *Mol Syndromol* 2010;1:239–45.
- 32 Budarf ML, Konkle BA, Ludlow LB, Michaud D, Li M, Yamashiro DJ, McDonald-McGinn D, Zackai EH, Driscoll DA. Identification of a patient with Bernard-Soulier syndrome and a deletion in the DiGeorge/velo-cardio-facial chromosomal region in 22q11.2. *Hum Mol Genet* 1995;4:763–6.
- 33 Ludlow LB, Schick BP, Budarf ML, Driscoll DA, Zackai EH, Cohen A, Konkle BA. Identification of a mutation in a GATA binding site of the platelet glycoprotein Ibbeta promoter resulting in the Bernard-Soulier syndrome. *J Biol Chem* 1996;271:22076–80.
- 34 Hohenstein AC, Roche PA. SNAP-29 is a promiscuous syntaxin-binding SNARE. *Biochem Biophys Res Co* 2001;285:167–71.
- 35 Rotem-Yehudar R, Galperin E, Horowitz M. Association of insulin-like growth factor 1 receptor with EHD1 and SNAP29. *J Biol Chem* 2001;276:33054–60.
- 36 Rapaport D, Lugassy Y, Sprecher E, Horowitz M. Loss of SNAP29 impairs endocytic recycling and cell motility. *PLoS One* 2010;5:e9759.
- 37 Kousseff BG. Sacral meningocele with conotruncal heart defects: a possible autosomal recessive trait. *Pediatrics* 1984;74:395–8.
- 38 Toriello HV, Sharda JK, Beaumont EJ. Autosomal recessive syndrome of sacral and conotruncal developmental field defects (Kousseff syndrome). *Am J Med Genet* 1985;22:357–60.
- 39 Forrester S, Kovach MJ, Smith RE, Rimer L, Wesson M, Kimonis VE. Kousseff syndrome caused by deletion of chromosome 22q11–13. *Am J Med Genet* 2002;112:338–42.
- 40 Maclean K, Field MJ, Colley AS, Mowat DR, Sparrow DB, Dunwoodie SL, Kirk EPE. Kousseff syndrome: a causally heterogeneous disorder. *Am J Med Genet A* 2004;124A:307–12.
- 41 Robin NH, Feldman GJ, Aronson AL, Mitchell HF, Weksberg R, Leonard CO, Burton BK, Josephson KD, Laxova R, Aleck KA, Allanson JE, Guinalmeida ML, Martin RA, Leichtman LG, Price RA, Opitz JM, Muenke M. Opitz syndrome is genetically heterogeneous, with one locus on Xp22, and a 2nd locus on 22q11.2. *Nat Genet* 1995;11:459–61.
- 42 McDonald-McGinn DM, Emanuel BS, Zackai EH. Autosomal dominant "Opitz" GBBB syndrome due to a 22q11.2 deletion. *Am J Med Genet* 1996;64:525–6.
- 43 McDonaldmgin DM, Driscoll DA, Bason L, Christensen K, Lynch D, Sullivan K, Canning D, Zavod W, Quinn N, Rome J, Paris Y, Weinberg P, Clark BJ, Emanuel BS, Zackai EH. Rapid publication—autosomal-dominant opitz Gbbb syndrome due to a 22q11.2 deletion. *Am J Med Genet* 1995;95:103–13.
- 44 Fryburg JS, Lin KY, Golden WL. Chromosome 22q11.2 deletion in a boy with Opitz (G/BBB) syndrome. *Am J Med Genet* 1996;62:274–5.
- 45 Lacassie Y, Arriaza MI. Opitz GBBB syndrome and the 22q11.2 deletion. *Am J Med Genet* 1996;62:318.
- 46 Erickson RP, de Stahl TD, Bruder CEG, Dumanski JP. A patient with 22q11.2 deletion and opitz syndrome-like phenotype has the same deletion as velocardiofacial patients. *Am J Med Genet A* 2007;143A:3302–8.
- 47 Williams CA, Frias JL. Apparent G-syndrome presenting as neck and upper limb dystonia and severe gastroesophageal reflux. *Am J Med Genet* 1987;28:297–302.
- 48 Neri G, Genuardi M, Natoli G, Costa P, Maggioni G. A girl with G syndrome and agenesis of the corpus callosum. *Am J Med Genet* 1987;28:287–91.
- 49 Borner GHH, Harbour M, Hester S, Lilley KS, Robinson MS. Comparative proteomics of clathrin-coated vesicles. *J Cell Biol* 2006;175:571–8.
- 50 de Queiroz Soares DC, Dutra RL, D'Angioli Costa Quairo CR, Melaragno MI, Kulikowski LD, Torres LC, Kim CA. Role of SNAP29, LZTR1 and P2RX1 genes on immune regulation in a patient with atypical 0.5Mb deletion in 22q11.2 region. *Clin Immunol* 2012;145:55–8.

51 Stalmans I, Lambrechts D, De smet F, Jansen S, Wang J, Maity S, Kneer P, von der Ohe M, Swillen A, Maes C, Gewillig M, Molin DGM, Hellings P, Boetel T, Haardt M, Compennolle V, Dewerchin M, Plaisance S, Vlietinck R, Emanuel B,

Gittenberger-de Groot AC, Scambler P, Morrow B, Driscoll DA, Moons L, Esguerra CV, Carmeliet G, Behn-Krappa A, Devriendt K, Collen D, Conway SJ, Carmeliet P. VEGF: A modifier of the del22q11 (DiGeorge) syndrome? *Nat Med* 2003;9:173–82.