



Adaptor protein complex-4 (AP-4) deficiency causes a novel autosomal recessive cerebral palsy syndrome with microcephaly and intellectual disability

Andres Moreno-De-Luca,¹ Sandra L Helmers,² Hui Mao,³ Thomas G Burns,⁴ Amanda M A Melton,⁴ Karen R Schmidt,¹ Paul M Fernhoff,¹ David H Ledbetter,¹ Christa L Martin¹

► An additional figure is published online only. To view this file please visit the journal online (<http://jmg.bmj.com>).

¹Department of Human Genetics, Emory University School of Medicine, Atlanta, Georgia, USA

²Department of Neurology, Emory University School of Medicine, Atlanta, Georgia, USA

³Department of Radiology, Emory University School of Medicine, Atlanta, Georgia, USA

⁴Department of Neuropsychology, Children's Healthcare of Atlanta, Atlanta, Georgia, USA

Correspondence to

Christa L Martin, 615 Michael Street, Suite 301, Atlanta, GA 30322, USA; christa.martin@emory.edu

Received 22 June 2010

Revised 27 August 2010

Accepted 30 August 2010

Published Online First

23 October 2010

ABSTRACT

Background Cerebral palsy is a heterogeneous group of neurodevelopmental brain disorders resulting in motor and posture impairments often associated with cognitive, sensorial, and behavioural disturbances. Hypoxic–ischaemic injury, long considered the most frequent causative factor, accounts for fewer than 10% of cases, whereas a growing body of evidence suggests that diverse genetic abnormalities likely play a major role.

Methods and results This report describes an autosomal recessive form of spastic tetraplegic cerebral palsy with profound intellectual disability, microcephaly, epilepsy and white matter loss in a consanguineous family resulting from a homozygous deletion involving *AP4E1*, one of the four subunits of the adaptor protein complex-4 (AP-4), identified by chromosomal microarray analysis.

Conclusion These findings, along with previous reports of human and mouse mutations in other members of the complex, indicate that disruption of any one of the four subunits of AP-4 causes dysfunction of the entire complex, leading to a distinct 'AP-4 deficiency syndrome'.

INTRODUCTION

Cerebral palsy (CP) is a heterogeneous group of neurodevelopmental brain disorders resulting in motor and posture impairments often associated with epilepsy and disturbances of cognition, behaviour, sensation, and communication. CP is classified according to the characteristics of the movement disorder observed (spastic, ataxic, dystonic, or atetoid) and the extremities involved (monoplegia, hemiplegia, diplegia, or tetraplegia). With a prevalence of 2–3/1000 births and an estimated 750 000 or more affected American children and adults, CP is the most common physical disability of childhood.¹

Although the aetiology of CP has been attributed to a variety of factors, the specific mechanism underlying most cases remains unknown. Despite earlier assumptions, CP turns out to be only rarely caused by birth asphyxia, as indicated by large population based controlled studies. Conversely, as many as ~50% of idiopathic CP cases in children born at term are now thought to be caused by genetic factors.² Support for genetic causes includes the identification of specific genetic abnormalities, such as mutations in *ANKRD15*, *GAD1* and *PROC* segregating with the disease in CP pedigrees,^{3–5} and the high prevalence of congenital anomalies in CP

patients (15%),⁶ of which microcephaly and hydrocephaly are the most common. Additional evidence for genetic contributions comes from twin studies,⁷ the 2.5-fold increased rate of CP in consanguineous families,⁸ familial clustering,⁹ and a paternal age effect.¹⁰

CLINICAL EVALUATION

We evaluated a Palestinian–Jordanian consanguineous family with two siblings affected by an idiopathic neurological condition described as cerebral palsy (figure 1A). This study was approved by our institutional review board and written informed consent was obtained. Both probands were evaluated by a clinical geneticist, a neurologist/epileptologist, and a neuropsychologist, all of whom acquired a detailed clinical history, reviewed previous medical records, and performed comprehensive evaluations. The clinical findings are summarised in table 1.

Patient IV-4 was born after a full term pregnancy and uneventful labour and delivery. At birth she presented with microcephaly and hypotonia that progressed to spastic tetraplegia with hyperreflexia and generalised hypertonia by the first year of life. She never developed speech or independent walking and has been wheelchair-bound since 5 years of age, when she also started experiencing generalised tonic-clonic seizures. Examination at age 23 showed microcephaly (–3 SD), profoundly impaired cognitive ability, deficient adaptive skills (age equivalents <1 year of age), drooling, and outbursts of stereotypic laughter. Dysmorphic features included bitemporal narrowing, long narrow face with prominent pointed chin, downslanting palpebral fissures, long nose with wide nasal ridge, short philtrum with everted full upper vermillion, prominent antehelix of the ears, and facial hypotonia. A brain MRI revealed ventriculomegaly, cortical and cerebellar atrophy, reduced hippocampal volume, and diffuse white matter loss that was more pronounced in the frontal region and corpus callosum (supplementary figure 1). An electroencephalogram (EEG) showed generalised theta slowing of the background, consistent with a diffuse cerebral dysfunction.

Patient IV-5 was born at term after an unremarkable pregnancy and normal labour and delivery. Postnatally he presented with microcephaly and hypotonia, and by the first year of life developmental delay was evident. He acquired some

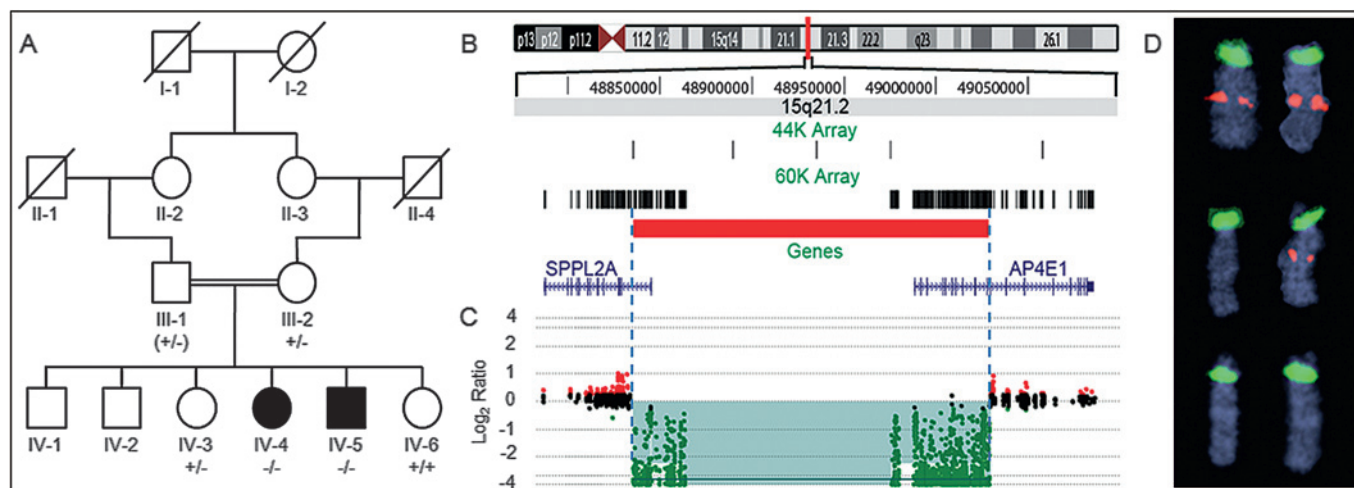


Figure 1 Pedigree and 15q21.2 deletion region. (A) Pedigree structure of the family. Deletion status is shown for available individuals and represented with $-/-$, homozygous deletion; $+/-$, heterozygous deletion; and $+/+$, non-deleted. Subject III-1 was not available; however, he was described as healthy and is inferred to be a carrier of the deleted allele, indicated by parenthesis. (B) Chromosome 15q21.2 schematic showing the deletion found in our patients, depicted as a horizontal red line. Vertical black bars represent probes from the whole genome 44K array and the tiling 60K array used to fine map the deletion breakpoints. The two genes involved are *SPPL2A* and *AP4E1*. (C) Array comparative genomic hybridisation (CGH) results of patient IV-5 used to represent the deletion in both patients. The x-axis displays the genomic position of the probes and the y-axis displays the \log_2 ratios of the patient sample hybridised against a normal control. Each dot represents a single probe; normal copy number probes are coloured in black and deleted probes in green. The deleted region is highlighted in green. (D) Metaphase fluorescent in situ hybridisation (FISH) results for chromosome 15. The probe within the deleted region is labelled in red; the control probe, located in the centromeric region of chromosome 15, is labelled in green. Top panel, normal FISH results from the younger sibling (IV-6); middle panel, heterozygous deletion identified in the mother and older sister (III-2, IV-3); bottom panel, homozygous deletion found in both probands (IV-4, IV-5).

dysarthric words, but never normal speech, and was able to walk with support, although increasing spasticity made him wheelchair-dependent by age 9 years. Seizures started with staring spells and developed into generalised tonic-clonic at age 15. On examination at 22 years, he had spastic tetraplegia with hyper-tonia and hyperreflexia, outbursts of stereotypic laughter, drooling, and jerky nystagmus. Severe cognitive deficits were noted, as well as adaptive impairments, with all age equivalents <1 year of age. Dysmorphic features and an EEG profile were very similar to patient IV-4. A head CT scan showed moderate ventriculomegaly with slightly prominent cisterns.

METHODS AND RESULTS

We performed clinical chromosomal microarray analysis, a first-tier diagnostic cytogenetic test for individuals with developmental disabilities and/or congenital anomalies,¹² on genomic DNA from both patients using a custom designed oligonucleotide array on a $4 \times 44K$ platform, according to standard protocols (Agilent Technologies, Santa Clara, California, USA). The array combines both backbone coverage across the whole genome (probes spaced on average every 75 kb) and targeted coverage of clinically relevant regions (a minimum of 10 probes per gene or region, as described in Baldwin *et al*¹³). Data analysis was performed using Feature Extraction (version 10.5.1.1) and DNA Analytics (Version 4.0.81) software (Agilent Technologies). We identified a 139 kb (minimum) to 222 kb (maximum) homozygous deletion of chromosome 15q21.2 that includes the 5' end of two genes: *AP4E1* (adaptor related protein complex-4, epsilon-1) and *SPPL2A* (signal peptide peptidase-like-2A). To define the deletion breakpoints better, we developed a 60K high resolution array that targets the region around these two genes with 2173 oligonucleotides (probes spaced every 22 base pairs) and used this array to define the size of the deleted region to 192 kb (chr15:48835480-49028171; hg18 genome assembly, figure 1B, C). The results were confirmed by fluorescence in situ

hybridisation (FISH) analysis performed on metaphase spreads using bacterial artificial chromosome clone probes as previously described.¹³ The probe within the deleted interval was RP11-147B19, and the control probe outside the region was D15Z1, corresponding to the centromeric region of chromosome 15 (figure 1D).

We next undertook additional studies to establish the inheritance pattern of the disorder. FISH analysis on the mother revealed that she is a heterozygous carrier of the deletion. Since a paternal sample was not available, we performed *SNRPN* methylation analysis on both probands using methylation sensitive PCR according to standard methods¹⁴ and confirmed the presence of both methylated and unmethylated alleles, consistent with biparental inheritance for chromosome 15. Therefore, the father is inferred to be a carrier of this deletion. Additional FISH analysis was also carried out on other unaffected family members (figure 1A).

DISCUSSION

The deletion includes the *AP4E1* gene, encoding the ϵ subunit of the adaptor protein complex-4 (AP-4), a heterotetramer composed of four subunits encoded by different genes: *AP4E1*, *AP4B1*, *AP4M1*, and *AP4S1*. There are four members of the AP-complex family that mediate the sorting of integral membrane proteins: AP-1, AP-2, AP-3, and AP-4, each comprising two large subunits (γ , α , δ or ϵ and $\beta 1-4$), one medium subunit ($\mu 1-4$), and one small subunit ($\sigma 1-4$).¹⁵ AP-4 is ubiquitously expressed in neurons throughout the embryologic and postnatal developmental stages.^{11 16} It interacts with $\delta 2$ and α -amino-3-hydroxy-5-methyl-4-isoxazolepropionic acid (AMPA) glutamate receptors to selectively transport them from the trans-Golgi network to the postsynaptic somatodendritic domain.¹⁷ Additionally, AP-4 mediates the transport of amyloid precursor protein (APP) from the trans-Golgi network to endosomes. Disruption of the APP-AP-4 interaction enhances γ -secretase-catalysed cleavage of APP

Table 1 Clinical findings in adaptor protein complex-4 (AP-4) deficiency syndrome patients

Patient	Present study		Verkerk <i>et al</i> 2009 ¹¹				
	IV-4	IV-5	IV-1	IV-3	IV-4	IV-5*	IV-6
AP-4 subunit disrupted	AP4E1	AP4E1	AP4M1	AP4M1	AP4M1	AP4M1	AP4M1
Sex	F	M	F	M	F	M	M
Age at evaluation (years)	23	22	24	23	22	1.5	21
Early infantile hypotonia	+	+	+	+	+	+	+
Spastic tetraplegia	+	+	+	+	+	NA	+
Hypertonia	+	+	+	+	+	NA	+
Hyperreflexia	+	+	+	+	+	NA	+
Babinski sign	+	+	+	+	+	NA	+
Head circumference	-3 SD	-3 SD	-1 SD	0 SD	-2 SD	NA	-2.5 SD
Severe ID	+	+	+	+	+	+	+
Epilepsy	+	+	-	-	-	-	-
Ambulation	-	-	-	-	-	NA	-
Normal speech	-	-	-	-	-	NA	-
Sphincter control	-	-	-	-	-	NA	-
Stereotypic laughter	+	+	+	+	+	NA	+
Drooling	+	+	+	+	+	NA	+
Eye evaluation	Normal	Normal	NA	Normal	NA	NA	Pale optic discs
Hearing evaluation	Normal	Normal	NA	NA	NA	NA	NA
Neuroimaging	MRI: dilated ventricles, cerebellar atrophy, abnormal white matter	CT: dilated ventricles, prominent cisterns	CT: normal (age 3 months)	MRI: dilated ventricles, cerebellar atrophy, abnormal white matter	MRI: dilated ventricles, abnormal white matter	NA	MRI: dilated ventricles, cerebellar atrophy, abnormal white matter

*Patient died at 17 months of age from aspiration pneumonia.

F, female; ID, intellectual disability; M, male; NA, not available; +, present; -, absent.

to amyloid- β peptide, making AP-4 deficiency a potential risk factor for Alzheimer's disease.¹⁸

The *SPPL2A* gene, also included in the deleted region, encodes a member of the signal peptide peptidase-like family of intramembrane cleaving proteases thought to play a role in immune regulation.¹⁹ Although we cannot completely rule out a potential pathogenic role for *SPPL2A*, or that its deletion might contribute to the phenotype, we propose that *AP4E1* deficiency is the main underlying genetic mechanism responsible for the clinical findings observed in our patients. Support for *AP4E1* as the causative gene comes from a recent report of a homozygous mutation in *AP4M1* causing an autosomal recessive form of spastic CP in five siblings from a Moroccan inbred sibship.¹¹ Interestingly, the affected individuals share many clinical features with our family (table 1). They presented with infantile hypotonia that progressed to spastic tetraplegia, hypertonia and hyperreflexia by the first year of life, microcephaly, severe intellectual disability, stereotypic laughter, and drooling. Neuroimaging revealed ventriculomegaly and white matter loss. Since the facial phenotype was unavailable, we could not confirm whether the craniofacial dysmorphic features described in our patients are also present in the affected members of this family.

Several lines of evidence suggest that disrupting any subunit of AP-4 results in dysfunction of the entire complex. Two unrelated families with homozygous disruptions in different subunits (ϵ and μ) show extremely similar clinical phenotypes (this report and the family reported by Verkerk *et al*¹¹). Selective downregulation by antisense RNA confirmed that absence of the μ subunit yields no functional AP-4.¹⁷ Data on a third subunit comes from knockout mice generated by the homozygous disruption of the β subunit lacking functional AP-4, resulting in axonal swelling due to mislocalisation and accumulation of glutamate receptors in autophagosomes near the axon terminals of Purkinje cells and hippocampal neurons.¹⁷ Finally, similar

results have been observed in other members of the AP-complex family: knockdown of the σ subunit of AP-2 results in destabilisation of the entire AP-2,²⁰ and mutations in the β 3A and δ subunits of AP-3 lead to drastically reduced levels of all four subunits and no functional AP-3.²¹ Therefore, we propose that disruption of any one of the four subunits of AP-4 abolishes its function and causes a distinct autosomal recessive disorder that we refer to as 'AP-4 deficiency syndrome'. It will be interesting to perform comprehensive mutational analysis, including resequencing and high resolution deletion/duplication analysis, of *AP4E1*, *AP4M1*, *AP4B1*, and *AP4S1*, on other CP individuals and families to determine the frequency of this disorder.

Our findings add to the growing body of evidence for multiple genetic aetiologies for CP and shed light on potential pathogenic mechanisms underlying this condition. As with other developmental brain disorders, such as intellectual disability, autism, and schizophrenia, CP is likely caused by many rare, single gene events. Rapid advances in high throughput technologies, including whole genome sequencing and copy number array analysis, will soon make it feasible to identify rare and private familial mutations in a cost effective way, first in a research setting, and ultimately in a routine, clinical setting.

Acknowledgements We would like to thank the family for participating in this study. We also thank D Moreno-De-Luca and EB Kaminsky for critical comments of this manuscript, D Kunig and L Wang for expert technical assistance, and C Strauss for editorial assistance.

Funding This work was funded in part by grant MH074090 (to DHL and CLM) from the National Institutes of Health.

Competing interests None declared.

Patient consent Obtained.

Ethics approval This study was conducted with the approval of the Emory University Institutional Review Board.

Provenance and peer review Not commissioned; externally peer reviewed.

REFERENCES

1. **Pakula AT**, Van Naarden Braun K, Yeargin-Allsopp M. Cerebral palsy: classification and epidemiology. *Phys Med Rehabil Clin N Am* 2009;**20**:425–52.
2. **Costeff H**. Estimated frequency of genetic and nongenetic causes of congenital idiopathic cerebral palsy in west Sweden. *Ann Hum Genet* 2004;**68**:515–20.
3. **Lerer I**, Sagi M, Meiner V, Cohen T, Zlotogora J, Abeliovich D. Deletion of the ANKRD15 gene at 9p24.3 causes parent-of-origin-dependent inheritance of familial cerebral palsy. *Hum Mol Genet* 2005;**14**:3911–20.
4. **Lynex CN**, Carr IM, Leek JP, Achuthan R, Mitchell S, Maher ER, Woods CG, Bonthon DT, Markham AF. Homozygosity for a missense mutation in the 67 kDa isoform of glutamate decarboxylase in a family with autosomal recessive spastic cerebral palsy: parallels with Stiff-Person Syndrome and other movement disorders. *BMC Neurol* 2004;**4**:20.
5. **Fong CY**, Mumford AD, Likeman MJ, Jardine PE. Cerebral palsy in siblings caused by compound heterozygous mutations in the gene encoding protein C. *Dev Med Child Neurol* 2010;**52**:489–93.
6. **Rankin J**, Cans C, Garne E, Colver A, Dolk H, Uldall P, Amar E, Krageloh-Mann I. Congenital anomalies in children with cerebral palsy: a population-based record linkage study. *Dev Med Child Neurol* 2010;**52**:345–51.
7. **Petterson B**, Stanley F, Henderson D. Cerebral palsy in multiple births in Western Australia: genetic aspects. *Am J Med Genet* 1990;**37**:346–51.
8. **al-Rajeh S**, Bademosi O, Awada A, Ismail H, al-Shammasi S, Dawodu A. Cerebral palsy in Saudi Arabia: a case-control study of risk factors. *Dev Med Child Neurol* 1991;**33**:1048–52.
9. **Hemminki K**, Li X, Sundquist K, Sundquist J. High familial risks for cerebral palsy implicate partial heritable aetiology. *Paediatr Perinat Epidemiol* 2007;**21**:235–41.
10. **Fletcher NA**, Foley J. Parental age, genetic mutation, and cerebral palsy. *J Med Genet* 1993;**30**:44–6.
11. **Verkerk AJ**, Schot R, Dumee B, Schellekens K, Swagemakers S, Bertoli-Avella AM, Lequin MH, Dudink J, Govaert P, van Zwol AL, Hirst J, Wessels MW, Catsman-Berrevoets C, Verheijen FW, de Graaff E, de Coo IF, Kros JM, Willemsen R, Willems PJ, van der Spek PJ, Mancini GM. Mutation in the AP4M1 gene provides a model for neuroaxonal injury in cerebral palsy. *Am J Hum Genet* 2009;**85**:40–52.
12. **Miller DT**, Adam MP, Aradhya S, Biesecker LG, Brothman AR, Carter NP, Church DM, Crolla JA, Eichler EE, Epstein CJ, Faucett WA, Feuk L, Friedman JM, Hamosh A, Jackson L, Kaminsky EB, Kok K, Krantz ID, Kuhn RM, Lee C, Ostell JM, Rosenberg C, Scherer SW, Spinner NB, Stavropoulos DJ, Tepperberg JH, Thorland EC, Vermeesch JR, Waggoner DJ, Watson MS, Martin CL, Ledbetter DH. Consensus statement: chromosomal microarray is a first-tier clinical diagnostic test for individuals with developmental disabilities or congenital anomalies. *Am J Hum Genet* 2010;**86**:749–64.
13. **Baldwin EL**, Lee JY, Blake DM, Bunke BP, Alexander CR, Kogan AL, Ledbetter DH, Martin CL. Enhanced detection of clinically relevant genomic imbalances using a targeted plus whole genome oligonucleotide microarray. *Genet Med* 2008;**10**:415–29.
14. **Kubota T**, Das S, Christian SL, Baylin SB, Herman JG, Ledbetter DH. Methylation-specific PCR simplifies imprinting analysis. *Nat Genet* 1997;**16**:16–17.
15. **Dell'Angelica EC**, Mullins C, Bonifacino JS. AP-4, a Novel Protein Complex Related to Clathrin Adaptors. *J Biol Chem* 1999;**274**:7278–85.
16. **Yap CC**, Murate M, Kishigami S, Muto Y, Kishida H, Hashikawa T, Yano R. Adaptor protein complex-4 (AP-4) is expressed in the central nervous system neurons and interacts with glutamate receptor delta2. *Mol Cell Neurosci* 2003;**24**:283–95.
17. **Matsuda S**, Miura E, Matsuda K, Kakegawa W, Kohda K, Watanabe M, Yuzaki M. Accumulation of AMPA receptors in autophagosomes in neuronal axons lacking adaptor protein AP-4. *Neuron* 2008;**57**:730–45.
18. **Burgos PV**, Mardones GA, Rojas AL, daSilva LL, Prabhu Y, Hurley JH, Bonifacino JS. Sorting of the Alzheimer's disease amyloid precursor protein mediated by the AP-4 complex. *Dev Cell* 2010;**18**:425–36.
19. **Friedmann E**, Hauben E, Maylandt K, Schleeper S, Vreugde S, Lichtenthaler SF, Kuhn PH, Stauffer D, Rovelli G, Martoglio B. SPPL2a and SPPL2b promote intramembrane proteolysis of TNFalpha in activated dendritic cells to trigger IL-12 production. *Nat Cell Biol* 2006;**8**:843–8.
20. **Borck G**, Molla-Herman A, Boddaert N, Encha-Razavi F, Philippe A, Robel L, Desguerre I, Brunelle F, Benmerah A, Munnich A, Colleaux L. Clinical, cellular, and neuropathological consequences of AP1S2 mutations: further delineation of a recognizable X-linked mental retardation syndrome. *Hum Mutat* 2008;**29**:966–74.
21. **Dell'Angelica EC**, Shotelersuk V, Aguilar RC, Gahl WA, Bonifacino JS. Altered trafficking of lysosomal proteins in Hermansky-Pudlak syndrome due to mutations in the beta 3A subunit of the AP-3 adaptor. *Mol Cell* 1999;**3**:11–21.

Journal of Medical Genetics online

Visit **JMG online** for free editor's choice articles, online archive, email alerts, blogs or to submit your paper. Keep informed and up to date by registering for electronic table of contents at jmg.bmj.com.