

Familial Sotos syndrome is caused by a novel 1 bp deletion of the *NSD1* gene

P Höglund, N Kurotaki, S Kytölä, N Miyake, M Somer, N Matsumoto

J Med Genet 2003;40:51–54

Sotos syndrome (SS) or cerebral gigantism (OMIM *117550) is characterised by excessive growth, advanced bone age, typical facial gestalt, and developmental delay.^{1,2} In infancy growth is rapid, but settles down above the >97th centile in early childhood^{3,4} and tends to follow this during childhood. The adult height remains close to normal.⁴ The hands and feet are large. The facial gestalt is very characteristic during childhood with macrocephaly (>97th centile), frontal bossing, prognathism, hypertelorism, and antimongoloid slant of the palpebral fissures. With increasing age, the face gradually lengthens, the jaw becomes more prominent, and macrocephaly is no longer pronounced.^{5,6} Neurological features are variable and include hypotonia and delay in motor and language development, with a tendency for improvement with age.^{1,2,5–9} Familial SS is rare. Only 17 families have been reported, most of which show an autosomal dominant mode of inheritance.^{5,6,10–19}

Recent advances have shown a molecular genetic basis for sporadic SS. Initially, two SS patients carrying de novo balanced translocations suggested 5q35 as a possible locus for the SS gene.^{20,21} Subsequently, the *NSD1* gene was isolated from the 5q35 breakpoint of the patient with t(5;8)(q35;q24.1) by positional cloning.^{22,23} *NSD1* has an open reading frame of 8088 bp and consists of at least 23 exons (GenBank accession No AF395588). *NSD1* is expressed in the fetal/adult brain, kidney, skeletal muscle, spleen, and the thymus, and faintly in the lung.²² The gene encodes 2696 amino acids with SET (su(var)3-9, enhancer-of-zeste, trithorax), PHD (plant homeodomain protein) finger, and PWWP (proline-tryptophan-tryptophan-proline) domains, all of which are possibly related to chromatin regulation, and possibly interact with nuclear receptors (Nrs).²² Among 42 sporadic SS patients examined by direct sequencing, altogether four de novo point mutations predicting truncation of the protein and 20 submicroscopic deletions involving the whole of *NSD1* were identified. Two-thirds of SS cases showed *NSD1* mutations, so haploinsufficiency of *NSD1* is suggested to be the major molecular defect in SS.²³ The role of *NSD1* in the pathogenesis of SS could be mediated through its action as a corepressor of genes that promote growth.^{23,25}

In this study, we describe a Finnish family with autosomal dominant segregation of classical SS, molecular genetic findings, and FISH analysis of an obvious candidate gene, *NSD1*.

CLINICAL PHENOTYPES

Patient 1 (son)

The proband is the first child of his parents, but the mother has a healthy daughter from a previous marriage. The pregnancy was complicated by diet treated gestational diabetes. The baby was born prematurely by vaginal delivery, large for gestational age (table 1). Apgar score was 9. The neonatal period was complicated by hypotonia, feeding difficulties, and transient hypoglycaemia, requiring nasogastric tube feeding for six weeks. X ray showed an abnormally elongated shape of the skull and abnormally positioned orbits. EEG

Key points

- Sotos syndrome (SS) is characterised by excessive growth, characteristic facial gestalt, advanced bone age, and early developmental delay with a non-progressive or receding course with age.
- Recently, deletions and four different point mutations of the *NSD1* gene were found to be responsible for Sotos syndrome (SS) in 24 out of 42 Japanese patients, all of whom were sporadic. Although >98% of SS patients have a negative family history, a few families with confirmed parent to offspring inheritance have been described.
- Here we report the first *NSD1* gene mutation segregating in a Finnish family with two members with classical SS. Both a male infant and his father had a novel 896delC mutation resulting in a frameshift and premature stop codon at nucleotides 955-957 of the *NSD1* gene.
- These findings confirm that sporadic and familial SS comprise a single entity and both can be caused by mutations in the *NSD1* gene.

showed non-specific abnormalities. Abdominal ultrasound examination and karyotype of cultured peripheral blood lymphocytes were normal.

At the age of 4 months (not corrected for prematurity), the baby was remarkably hypotonic and drowsy. He was tall (+2.1 SD) and macrocephalic (+3 SD) and his height adjusted weight was +10% (8460 g). His bone age was between 9 and 12 months. His facial characteristics included slight hypertelorism and inner epicanthic folds (fig 1). The forehead was slightly prominent with bizygomatic narrowing and frontoparietal baldness. The palpebral fissures were straight and narrow. The jaw was small and the palate was high. He had slightly oedematous hands and feet, and his toenails were deep set. His hands and feet were fairly large, but within normal limits, and there were bilateral simian creases. The truncal skin was loose. The deep tendon reflexes were slightly brisk. His psychomotor development was delayed in terms of lack of reciprocal smile, poor fixation of eyes, and marked hypotonia. Ophthalmological examination showed hyperopia of +3 D and the papillae were pale. The electroretinogram was normal, but visual evoked potentials to flash stimuli showed extended latency with normal potentials. The magnetic resonance imaging (MRI) of the brain showed dilated lateral ventricles and wide frontal cortical spaces, scarcity of periventricular white matter on the trigonum, and a thin corpus callosum. Laboratory tests showed normal blood haemoglobin level, serum creatinine kinase, alanine aminotransferase, whole blood pyruvate, and plasma lactate, and slightly raised ionised calcium in plasma. Based on these data, a clinical diagnosis of Sotos syndrome was made.

Table 1 Clinical features of Sotos syndrome in our two patients illustrates their course of growth, development, and facial gestalt

	Patient 1	Patient 2
Sex	Male	Male
Age	18 months	29 years
Gestation (weeks)	36	38
BW: LGA*	4200 g (+2.5 SD)†	4700 g (+3.1 SD)†
BL	54 cm (+2.3 SD)†	55 cm (+2.5 SD)†
OFC at birth	39 cm (+3 SD)	NA
Neonatal hypoglycaemia	+ Transient	+ Transient
Neonatal feeding problems	+ Nasogastric feeding for 6 weeks	+ Nasogastric feeding for 4 weeks
Advanced postnatal growth	++ 6 mth: 75.5 cm (+2.7 SD) 16 mth: 92 cm (+4 SD)	++ 5 y: 120 cm (+2.4 SD) Adult: 186 cm (+1.1 SD)
Advanced bone age	+ 9–12 mth at calendar age of 4 mth	+ Slightly dysharmonic maturation
Macrocephaly	++ 4 mth: 46.6 cm (+3 SD) 16 mth: 53.5 cm (+2.8 SD)	++ 6 mth: 48 cm (+3 SD) 5 y: 56 cm (+3 SD) Adult: 61.6 cm (+3 SD)
Large hands	± 75–95th centile	++ >>97th centile
Large feet	± 75–95th centile	++ >>97th centile
Increased arm span	NA	+
Hypotonia	++	++ Childhood
Delayed motor skills	+	+
Delayed speech	±	+
Frontal bossing	++	±
Midfacial narrowing	+	+
Palpebral fissures slanting downwards	–	+
Frontoparietal baldness	++	–
Jaw	Small	Pointed chin, prognathism
High arched palate	+	+

*LGA, large for gestational age.

†SD, standard deviation, corrected for gestational age.

NA, not available.

His growth has continued to be rapid and his psychomotor development has progressed well, in terms of sitting at the age of 9 months, crawling and getting up to standing position at the age of 14 months, and walking with support soon after. At 16 months, he spoke no words but was babbling. Hypotonia was milder, but poor motor skills of the oral and throat region affected both speech and consuming liquid nutriment, and he drooled abundantly. At present, he receives physiotherapeutic and logopedic support. Owing to hyperopia and strabismus, a spectacle correction of +4.0 D for both eyes was recommended at the age of 13 months.

Patient 2 (father)

The father is a 29 year old male, born as the second child of the family. At birth, he was large for gestational age despite maternal pre-eclampsia. His Apgar scores were 7. Neonatally, he showed hypoglycaemia, hypotonia, a hoarse cry, and poor sucking requiring nasogastric tube feeding for 4 weeks. A systolic heart murmur was heard, which disappeared before 6 months of age.

His growth was rapid and he was macrocephalic (table 1). His motor development was delayed, and at 5 years he was reinvestigated because of hypotonia and delayed speech. At 6 months of age the EEG was normal, but brain ultrasound examination showed mildly dilated lateral ventricles. He had brisk deep tendon reflexes in his lower extremities associated with clonus of the right ankle. The visual acuity was normal, but eye examination showed a few pigmentations below the right papilla. At 5 years, hand x ray showed slightly advanced bone age with dysharmonic maturation, phalangeal age being more advanced than carpal bone age. His phenotype was consistent with Sotos syndrome. Despite delayed early developmental milestones, he attended regular primary and senior

high schools, and received occupational education in both commercial and nursing colleges. Presently, he is working at a day care centre for children.

When re-examined together with his son, he had close to normal stature with macrocephaly and long extremities (table 1). He had long facies and a narrow midface giving an impression of hypertelorism, and his palpebral fissures slanted downwards (fig 1). His forehead was slightly prominent with normal hair in the frontoparietal regions. The mandible was prognathic with a prominent pointed chin. The nose and cheeks were erythematous. The palate was high, the teeth were maloccluded, and four of the permanent teeth were lost. His hands and feet were large.

MOLECULAR STUDIES OF THE NSD1 GENE

FISH analysis

For FISH, the PAC clone RP1-118m12 (ResGen Invitrogen Corporation, AL) was labelled with FITC-dUTP (DuPont, Boston, MA) and hybridised to peripheral blood metaphase spreads using standard methods. The results were analysed using a Zeiss Axioplan 2 (Carl Zeiss Jena GmbH, Jena, Germany) epifluorescence microscope equipped with a cooled CCD camera (Sensys, Photometrics Ltd, Tucson, AZ) interfaced to the ISIS imaging system (MetaSystems, Altlussheim, Germany).

Green signals were detected on both chromosome 5q35 regions. No deletion was found by FISH analysis (data not shown).

SEQUENCE ANALYSIS

After obtaining informed consent, 5 ml of EDTA blood were drawn from the two patients with SS and the healthy mother

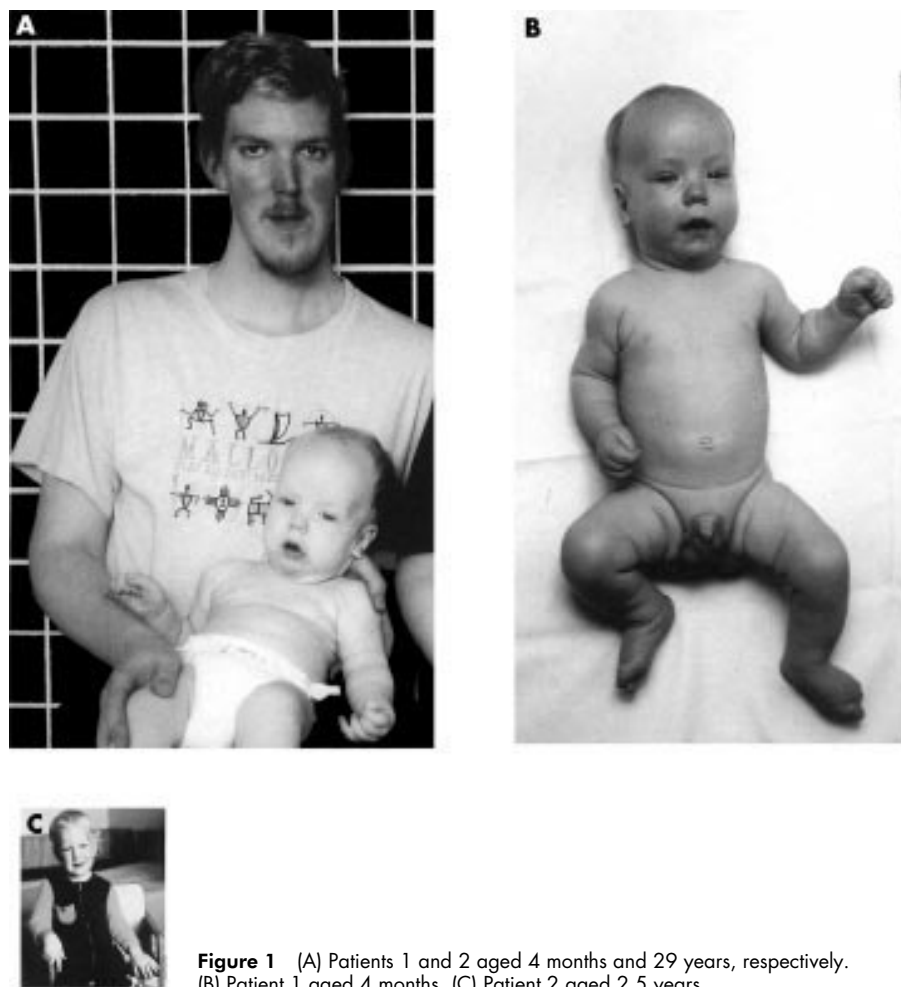


Figure 1 (A) Patients 1 and 2 aged 4 months and 29 years, respectively. (B) Patient 1 aged 4 months. (C) Patient 2 aged 2.5 years.

of the family. Genomic DNA was extracted from peripheral blood leucocytes following standard methods. Altogether 22 *NSD1* exons (exons 2-23) covering the coding region of *NSD1*²² were amplified by PCR. The primer sequences are available on request.²³ PCR was cycled 35 times at 95°C for 30 seconds, 50°C for 30 seconds, 72°C for one minute in a volume of 50 μ l, containing 1 \times PCR buffer with 1.5 mmol/l MgCl₂, 0.2 mmol/l each dNTP, 1 μ mol/l each primer, and 2.5 U *Taq*Gold polymerase (PE Applied Biosystems). PCR products were purified using the QIAquick PCR purification kit (Qiagen, Chatsworth, CA) and sequenced individually on both strands with BigDye Terminator chemistry by a standard protocol (PE Applied Biosystems) as described previously.²⁴

Genomic sequence analysis of *NSD1* showed a heterozygous deletion of a C at position 896 (896delC) in exon 2 in both affected subjects (fig 2). This change results in a frameshift and premature stop codon at nucleotides 955-957, resulting in truncation of 88% of the predicted polypeptide. The mutant allele was not found in the unaffected mother nor in 94 unrelated subjects from the Finnish population (data not shown).

DISCUSSION

We report the first mutation in the *NSD1* gene segregating in a family with SS, confirming that the familial form of this syndrome may be caused by mutations in the *NSD1* gene, haploinsufficiency of which has recently been shown to be the major cause of sporadic Sotos syndrome.²³

Previous clinical studies have shown that mental retardation is variable and not a constant feature of SS,² and especially in familial cases the early developmental delay

tends to recede with age. Interestingly, the milder clinical picture in this family was associated with an early truncating point mutation in the *NSD1* gene, whereas the majority of sporadic patients have a deletion of the whole *NSD1* gene along with several other genes residing on the 2.2 Mb segment of deleted DNA. The early developmental course of SS between patients with point mutations and larger deletion may thus be overlapping, although more severe and constant mental retardation may be associated with larger deletions. This is the first report providing preliminary evidence for the phenotype-genotype correlation in Sotos syndrome.

The spectrum of other clinical features appears to be similar in our two patients with a single nucleotide deletion and classical SS patients. In addition to rapid pre- and postnatal growth with a slightly advanced bone age, typical development of the facial gestalt, and early developmental delay, our patients also presented with several other occasional or transient features associated with SS, such as ocular^{26,27} and neuroradiological findings,⁷ suggesting a major pleiotropic role of the *NSD1* gene in SS.

Familial Sotos syndrome is rare and many of these diagnoses have even been questioned afterwards because of lack of sufficient data.^{5,6} For this reason, figures for the incidence of sporadic SS is unknown. In the past, the absence of biochemical and molecular markers has made it difficult to distinguish between Sotos and other overgrowth conditions with varying degree of clumsiness and developmental delay.⁵ Particularly in adulthood, the diagnosis of SS may be challenging because the increased height and macrocephaly are not as pronounced as in childhood and the criterion of advanced bone age cannot be applied. It is not unusual that

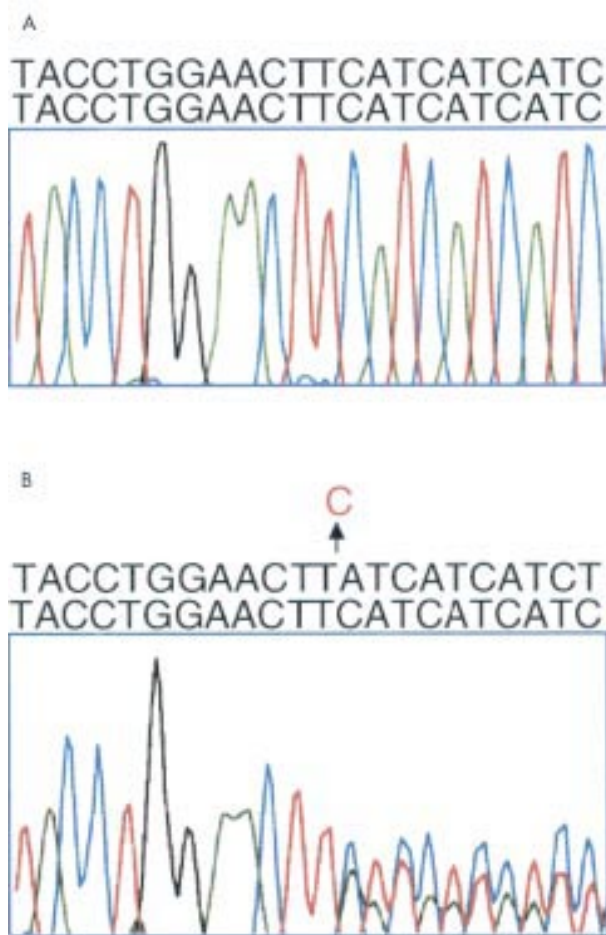


Figure 2 Partial sequence of the *NSD1* gene in exon 2 in a control (A) and in a patient with familial SS (B). An arrow points to the deletion of a single C.

the diagnosis of SS is made in an adult via an affected child. Nowadays, confirmation of the SS diagnosis by genetic testing is available for approximately 50-70% of patients, allowing more precise genetic counselling and more accurate figures of incidence for both familial and sporadic SS.

Previously, over-representation of sporadic patients with SS has been explained by high mutation rate and reduced reproduction.⁵ Mental retardation, if present, is an independent factor affecting reproductive fitness. The early developmental delay, or slow normal development, observed in the father of our family faded during childhood enabling normal adult life and transmission of the mutated *NSD1* to the next generation. According to our data, the 896delC mutation of the *NSD1* gene does not have a major effect on fertility.

ACKNOWLEDGEMENTS

We thank Dr T C Cole and Dr Irma Järvelä for helpful discussions and Ms Kazumi Miyazaki, Naoko Takaki, Naoko Yanai, and Yasuko Noguchi for their technical assistance. This work was supported in part by a grant, CREST, from the Japan Science and Technology Corporation (JST) (NK, NM), Helsinki University Hospital Funds (PH), and the Foundation for Pediatric Research in Finland (PH). The authors also thank the family for their kind cooperation.

Authors' affiliations

P Höglund, Department of Paediatrics, University of Helsinki, Helsinki, Finland
P Höglund, M Somer, Department of Clinical Genetics, University of

Helsinki, Helsinki, Finland

N Kurotaki, N Miyake, N Matsumoto, Department of Human Genetics, Nagasaki University School of Medicine, Nagasaki, Japan
N Kurotaki, N Miyake, N Matsumoto, CREST, Science and Technology Corporation, Kawaguchi, Japan

S Kytölä, Medix Laboratories Ltd, Espoo, Finland and Institute of Medical Technology, University of Tampere and Tampere University Hospital, Finland

Correspondence to: Dr P Höglund, Hospital for Children and Adolescents, P O Box 281 (Stenbäckinkatu 11), 00029 HUS, Finland; Pia.Hoglund@Hus.Fi or Pia.Hoglund@Helsinki.Fi

REFERENCES

- Sotos JF, Dodge PR, Muirhead D, Crawford JF, Talbot NB. Cerebral gigantism in childhood: a syndrome of excessively rapid growth with acromegalic features and nonprogressive neurologic disorder. *N Engl J Med* 1964;**271**:109-16.
- Cole TRP, Hughes HE. Sotos syndrome. *J Med Genet* 1990;**27**:571-6.
- Wit JM, Beemer FA, Barth PG, Oorthuys JW, Dijkstra PF, Van den Brande JL, Leschot NJ. Cerebral gigantism (Sotos syndrome). Compiled data of 22 cases. Analysis of clinical features, growth and plasma somatomedin. *Eur J Pediatr* 1985;**144**:131-40.
- Agwu JC, Shaw NJ, Kirk J, Chapman S, Ravine D, Cole TR. Growth in Sotos syndrome. *Arch Dis Child* 1999;**80**:339-42.
- Cole TRP, Hughes HE. Sotos syndrome: a study of the diagnostic criteria and natural history. *J Med Genet* 1994;**31**:20-32.
- Opitz JM, Weaver DW, Reynolds JF Jr. The syndromes of Sotos and Weaver: reports and review. *Am J Med Genet* 1998;**79**:294-304.
- Schaefer GB, Bodensteiner JB, Buehler BA, Lin A, Cole TR. The neuroimaging findings in Sotos syndrome. *Am J Med Genet* 1997;**68**:462-5.
- Cole TRP. Sotos syndrome. In: *Management of genetic syndromes*. New York: Wiley-Liss, 2001:389-404.
- Mouridsen SE, Hansen MB. Neuropsychiatric aspects of Sotos syndrome. A review and two case illustrations. *Eur Child Adolesc Psych* 2002;**11**:43-8.
- Hansen FJ, Friis B. Familial occurrence in cerebral gigantism: Sotos' syndrome. *Acta Paediatr Scand* 1976;**65**:387-9.
- Townes PL, Scheined AP. Cerebral gigantism (Sotos' syndrome): Evidence for recessive inheritance. *Pediatr Res* 1973;**7**:349.
- Zonana J, Sotos JF, Romshe CA, Fisher DA, Elders MJ, Rimoin DL. Dominant inheritance of cerebral gigantism. *J Pediatr* 1977;**91**:251-6.
- Goymy P, Malpuech G, Gannat M, Menet G. Gigantism cerebral familial: une nouvelle observation à transmission autosomique dominante? *Pediatrie* 1979;**34**:249-56.
- Boman H, Nilsson D. Sotos syndrome in two brothers. *Clin Genet* 1980;**18**:421-7.
- Smith A, Farrar JR, Silink M, Judzewitsch R. Dominant Sotos's syndrome. *Arch Dis Child* 1980;**55**:579.
- Bale AE, Drum MA, Parry DM, Mulvihill JJ. Familial Sotos syndrome (cerebral gigantism): craniofacial and psychological characteristics. *Am J Med Genet* 1985;**20**:613-24.
- Winship IM. Sotos syndrome - autosomal dominant inheritance substantiated. *Clin Genet* 1985;**28**:243-6.
- Kaneko H, Tsukahara M, Tachibana H, Kurashige H, Kuwano A, Kajii T. Congenital heart defects in Sotos sequence. *Am J Med Genet* 1987;**26**:569-76.
- Scarpa P, Faggioli R, Voghenzi A. Familial Sotos syndrome: longitudinal study of two additional cases. *Genet Couns* 1994;**5**:155-9.
- Maroun C, Schmerler S, Hutcheon RG. Child with Sotos phenotype and a 5:15 translocation. *Am J Med Genet* 1994;**50**:291-3.
- Imaizumi K, Kimura J, Matsuo M, Kurosawa K, Masuno M, Niikawa N, Kuroki Y. Sotos syndrome associated with a de novo balanced reciprocal translocation t(5;8)(q35;q24.1). *Am J Med Genet* 2002;**107**:58-60.
- Kurotaki N, Harada N, Yoshiura K, Sugano S, Niikawa N, Matsumoto N. Molecular characterization of *NSD1*, a human homologue of the mouse *Nsd1* gene. *Gene* 2001;**279**:197-204.
- Kurotaki N, Imaizumi K, Harada N, Masuno M, Kondoh T, Nagai T, Ohashi H, Naritomi K, Tsukahara M, Makita Y, Sugimoto T, Sonoda T, Hasegawa T, Chinen Y, Tamita Ha HA, Kinoshita A, Mizuguchi T, Yoshiura Ki K, Ohta T, Kishino T, Fukushima Y, Niikawa N, Matsumoto N.. Haploinsufficiency of *NSD1* causes Sotos syndrome. *Nat Genet* 2002;**30**:365-6.
- Matsumoto N, Leventer RJ, Kuc JA, Mewborn SK, Dudlicek LL, Ramocki MB, Pilz DT, Mills PL, Das S, Ross ME, Ledbetter DH, Dobyns WB. Mutation analysis of the *DCX* gene and genotype/phenotype correlation in subcortical band heterotopia. *Eur J Hum Genet* 2001;**9**:5-12.
- Huang N, vom Baur E, Garnier JM, lerouge T, Vonesch JL, Lutz Y, Chambon P, Losson R. Two distinct nuclear receptor interaction domains in *NSD1*, a novel SET protein that exhibits characteristics of both corepressors and coactivators. *EMBO J* 1998;**17**:3398-412.
- Inoue K, Kato S, Numaga J, Sakurai M, Ohara C, Ouchi M, Iwata T, Kawashima H. Optic disk pallor and retinal atrophy in Sotos syndrome (cerebral gigantism). *Am J Ophthalmol* 2000;**130**:853-4.
- Yen MT, Gedde SJ, Flynn JT. Unilateral glaucoma in Sotos syndrome (cerebral gigantism). *Am J Ophthalmol* 2000;**130**:851-3.