

ELECTRONIC LETTER

Partial deletion of 4p and 4q in a fetus with ring chromosome 4: phenotype and molecular mapping of the breakpoints

A Kocks, S Endele, R Heller, B Schröder, H-J Schäfer, C Städtler, M Makrigeorgi-Butera, A Winterpacht

J Med Genet 2002;39:e23 (<http://www.jmedgenet.com/cgi/content/full/39/5/e23>)

Molecular breakpoint mapping in phenotypically well defined patients with structurally rearranged chromosomes is an established strategy to narrow down the physical interval for genes that are critical in the formation of the phenotype. In patients with balanced translocations, the breakpoints themselves are likely to contain the disease associated gene, whereas in patients with segmental aneuploidy the deleted or duplicated chromosome fragments are the candidate regions for one or more dosage regulated genes. The phenotypes in patients with segmental aneuploidy are syndromes which often vary in their clinical manifestation depending on the size of the chromosomal region involved. Two relatively frequent syndromes involve chromosome 4 and may coincide in the same person in the form of a ring chromosome 4. Formation of a ring chromosome 4, r(4), often involves loss of 4p and 4q telomeres and of more proximal regions on either or both chromosome arms. Several r(4) chromosomes have been reported in patients who had a combination of features typical of the deletion 4p- and deletion 4q- syndromes.¹⁻³

Deletions of the distal short arm of one chromosome 4 involving parts of 4p16 cause the Wolf-Hirschhorn (4p-) syndrome (WHS, OMIM 194190), a complex malformation syndrome characterised by low birth weight, severe psychomotor delay, microcephaly, typical facial features ("Greek warrior helmet" appearance), midline fusion defects, heart defects, and other abnormalities. Most likely, WHS is a contiguous gene syndrome caused by the deletion of more than one gene. Several attempts have been made to identify the genes involved by genotype-phenotype mapping.⁴⁻⁶ The minimal critical region for some of the WHS features (typical facial appearance, mild mental and growth retardation, and congenital hypotonia) has been mapped to a 165 kb region in 4p16.3 (WHSCR).^{7,8} Other features of WHS patients, like midline fusion defects and heart defects, clearly map outside the WHSCR.^{5,6} Recently, a novel small interstitial deletion of 191 kb containing the WHSCR has been described.⁸ However, as opposed to what would be expected for a deletion encompassing the WHSCR, the patient only had a mild, not entirely typical WHS phenotype. Despite efforts to solve the molecular basis of the syndrome,⁷⁻¹² only little is known about the pathological and neuropathological changes in this disorder or about the changes in fetal development. Consequently, there is only a limited number of case reports giving necropsy findings in WHS.¹³⁻¹⁷

Deletions of chromosome regions 4q31, 4q32, and 4q33-4qter have also been recognised as a distinctive malformation syndrome (deletion 4q syndrome), including variable mental and growth deficiency, cleft palate, limb anomalies, and cardiac and genitourinary defects.¹⁸⁻²⁰ More distal 4q deletions involving bands q34-q35 have been found in patients presenting with less characteristic dysmorphism and less severe mental retardation.^{3,20} Since many of these patients have

abnormalities of the limbs, including ectrodactyly, a gene associated with limb deficiency was tentatively assigned to chromosome 4q33.^{2,21,22} Necropsy findings were reported in a patient with 4q- (breakpoint in 4q31).¹⁸ No internal congenital malformations were found at necropsy.

Here, we present the clinical, histopathological, and molecular findings in a fetus with a mosaic ring chromosome 4 (45,XX,-4/46,XX,r(4)). This report represents not only the first molecular characterisation of chromosomal breakpoints in a ring chromosome 4 with a distal 4q deletion, but also one

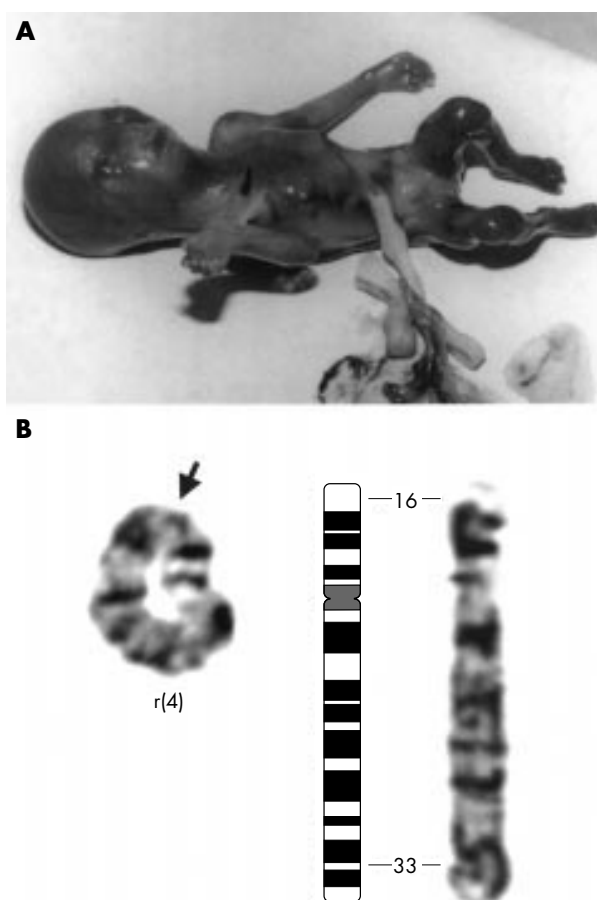


Figure 1 (A) A female fetus (21st week) with ring chromosome 4. (B) G banded normal chromosome 4 (right) and ring chromosome 4 (left) of the fetus. Chromosomes are at the 550 band resolution. Cytogenetically determined putative breakpoints at 4p16 and 4q33 are indicated.

Table 1 PAC/BAC clones for FISH. The chromosomal localisation and the relative order of the clones is deduced from the Draft Human Genome Sequence/Map Viewer (<http://www.ncbi.nlm.nih.gov/>) from the NCBI FISH clone map (cytogenetic) and from our own mapping data.¹² Clones 1 and 2 were isolated from a PAC library obtained by P de Jong (Buffalo, USA) and clones 3–10 were obtained from the German Resource Centre (RZPD, Berlin; BAC library RPCIB753)

No	PAC/BAC clone	Containing markers	Chromosomal localisation (Map Viewer) (Mb)	Cytogenetic (FISH)
1	PJ-129P5	D4S142	Ambiguous	4p16.3
2	PJ-111E4	D4S166	4.2	4p16.3 (WHSCR)
3	RP11-478A6	D4S1233	4.7	4p16
4	RP11-7A6	D4S1276, MSX1	7.1	4p16
5	RP11-81L15	D4S1511	16.5	4p15
6	RP11-119N7	D4S863	27.5	4p14-15.1
7	RP11-648O9	D4S2677	112.1	4q32-33
8	RP11-4D13	D4S575	154.8	4q32 ?
9	RP11-79K2	SHGC-84154	177.4	4q34
10	RP11-274E20	D4S3128	184.8	4q35 (RP11-228F3)

of the very rare histopathological investigations of second trimester fetuses with 4p and 4q deletions.

CASE REPORT

Conspicuous ultrasound findings in this pregnancy of a 27 year old primigravida first occurred in the 17th week and included intrauterine growth retardation, increased nuchal translucency (NT=5.6 mm), and a suspected cardiac malformation. Another scan in the 21st week shortly before termination of pregnancy showed further abnormalities, namely cleft lip, left sided diaphragmatic hernia with cardiac dextroposition, a single umbilical artery, and pathological uterine blood flow patterns, which were considered to be indicative of a compromised placental function and potential development of pre-eclampsia. In view of the ultrasound findings and the prenatal cytogenetic diagnosis of a mosaic r(4), the mother opted for termination of pregnancy and consented to necropsy (fig 1A). The above malformations were confirmed. Additional findings were a high nasal bridge with hypertelorism and a prominent glabella, a bilateral cleft lip and palate, a short philtrum, a complex cardiac defect (transposition of the great arteries with double outlet right ventricle), thymic hypoplasia, and aplasia of the gall bladder.

The macroscopic architecture of the brain (35.5 g post fixation) was normal. A thorough neuropathological examination included immunohistochemical staining for markers of neuronal and glial differentiation (neurofilament, glial fibre acidic protein, and CD68 antibodies) in addition to conventional haematoxylin-eosin staining of sections containing corpus callosum, periventricular germinal cell layer, cerebral cortex, thalamus and basal ganglia, dorsolateral geniculate corpus, brain stem with nuclei of cranial nerves III (oculomotorius) and XII (hypoglossus), as well as nucleus ambiguus and inferior olivary nucleus, cerebellar cortex, and dentate nucleus. All anatomical structures with the exception of the corpus callosum, which was not fully preserved and could therefore not be reliably assessed, showed normal age related organisation and differentiation when compared to sections from normal fetuses of a similar age (20 and 22 weeks of gestation) (data not shown).

Analysis of 23 GTG banded metaphases from lymphocytes showed monosomy of chromosome 4 in 56% of the cells. In 44%, one chromosome 4 was replaced by a ring chromosome with breakpoints at 4p16 and 4q33-34 (45,XX,-4/46,XX,r(4)(p1?6;q3?3)) (fig 1B) thus confirming the prenatal diagnosis. In order to relate the cytogenetic breakpoints to the

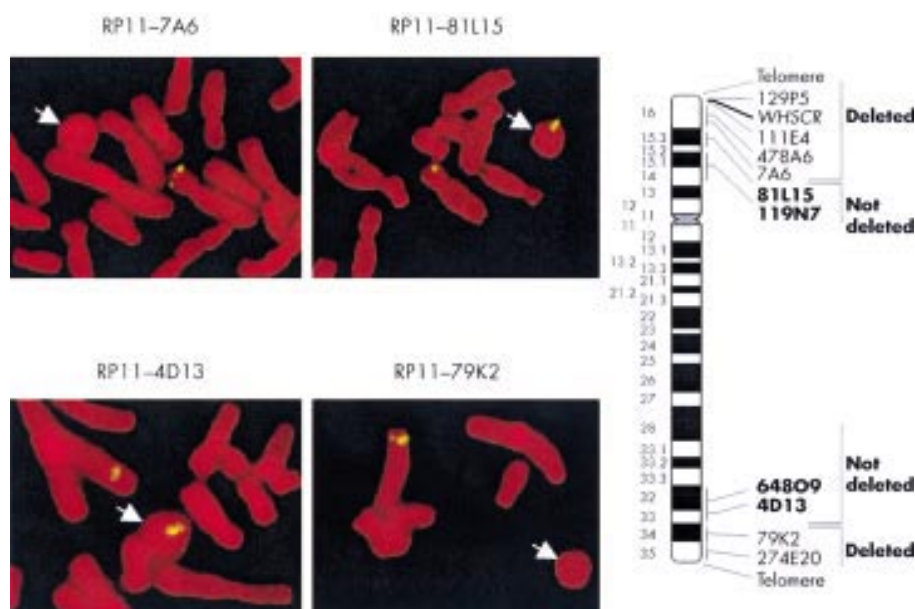


Figure 2 Results of FISH studies on metaphase cells with ring chromosome 4. PAC/BAC clones used as hybridisation probes for FISH are shown on the right (see also table 1). Probes deleted on the ring chromosome are indicated.

physical map of chromosome 4 as available from the human genome draft sequence, we isolated a set of chromosome 4 specific PAC/BAC clones from various regions of the distal long and short arms. Clones were selected from the FISH clone map of the NCBI (<http://www.ncbi.nlm.nih.gov>) or contained mapped genes. Clones were checked by PCR and direct DNA sequencing. In total, 10 PAC clones (table 1) were used for FISH. The results are summarised in fig 2. The breakpoints were located in the intervals between clones RP11-7A6 and RP11-81L15 on the short arm and between clones RP11-4D13 and RP11-79K2 on the long arm of chromosome 4 (table 1). Hybridisation with chromosome 4p and 4q specific telomeric probes showed that both telomeres are lost (fig 2). Therefore the ring most likely arose as a result of breakage in both arms of the chromosome, with subsequent fusion of the ends and loss of the distal segments.

DISCUSSION

This case represents the only case out of the 11 previously described cases of ring chromosome 4 and 20 cases of distal 4q deletion to have breakpoints defined at the molecular level. According to the Draft Human Genome (Map Viewer), we located the breakpoint on the long arm of chromosome 4 in a 22 Mb region between clones RP11-4D13 and RP11-79K2. Based on the published genomic localisation of the two clones and the markers, we assigned the breakpoint between 4q33 and q34. Terminal deletions with breakpoints in 4q33 cause the 4q- (4q terminal deletion) syndrome.²⁰ Keeling *et al*²⁰ proposed that the critical region for this syndrome is 4q33, and that the main features of this syndrome are the Robin sequence, typical facial features, developmental delay, limb abnormalities, and variable cardiac defects. *HAND2*, a basic HLH transcription factor located in 4q33 proximal to RP1179K2 (at ~174 Mb), is an interesting candidate gene for the cardiac defects. Srivastava *et al*²³ showed that the gene is required for formation of the right ventricle of the heart and the aortic arch arteries. Recently, Tsai *et al*²⁴ described a patient with a congenital heart defect and a 4q34.2-qter deletion, indicating that a gene responsible for heart development is also located in this more distal region. Limb deficiencies are also part of the 4q terminal deletion syndrome²⁰⁻²⁴ and are present in about 30-60% of the patients with 4q33-qter deletions. The major limb anomalies are uni- and bilateral ulnar ray defects and minor anomalies including fifth digit clinodactyly of the hands and feet, hypoplastic nails, and overlapping toes.²⁰ A gene involved in limb deficiencies may therefore be assigned to 4q33.²⁻²⁰ The fetus described here had no signs of limb deficiency which suggests that the gene for limb development may be located in 4q33, proximal to RP11-79K2.

According to the current data from the Draft Human Genome (Map Viewer), the breakpoint on the short arm of chromosome 4 is located in a 9.4 Mb interval flanked by the clones RP11-7A6 and RP11-81L15. Clones were mapped by FISH to 4p16 and 4p15, respectively (NCBI FISH clone map). RP11-7A6 contains the *MSX1* gene (FISH map position 4p16.1-16.3), which was used by Zollino *et al*⁶ as a 4p16.1 specific FISH probe for phenotype-genotype mapping of WHS patients. Therefore, the breakpoint on the short arm is located in chromosome region 4p16.1, proximal to *MSX1*, and indicates deletion of the whole distal portion of the short arm including the complete WHS critical region in the fetus. Similar deletions have been described in a number of patients with Wolf-Hirschhorn syndrome with the full spectrum of clinical changes, including heart and renal abnormalities.⁴⁻⁶ The size of the deletion is comparable to the deletions described in six patients with WHS by Zollino *et al*,⁶ which were characterised by a terminal deletion including *MSX1*. In addition to the main features of WHS, all six patients had midline fusion defects, three patients had heart defects, one had pulmonary stenosis,

and four of the six patients presented with renal abnormalities (renal hypoplasia, dilatation of the renal pelvis).

The neuropathological examination in our case was prompted by previous reports that had found recurrent developmental and structural CNS abnormalities in aborted fetuses or dead neonates and young children with WHS. This neuropathological constellation includes shortening of the H2 area of Ammons' horn, defective development of the pyramids, and abnormal cerebellar gyration.¹³ Further features in WHS necropsy cases were generalised brain hypoplasia (4/10 cases), abnormal gyration of the cerebral cortex with heterotopia of neurones (5/10 cases), hypoplasia and/or fibrous disorganisation of the corpus callosum (5/10 cases), and dysplasia of several nuclei, such as the dorsolateral geniculate nuclei and the dentate nuclei (3/5 cases).¹⁴⁻¹⁷ Some of these features, namely hypoplasia of the cerebellar cortex and defects of lobulation, were also described in a recently published mutant mouse that is claimed to be an animal model for WHS.²⁵ Strikingly, the examination of the histomorphology and of the immunocytochemical parameters of cellular differentiation did not show any visible abnormality in our case. Subtle anomalies in the fetal brain, such as regionally disturbed gyration, may easily be overlooked at the relatively early gestational age of 21 weeks. In addition, the corpus callosum could not be examined properly in our case owing to preparation artefacts. However, the comparison with similar to identical sections from fetuses of comparable gestational age with no sign of WHS did not suggest any of the above mentioned WHS associated CNS findings.

We propose that the typical WHS pathological changes of the CNS are either not detectable by standard methods or are not present around the 21st week of gestation. Alternatively, CNS abnormalities may not occur at all in a subgroup of affected patients owing to phenotypic variability of the WHS. This latter explanation is supported by at least two previous reports where a postmortem examination of WHS infants did not show any significant CNS pathology.¹⁵⁻¹⁶

Detailed molecular mapping of 4p- and 4q- deletion cases on the basis of the continuously improving human genome sequence in comparison with a thorough phenotypic characterisation of affected patients should help to track down individual candidate genes for specific features of deletion syndromes. Moreover, we propose that a thorough work up of human aborted fetuses with these deletions is an important strategy to complement data obtained from molecular studies and that it helps to understand the pathological consequences of changes in gene expression levels in these contiguous gene syndromes with variable phenotypic expression.

ACKNOWLEDGEMENTS

We wish to thank Ms K v Hadeln for skilful technical assistance in cell culture. The prenatal diagnosis in the case presented here was made by Dr E Kaminsky (Hamburg). The study was supported by a grant (SPB545) from the Deutsche Forschungsgemeinschaft (to Andreas Winterpacht).

.....

Authors' affiliations

A Kocks, S Endele, R Heller, B Schröder, A Winterpacht, Institute of Human Genetics, University Hospital Hamburg-Eppendorf, Butenfeld 42, D-22529 Hamburg, Germany

H-J Schäfer, C Städtler, Institute of Pathology, University Hospital Hamburg-Eppendorf, Martinistrasse 52, D-20251 Hamburg, Germany

M Makrigeorgi-Butera, Department of Neuropathology, Institute of Pathology, University Hospital Hamburg-Eppendorf, Martinistrasse 52, D-20251 Hamburg, Germany

Correspondence to: Professor A Winterpacht, Institute of Human Genetics, University Hospital Hamburg-Eppendorf, Butenfeld 42, D22529 Hamburg, Germany; winterpacht@uke.uni-hamburg.de

REFERENCES

- 1 Perez-Castillo A, Abrisqueta JA. Ring chromosome 4 and Wolf syndrome. *Hum Genet* 1977;**37**:87-91.

- 2 **Lurie IW**. Further study of genetic interactions: loss of short arm material in patients with ring chromosome 4 changes developmental pattern of del(4)(q33). *Am J Med Genet* 1995;**56**:308-11.
- 3 **Calabrese G**, Giannotti A, Mingarelli R, Di Gilio MC, Piemontese MR, Palka G. Two newborns with chromosome 4 imbalances: deletion 4q33-q35 and ring r(4)(pterq35.2-pter). *Clin Genet* 1997;**51**:264-7.
- 4 **Estabrooks LL**, Rao KW, Driscoll DA, Crandall BF, Dean JC, Ikonen E, Korf B, Aylsworth AS. Preliminary phenotypic map of chromosome 4p16 based on 4p deletions. *Am J Med Genet* 1995;**57**:581-6.
- 5 **Wieczorek D**, Krause M, Majewski F, Albrecht B, Horn D, Riess O, Gillissen-Kaesbach G. Effect of the size of the deletion and clinical manifestation in Wolf-Hirschhorn syndrome: analysis of 13 patients with a de novo deletion. *Eur J Hum Genet* 2000;**8**:519-26.
- 6 **Zollino M**, Di Stefano C, Zampino G, Mastroiacovo P, Wright TJ, Sorge G, Selicorni A, Tenconi R, Zappala A, Battaglia A, Di Rocco M, Palka G, Pallotta R, Altherr MR, Neri G. Genotype-phenotype correlations and clinical diagnostic criteria in Wolf-Hirschhorn syndrome. *Am J Med Genet* 2000;**94**:254-61.
- 7 **Wright TJ**, Ricke DO, Denison K, Abmayr S, Cotter PD, Hirschhorn K, Keinanen M, McDonald-McGinn D, Somer M, Spinner N, Yang-Feng T, Zackai E, Altherr MR. A transcript map of the newly defined 165 kb Wolf-Hirschhorn syndrome critical region. *Hum Mol Genet* 1997;**6**:317-24.
- 8 **Rauch A**, Schellmoser S, Kraus C, Dorr HG, Trautmann U, Altherr MR, Pfeiffer RA, Reis A. First known microdeletion within the Wolf-Hirschhorn syndrome critical region refines genotype-phenotype correlation. *Am J Med Genet* 2001;**99**:338-42.
- 9 **Stec I**, Wright TJ, van Ommen GJ, de Boer PA, van Haeringen A, Moorman AF, Altherr MR, den Dunnen JT. WHSC1, a 90 kb SET domain-containing gene, expressed in early development and homologous to a Drosophila dysmorphia gene maps in the Wolf-Hirschhorn syndrome critical region and is fused to IgH in t(4;14) multiple myeloma. *Hum Mol Genet* 1998;**7**:1071-82.
- 10 **Wright TJ**, Costa JL, Naranjo C, Francis-West P, Altherr MR. Comparative analysis of a novel gene from the Wolf-Hirschhorn/Pitt-Rogers-Danks syndrome critical region. *Genomics* 1999;**59**:203-12.
- 11 **Endele S**, Fuhry M, Pak SJ, Zabel BU, Winterpacht A. LETM1, a novel gene encoding a putative EF-hand Ca(2+)-binding protein, flanks the Wolf-Hirschhorn syndrome (WHS) critical region and is deleted in most WHS patients. *Genomics* 1999;**60**:218-25.
- 12 **Endele S**, Pfarr N, Schlickum S, Steglich C, Oswald M, Heller R, Zabel B, Winterpacht A. Wolf-Hirschhorn syndrome - molecular dissection of a complex phenotype by comparative sequencing and functional studies. 10th International Congress of Human Genetics, Wien, 15.19.05. *Eur J Hum Genet Suppl* 2001;**9**:252
- 13 **Lazjuk GI**, Lurie IW, Ostrowskaja TI, Kirillova IA, Nedzved MK, Cherstvoy ED, Silyaeva NF. The Wolf-Hirschhorn syndrome. II. Pathologic anatomy. *Clin Genet* 1980;**18**:6-12.
- 14 **Gottfried M**, Lavine L, Roessmann U. Neuropathological findings in Wolf-Hirschhorn (4p-) syndrome. *Acta Neuropathol* 1981;**55**:163-5.
- 15 **Gonzalez CH**, Capelozzi VL, Wajntal A. Pathologic findings in the Wolf-Hirschhorn (4p-) syndrome. *Am J Med Genet* 1981;**9**:183-7.
- 16 **Kitsiou S**, Bartsocas CS, Alexiou D, Mourtzinis D. Unusual pathologic findings in a girl with Wolf-Hirschhorn syndrome, del(4p). *Pediatr Pathol* 1986;**6**:161-5.
- 17 **Tachdjian G**, Fondacci C, Tapia S, Hutten Y, Blot P, Nessmann C. The Wolf-Hirschhorn syndrome in fetuses. *Clin Genet* 1992;**42**:281-7.
- 18 **Townes PL**, White M, Di Marzo SV. 4q- syndrome. *Am J Dis Child* 1979;**133**:383-5.
- 19 **Robertson SP**, O'Day K, Bankier A. The 4q- syndrome: delineation of the minimal critical region to within band 4q31. *Clin Genet* 1998;**53**:70-3.
- 20 **Keeling SL**, Lee-Jones L, Thompson P. Interstitial deletion 4q32-34 with ulnar deficiency: 4q33 may be the critical region in 4q terminal deletion syndrome. *Am J Med Genet* 2001;**99**:94-8.
- 21 **Tomkins DJ**, Hunter AG, Uchida IA, Roberts MH. Two children with deletion of the long arm of chromosome 4 with breakpoint at band q33. *Clin Genet* 1982;**22**:348-55.
- 22 **Menko FH**, Madan K, Baart JA, Beukenhorst HL. Robin sequence and a deficiency of the left forearm in a girl with a deletion of chromosome 4q33-qter. *Am J Med Genet* 1992;**44**:696-8.
- 23 **Srivastava D**, Thomas T, Lin Q, Kirby ML, Brown D, Olson EN. Regulation of cardiac mesodermal and neural crest development by the bHLH transcription factor, dHAND. *Nat Genet* 1997;**16**:154-0.
- 24 **Tsai CH**, Van Dyke DL, Feldman GL. Child with velocardiofacial syndrome and del (4)(q34.2): another critical region associated with a velocardiofacial syndrome-like phenotype. *Am J Med Genet* 1999;**82**:336-9.
- 25 **Naf D**, Wilson LA, Bergstrom RA, Smith RS, Goodwin NC, Verkerk A, van Ommen GJ, Ackerman SL, Frankel WN, Schimenti JC. Mouse models for the Wolf-Hirschhorn deletion syndrome. *Hum Mol Genet* 2001;**10**:91-8.