

## REVIEW ARTICLE

## Coffin-Lowry syndrome: clinical and molecular features

A Hanauer, I D Young

J Med Genet 2002;39:705-713

The Coffin-Lowry syndrome (CLS) is a rare X linked disorder in which affected males show severe mental retardation with characteristic dysmorphism, most notably affecting the face and hands. The typical facial features consist of a prominent forehead, hypertelorism, a flat nasal bridge, downward sloping palpebral fissures, and a wide mouth with full lips. Mild progression in facial coarsening occurs during childhood and adult life. The hands are broad with soft, stubby, tapering fingers. Other clinical findings include short stature (95%), a pectus deformity (80%), a kyphosis and/or scoliosis (80%), mitral valve dysfunction, and sensorineural hearing loss. The causal gene, *RSK2*, was identified in 1996 and contains 22 exons which encode a protein of 740 amino acids. Over 75 distinct pathogenic mutations have been identified in 250 unrelated CLS patients.

female) published cases.<sup>1-3 9-19</sup> In many of these reports full clinical details were not provided. The information drawn up in table 1 has been gathered from clinical case descriptions and clinical photographs when available. It should be noted that this approach to clinical delineation introduces a degree of bias, as only those cases conforming to early clinical descriptions have been diagnosed as Coffin-Lowry syndrome and published accordingly. The two recent reports of much milder phenotypes with proven pathogenic mutations in *RSK2* emphasise the potential wide range of clinical involvement.<sup>7 8</sup>

**Growth**

Parameters at birth are usually within the normal range although a broad, high forehead may give a false impression of macrocephaly. Delay in closure of the anterior fontanelle is often noted. Short stature becomes apparent in boys in early childhood with the average height in reported adult males being 143 cm (range 115-158 cm). The shortening of stature is often exacerbated by a severe kyphoscoliosis. Female heterozygotes are less severely affected with almost 50% lying above the 10th centile.

**Facial features**

In boys these are usually very characteristic and consistent with a rapid gestalt diagnosis (fig 1). Prominence of the forehead is present from early infancy with true orbital hypertelorism and narrow, downward slanting palpebral fissures. The nasal bridge is flat in childhood with anteversion of the nares and thickening of both the alae nasi and the nasal septum. Midface hypoplasia contrasts with prominence of the jaw. The mouth is long with full everted lips. Typical orodontal findings include a high, narrow palate, malocclusion, hypodontia, peg shaped incisors, and a midline lingual furrow. The ears appear large and prominent. This typical facial appearance is usually apparent by the second year of life and shows progressive coarsening thereafter with increasing prominence of the glabella and protrusion of the lips.

The facial characteristics in females are much more variable with some obligate heterozygotes having no obvious distinguishing facial features. Once again it should be emphasised that the incidence figures given in table 1 are almost certainly biased in favour of more severely affected females, as many mildly affected or unaffected women will not be correctly diagnosed. There is also an anecdotal impression, as yet unsubstantiated, that the degree of facial dysmorphism correlates with the level of intellectual impairment. Some women show marked coarsening with hypertelorism, downward sloping fissures,

CLS (MIM 303600) is a well defined clinical entity classically associated with severe mental retardation and characteristic facial features in males, with females being much more mildly and variably affected. The condition was first reported in two separate families by Coffin *et al*<sup>1</sup> in 1966 and by Lowry *et al*<sup>2</sup> in 1971. Based on the clinical features in three new families, Temtamy *et al*<sup>3</sup> astutely concluded that all of these families were manifesting the same condition for which the eponymous title "Coffin-Lowry" syndrome was proposed.

Confirmation of the suspected X linked mode of inheritance was forthcoming with the mapping of the disease locus to Xp22.2 by multipoint linkage analysis by Hanauer *et al*<sup>4</sup> in 1988, with the subsequent isolation of the causal gene, *RSK2*, in 1996.<sup>5</sup> *RSK2* encodes a growth factor regulated serine-threonine protein kinase which acts at the distal end of the *RAS* signalling cascade. To date, well over 100 affected subjects have been reported from all ethnic groups and over 75 distinct disease associated *RSK2* mutations have been identified.<sup>6</sup> These are usually associated with severe disease but a mild phenotype has been recognised<sup>7</sup> and in one family an *RSK2* mutation results in only mild mental retardation with no physical stigmata.<sup>8</sup>

This review provides an overview of the clinical features seen in CLS together with details of the causal gene, *RSK2*, its protein product, and the spectrum of mutations identified to date.

**CLINICAL FEATURES**

The clinical features are summarised in table 1, which is based on review of 77 (42 male and 35

See end of article for authors' affiliations

Correspondence to:  
Professor I D Young,  
Department of Clinical  
Genetics, Leicester Royal  
Infirmary, Leicester  
LE1 5WW, UK;  
iandyong@hotmail.com

**Table 1** Clinical features of Coffin-Lowry syndrome (based on patients reported in references 1–3 and 9–19)

	Males	Females
Growth and development		
Stature		
<3rd centile	37/39	11/24
<10th centile	2/39	4/24
Retardation		
Severe	41/41	5/34
Mild	–	23/34
Normal IQ	–	6/34
Dysmorphism		
Prominent forehead/coarse facies	37/37	26/29
Hypertelorism	42/42	14/22
Downward slanting palpebral fissures	35/40	9/17
Broad nose/thick septum	34/37	20/23
Full everted lips/wide mouth	40/42	22/28
Hypodontia	19/22	3/13
Pectus excavatum/carinatum	26/32	5/17
Kyphosis/scoliosis	30/38	6/23
Soft, stubby, tapering fingers	42/42	34/35
Hypothenar crease	20/22	14/16

full cheeks, and everted, “pouting” lips, whereas others show only subtle involvement with a broad forehead and flat nasal bridge (fig 2).

### Limbs

Abnormalities in the limbs are minor but very characteristic. The hands are broad and soft with stubby, tapering, limp fingers, which are wide at the base and narrow distally (fig.3). These features are present at birth and have been observed in a stillborn male infant delivered at 30 weeks’ gestation (fig 3A). They have also been noted in almost all reported heterozygotes, including those with otherwise minimal clinical involvement (fig 4). As such, they provide an extremely useful diagnostic feature. Other reported findings include a short horizontal crease in the hypothenar region (fig 5) and fullness of the forearms owing to increased subcutaneous fat.<sup>20</sup>

### Trunk

Approximately 80% of affected males have either pectus carinatum or pectus excavatum (fig 1), whereas these are reported in only one third of affected females. In association, the sternum may be short and bifid. The progressive development of a thoracolumbar kyphosis and/or scoliosis can cause severe cardiorespiratory compromise. Other reported findings include inguinal herniae (congenital or acquired) in males and generalised obesity in females.

### RADIOLOGY

Characteristic skeletal changes are found in the skull, the spine, and the hands.<sup>21</sup> The skull shows sclerosis, which may be generalised or localised to the frontal bones, with variable enlargement or hypoplasia of the frontal sinuses. The anterior fontanelle is large and shows delayed closure. Minor coarctation of the foramen magnum has been noted with anterior placement of the occiput.<sup>10</sup> The findings in the thoracolumbar vertebrae are also variable and can include narrowing of the intervertebral spaces, irregular endplates, and anterior wedging (fig 6). Progressive changes in the vertebral bodies coupled with increased joint laxity and hypotonia predispose to the development of a kyphoscoliosis. In the hands the distal phalanges are small with a “drumstick” appearance and distal tufting. The middle phalanges may show abnormal modelling. Pseudoepiphyses may be present at the bases of the metacarpals. Bone age is delayed.

## NATURAL HISTORY AND MORBIDITY

### Mental retardation and the central nervous system

With the exception of the two male sibs recently reported,<sup>7</sup> retardation is severe in males, whereas females fall along a continuum ranging from severe retardation to relatively normal intellectual performance. Delay in speech acquisition is particularly common with most reported males having a very limited vocabulary. Ventriculomegaly has been observed in several affected males and females but its cause and natural history remain unclear. Nor is it clear whether mental retardation is truly progressive as has been suggested.<sup>3</sup> In many instances, apparent deterioration is probably a result of poor social circumstances or institutionalisation.<sup>13</sup>

Other manifestations of CNS involvement include generalised congenital hypotonia, convulsions presenting from the age of 1 year onwards, and sensorineural hearing loss which can be profound.<sup>13 15 22</sup>

### Psychiatric illness

Four families have been reported in which females with Coffin-Lowry syndrome have shown episodic or long standing psychotic behaviour. In one instance this resulted in hospitalisation for over 30 years.<sup>14</sup> In another family, one woman was described as being “shy and retiring” whereas her sister had a life long history of being “in a world of her own”.<sup>18</sup> Three other affected females in two different families have been diagnosed as having either schizophrenia<sup>15</sup> or a depressive psychosis.<sup>23</sup> Given the relative rarity of the Coffin-Lowry syndrome, these reports indicate that psychotic behaviour in affected females is a true complication rather than a spurious chance observation. Onset is usually around the age of 20 years and response to therapy is variable. This pattern of behaviour is observed only rarely in affected males,<sup>17</sup> who are usually cheerful, easy going, and friendly.

### Cardiovascular system

Cardiac involvement has been reported in a small number of affected males,<sup>1 3 13 17 24–26</sup> usually in the form of mitral valve dysfunction. This may show primary changes such as fibrosis and shortened chordae tendinae,<sup>24</sup> or become incompetent secondary to a dilated cardiomyopathy.<sup>13</sup> Thus, mitral valve incompetence and congestive cardiomyopathy may aggravate each other as in the 10 year old boy reported by Massin *et al*,<sup>26</sup> in whom recurrent left heart failure proved difficult to control.

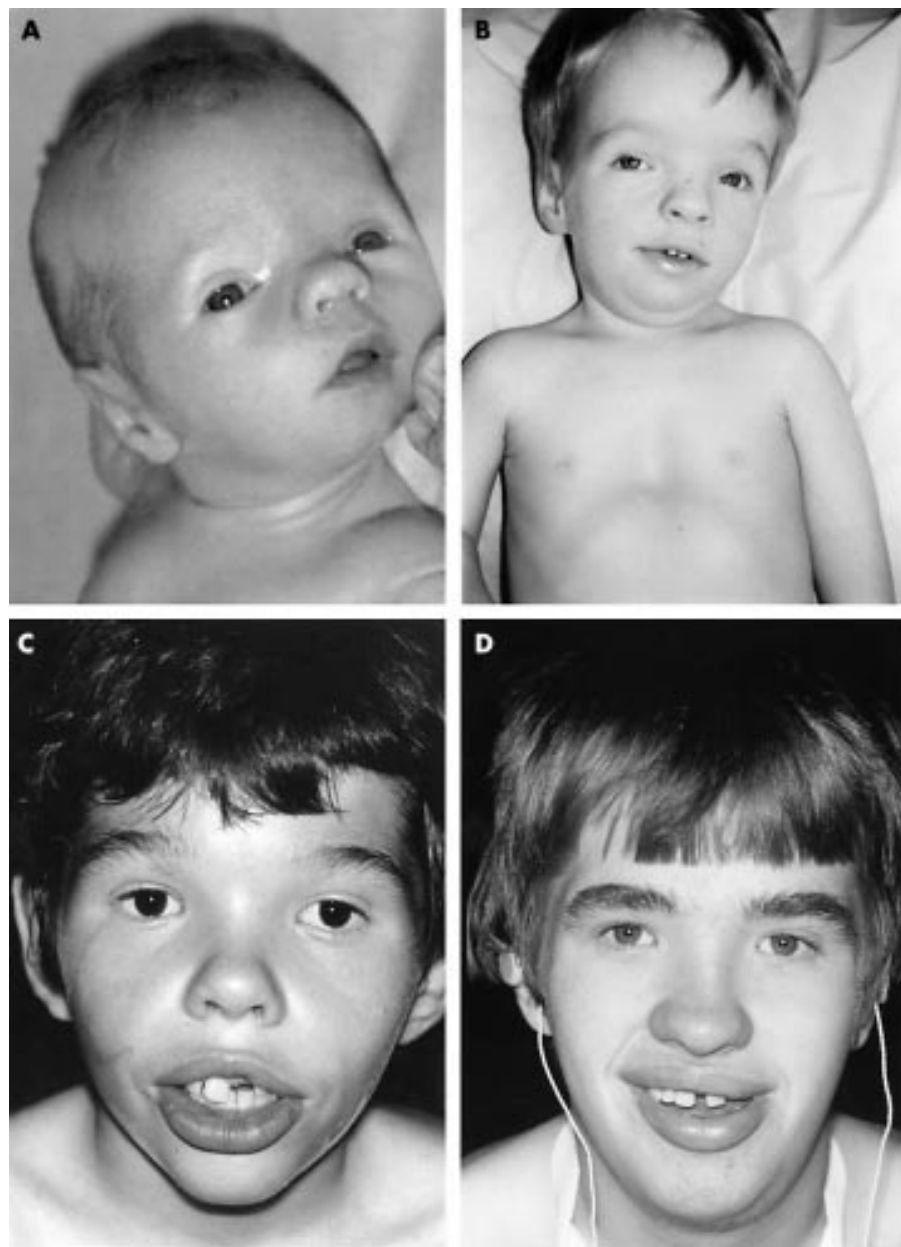
### Life expectancy

Although accurate information is not available, the paucity of reports of older affected males suggests that their life expectancy is reduced in contrast to that of females, who can survive well into old age.<sup>18</sup> Partington *et al*<sup>18</sup> described a profoundly retarded man who could still walk and run at the age of 39 years and Haspeslagh *et al*<sup>14</sup> observed a similarly affected 35 year old male. Other reports have documented severe disability in affected young adult males, including a 22 year old man who was bedridden, incontinent, and unresponsive.<sup>17</sup> The authors know of at least one pair of affected male sibs, both of whom remain active and enjoy life at the ages of 26 and 35 years.

Reported causes of death in affected males include myocarditis at the age of 32 years, pneumonia at 18 years,<sup>18</sup> and inhalation during a convulsion at 17 years.<sup>17</sup> Several males have succumbed to complications following general anaesthesia for correction of orthopaedic problems<sup>17</sup> or dental extraction.<sup>2</sup>

### Other complications

There are a large number of reports of putative rare complications occurring in one or a few cases. Many of these may well represent spurious chance observations. Examples include drop attacks<sup>27</sup> and cataplexy,<sup>28</sup> cataracts,<sup>13 19</sup> visceral neuropathy,<sup>24</sup> myelopathy,<sup>29</sup> and subclavian artery stenosis.<sup>18</sup>



**Figure 1** Facial views of four males with CLS showing typical facies at different ages.

Premature loss of the primary<sup>1</sup> or secondary<sup>22</sup> dentition may be a consequence of periodontal disease.

## MOLECULAR GENETICS

### Identification of the gene

Genetic mapping studies placed the CLS locus between DXS43 and DXS41 in Xp22.1-p22.2.<sup>4</sup> Subsequent analyses with additional markers and key recombinants refined the localisation within an interval of approximately 2 cM, between markers DXS365 and DXS7161 in Xp22.2.<sup>30-31</sup> No evidence for locus heterogeneity was found in the families analysed in these studies. A YAC contig encompassing both flanking markers was assembled and a subsequent search for transcribed sequences identified several candidate genes within the CLS candidate interval. RT-PCR screening showed mutations in one of these genes, encoding the protein kinase RSK2 (ribosomal S6 kinase), in six CLS patients. Mutations resulted in complete loss of RSK2 phosphotransferase activity.<sup>3</sup> These

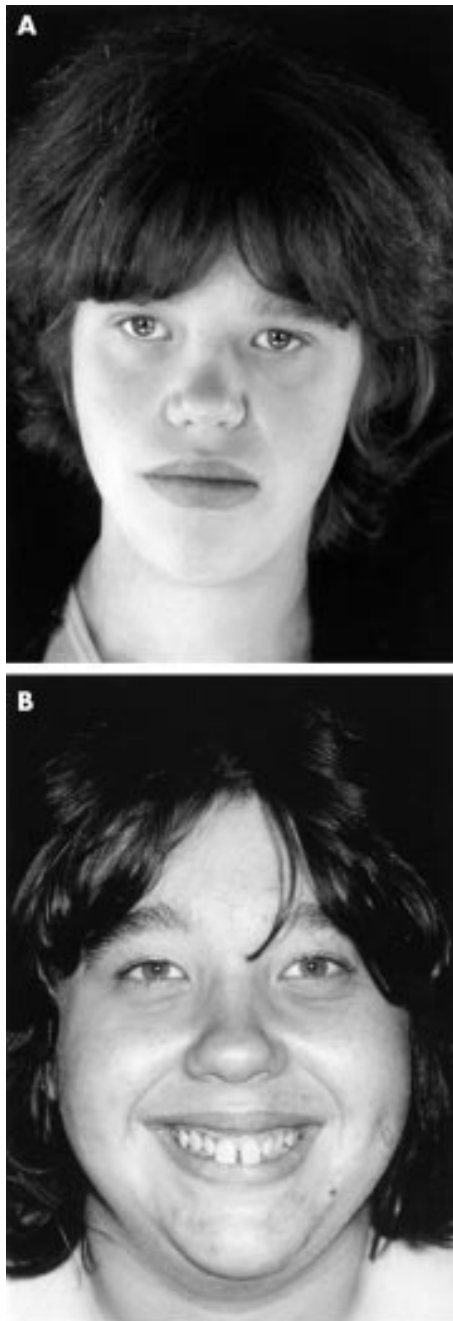data provided evidence that Coffin-Lowry syndrome was caused by loss of function mutations in *RSK2*.

### The *RSK2* gene and its protein product

PCR tests using primer sets designed from the *RSK2* cDNA sequence and performed on YAC templates, localised the whole *RSK2* gene (*RPS6KA3*) to an approximately 80 kb region within the interval flanked by markers DXS3424 and DXS1229. This analysis also indicated the direction of transcription, from centromere to telomere. The gene has an open reading frame, split into 22 exons, encoding a protein of 740 amino acids.<sup>32</sup> Two *RSK2* transcripts, of 3.5 and 8.4 kb, have been detected in all tissues and cells analysed. Sequencing of cDNAs has shown that alternative use of two different polyadenylation sites gives rise to these two transcripts (manuscript in preparation). No alternative splicing variant has been identified for the *RSK2* gene.

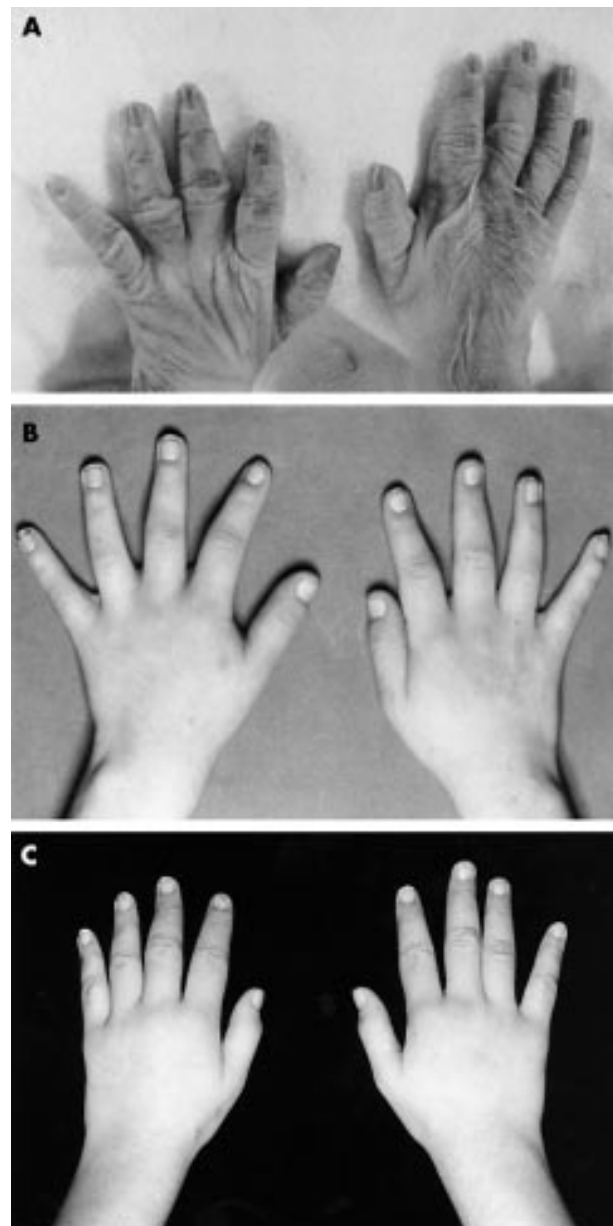
The RSK2 protein is a member of a family of serine/threonine protein kinases (known as p90<sup>sk</sup> or RSK or MAPKAP-K1 family) that act at the distal end of the mitogen





**Figure 2** Facial views of two sisters showing mild features of CLS.

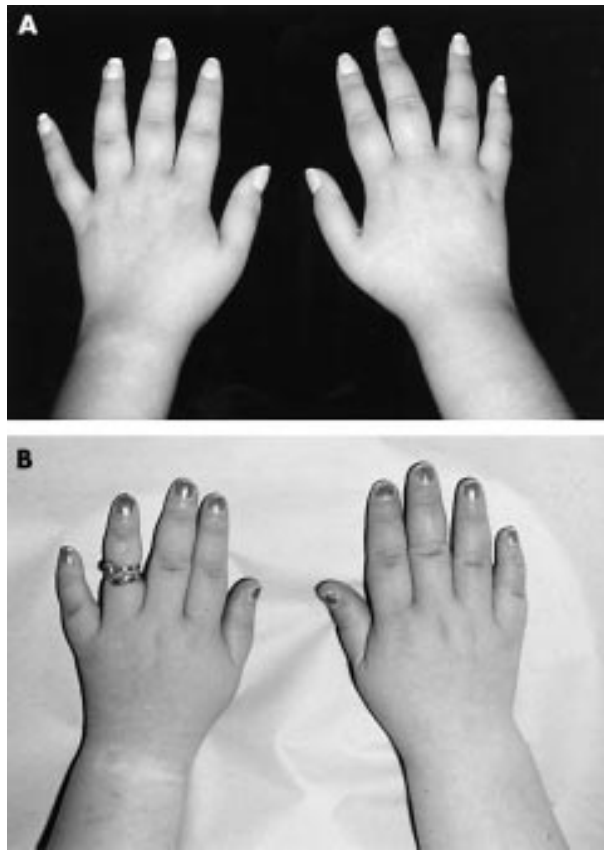
induced Ras-MAPK signalling pathway. The first RSK protein was identified in 1985 in *Xenopus laevis*, and initially characterised as a 90 kDa protein capable of phosphorylating the 40 S ribosomal subunit protein S6<sup>33</sup> (their name is because of this property). However, it has recently been shown that it is not a substrate *in vivo*.<sup>34</sup> RSK family members have subsequently been identified in many other species including *Caenorhabditis elegans*, *Drosophila melanogaster*, chicken, mouse, and humans.<sup>35-36</sup> In humans, four members have so far been characterised, RSK1, RSK2, RSK3, and RSK4, which are very similar in length (735, 740, 733, and 745 amino acid residues respectively) and show 75-80% amino acid identity. They are encoded by four distinct genes mapping to chromosomes 3 (*RSK1*), Xp22.2 (*RSK2*), 6q27 (*RSK3*), and Xq21 (*RSK4*). RSK proteins are composed of two functional kinase catalytic domains, linked together by a regulatory linker region (fig 7). Each domain is related to a different class of protein kinases.



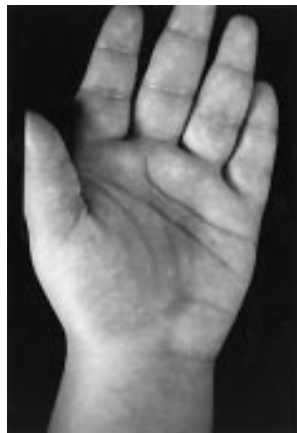**Figure 3** Views of the hands in (A) a stillborn male infant and (B, C) two boys with CLS showing broad, tapering digits.

The C-terminal kinase domain shares common structural features with the calcium/calmodulin dependent kinase (CaMK) group of kinases, whereas the N-terminal kinase domain is related to the AGC group of kinases.

Elucidation of the contribution of each catalytic domain to the RSK phosphotransferase activity has been a major focus of research in the past few years. It is now well established that the N-terminal kinase domain is responsible for phosphotransferase activity towards substrates, whereas the C-terminal kinase domain is necessary for enzymatic activation of the N-terminal kinase domain.<sup>37-40</sup> RSK phosphotransferase activity is accompanied by the phosphorylation of at least six residues, four of which have been shown to modulate kinase activity (one threonine and three serines)<sup>41</sup> (fig 7). Upon stimulation, ERK binds to a docking site located at the extreme C-terminus of *RSK*<sup>42</sup> and phosphorylates Ser369 (using human RSK2 numbering) in the linker region and Thr577 in the activation loop of the C-terminal kinase domain. These events lead to activation of the C-terminal

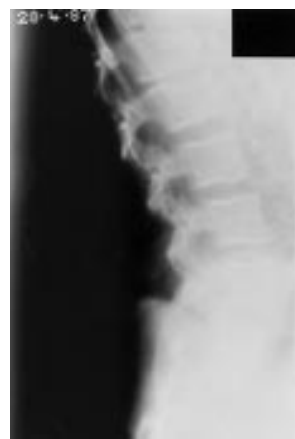

**Figure 4** Views of the hands in two adult females with mild CLS showing broad, tapering digits.



**Figure 5** View of the palm showing a hypothenar crease in a boy with CLS.

catalytic domain. How the signal is then transmitted from the C- to the N-terminal domain is a question that has recently been elucidated. Activation of the C-terminal domain by ERKs enhances the N-terminal kinase activity through a mechanism involving autophosphorylation of an additional serine residue (Ser386 in human RSK2) in the linker region.<sup>43</sup> Recent studies have shown that the 3-phosphoinositide-dependent protein kinase-1 (PDK1) is involved in the activation of the N-terminal kinase domain by phosphorylating a serine residue within the activation loop of this domain (Ser227 in human RSK2). How PDK1 and ERK cooperate to activate the N-terminal domain of RSK has also been unravelled. PDK1 is recruited to RSK at a docking site, encompassing serine386 (human RSK2) in the linker region, and in a Ser386 phospho dependent manner. Recruitment of PDK1 results in phosphorylation and activation of PDK1



**Figure 6** Lateral view of the spine in a male with CLS showing thickening and irregularity of the vertebral end plates with concavity of the upper and lower surfaces of the vertebral bodies.

itself. Activated PDK1 phosphorylates Ser227 and thereby activates the N-terminal catalytic domain.<sup>44</sup> Thus, RSK enzymatic activity results from the synergistic action of at least two signalling pathways, the ERK pathway and the PDK1 pathway. The activated N-terminal domain phosphorylates substrates on threonine and serine residues within the basophilic consensus motif Arg/Lys-X-Arg-X-X-Ser/Thr or Arg-Arg-X-Ser/Thr.<sup>45</sup>

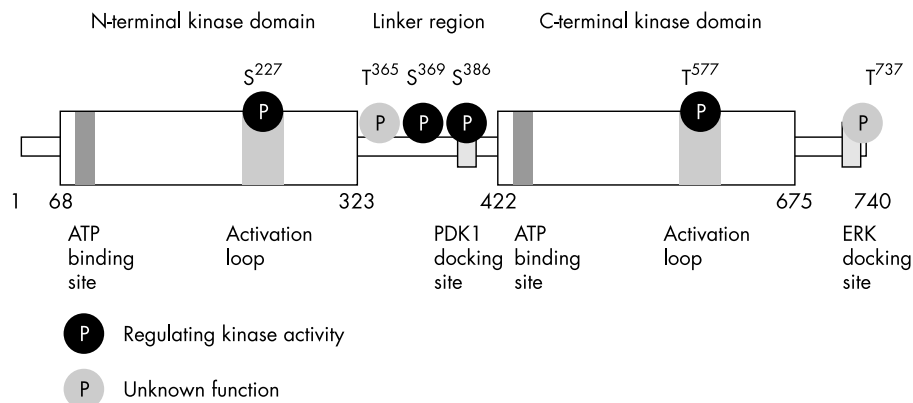
#### Functions of RSK

RSKs have been implicated in several important cellular events, including proliferation and differentiation, cellular stress response, and apoptosis.<sup>46</sup> Involvement in regulating a wide range of cellular functions has been supported by the identification of numerous and diverse cytosolic and nuclear substrates. Known cytosolic RSK substrates include IκBα, glycogen synthase kinase-3 (GSK3), and the pro-apoptotic BCL2 antagonist of cell death (BAD) protein.<sup>47</sup> Among nuclear substrates so far identified there are various histones and several transcription factors, such as the cAMP responsive element binding protein (CREB), c-Fos, c-Jun, the oestrogen nuclear receptor alpha (Erα), Nur 77, and the serum response factor (SFR).<sup>47</sup> RSKs may also bind and modulate the function of the transcriptional coactivators CBP and p300.<sup>48</sup> Together these data support a major role for RSK proteins in transcriptional control of gene expression. The respective contribution of each RSK to the activation of most of the known substrates is still unknown. It is also unclear whether distinct cellular functions are regulated by the four proteins or whether they perform unique plus overlapping functions. However, a few RSK2 specific physiological substrates have already been identified. They include the transcription factor CREB<sup>49</sup> and histone H3<sup>50</sup> (fig 8). CREB binds to a DNA element known as the cAMP regulated enhancer (CRE) present in the 5' region of various genes regulated by CREB activity. Indeed, a drastic reduction of EGF-*c-fos* induction, an immediate early gene whose expression is regulated by CREB, was observed in fibroblasts from a CLS patient lacking functional RSK2.<sup>49</sup> Phosphorylation of histone H3 is believed to facilitate its acetylation and thereby favour chromatin decondensation and transcription. Thus, chromatin remodelling might contribute to RSK2 regulated gene expression.

While *RSK1* and *RSK3* have not yet been associated with a disorder, recent data suggest that mutation in *RSK4* may also lead to mental retardation.<sup>51</sup>

#### Mutation spectrum

By screening of 250 unrelated subjects with clinical features suggestive of Coffin-Lowry syndrome, over 75 distinct disease associated *RSK2* mutations have been identified in 85 of these patients (fig 9).<sup>5 6 32 52</sup> Approximately 40% of these mutations

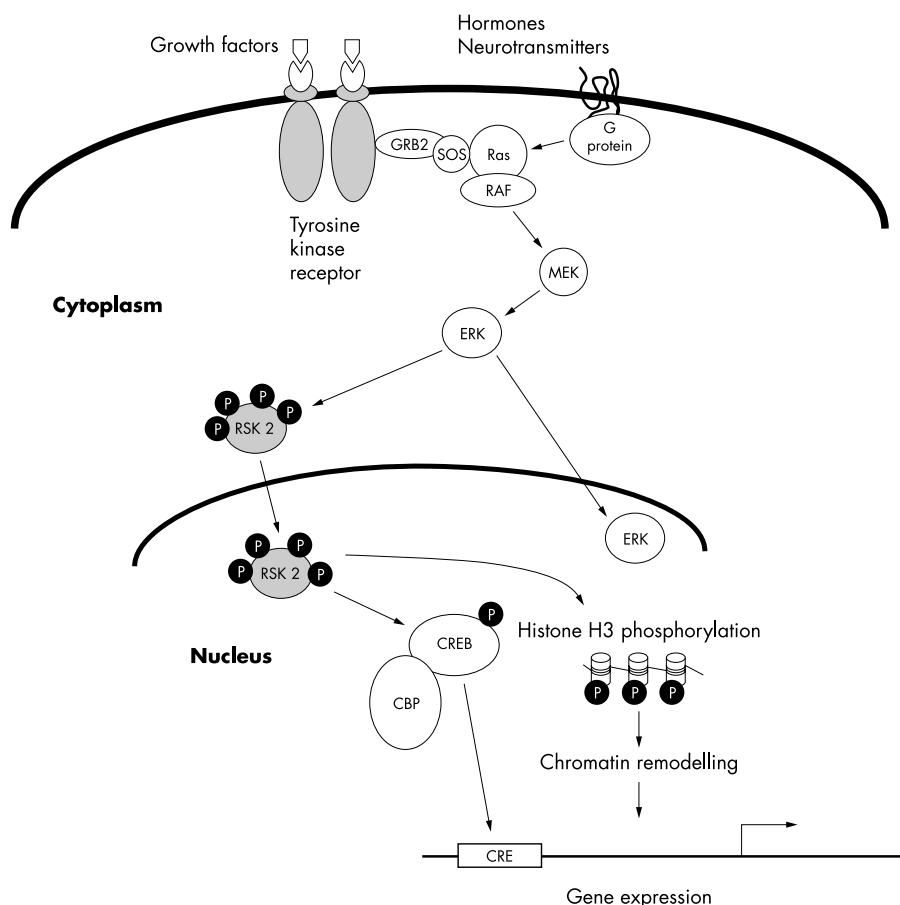


**Figure 7** Structure of RSK proteins. Six regulatory phosphorylation sites (P) are indicated. Amino acid numbering refers to human RSK2.

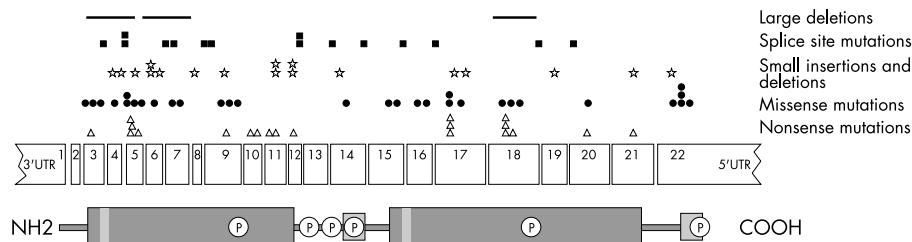
are missense mutations, 20% nonsense mutations, 20% splicing errors, and 20% short deletion or insertion events. Only three large deletions, two involving two exons and the third only one exon, have so far been found. Mutations occurred throughout all exons, except exons 1 and 2, and the majority have been found in a single family. Only 11 mutations have shown recurrence: the most prevalent alterations are three nonsense mutations (three occurrences each) and a missense mutation (three occurrences) (fig 9). Intriguingly, a high rate of new mutations was observed. Indeed, in a total of 41 families for which samples were available from the mothers of the probands, two thirds (27/41) of the mutations arose de novo in the proband. This high proportion of de novo mutation is very unusual in X linked disorders and has received no explanation

as yet. Evidence for germinal mosaicism was clearly shown in two families<sup>53, 54</sup> and strong suggestion was provided by a few additional families. Ten mutations have been identified in young female probands ascertained through learning disability and mild but suggestive physical phenotype, but with no affected male relatives.

Two thirds of *RSK2* mutations result in premature translation termination, out of which the vast majority have been shown or can be predicted to cause complete loss of function of the mutant allele. One-third of *RSK2* mutations exert their effect by substituting one amino acid. A number of these missense mutations alter known phosphorylation sites (or surrounding amino acids belonging to their recognition motifs) critical for *RSK2* catalytic function, ATP binding sites,



**Figure 8** The RSK2 signalling pathway. Only two RSK2 specific physiological substrates are represented.



**Figure 9** Mutation spectrum of the *RSK2* gene. Mutations so far detected are shown above the schematic representation of the *RSK2* transcript. Exons are represented as boxes numbered from 1 to 22. Below the *RSK2* transcript is represented the protein. White boxes in both kinase domains represent ATP binding sites and (P) regulatory phosphorylation sites.

or the ERK docking site and their detrimental effect is obvious. The mechanism by which the remaining missense mutations exert their effects is less evident but in most cases the secondary structure of the kinase domains is likely to be disrupted.

A web page (<http://alsace.u-strasbg.fr/chimbio/diag/coffin/index.html>) is available for information about *RSK2*, including a continuously updated overview of all *RSK2* mutations.

### GENOTYPE/PHENOTYPE RELATIONSHIP

No consistent relationship has been observed between specific mutations and the severity of the disease or the expression of particular features. The extent of protein truncation, for instance, shows no correlation with the disease severity. This makes genetic counselling difficult because estimation of the severity of involvement cannot be given to parents. Interestingly, however, significantly milder disease was noted in some cases carrying missense mutations as compared with the vast majority of those with truncating mutations. For instance, the I189K mutation, which results in a mutant protein retaining 10% of residual enzymatic activity, was identified in two slightly retarded male sibs with a very mild form of CLS.<sup>7</sup> The least severely affected male of our cohort of patients expressed a mutant protein retaining 20% of residual kinase activity.<sup>8</sup> The patient bearing this mutation and his affected male relatives were only mildly mentally retarded. This family was previously published as a non-syndromic X linked mental retardation family,<sup>35</sup> and formally these patients cannot be classified as CLS patients since they do not exhibit any physical feature of the syndrome. Thus, the tendency in some patients carrying a missense mutation to be less affected suggests a pivotal role of residual enzyme activity in determining severity of symptoms. It is, however, difficult to extend this observation to all known missense mutations, since detailed clinical data and cell lines, necessary for assessing the kinase activity, of a high proportion of patients have not been available. In addition, patients have been examined by different clinicians and there was no common definition of severity. Nevertheless, investigation in a few families with multiple affected members showed that there is intrafamilial variability for severity or for expression of uncommonly associated features. Thus, taken together, current data suggest that the genotype of the mutation is not the only determinant in phenotypic expression. Environmental factors or other components that contribute to the same physiological function as the *RSK2* protein may also influence the presentation of the disease. Modifying genes could be those encoding other RSK members or the closely related MSKs<sup>47</sup> or genes that encode proteins that participate in the same pathway. X chromosome inactivation studies undertaken on peripheral blood samples from six female heterozygotes have not shown significant deviation from normal.

### MOLECULAR DIAGNOSIS

Early diagnosis of Coffin-Lowry syndrome is essential for proper management of the patients, including survey of some

specific complications, and for genetic counselling. For instance, sensorineural hearing deficit should be addressed very early in order to improve the development and quality of life of the patients. However, several factors can lead to diagnostic and hence counselling difficulties. Most cases (80%) with Coffin-Lowry syndrome are sporadic and only a few families with transmission over three generations are known. In addition, since most clinical features are non-specific, clinical examination may not always distinguish CLS from other mental retardation syndromes, especially in very young children. In particular, similarities in the clinical presentation of CLS and ATR-X have been repeatedly noted. In the series of 250 patients clinically diagnosed with CLS and screened by SSCP analysis, no mutation was detected in 66% of them. Even if mutations have been missed in 20% of these patients by SSCP, as suggested by our recent study,<sup>56</sup> there remain over 50% of patients who have no *RSK2* defect. In 50 of these patients, no mutation was identified in *RSK4* either (H G Yntema, personal communication). It is very likely that some of these subjects were misdiagnosed. Nevertheless, detailed clinical records obtained for a number of subjects provide evidence that indeed some patients without *RSK2* mutation exhibit a typical CLS phenotype. Therefore, the possibility of locus heterogeneity should also be taken into consideration. Interestingly, a patient with a CLS-like phenotype and carrying an interstitial deletion on chromosome 10 has recently been reported.<sup>57</sup> Thus, screening for mutations in the *RSK2* gene is essential to establish the diagnosis of CLS firmly in the majority of patients and to offer molecular prenatal or carrier diagnosis to families. Primer sets used to amplify *RSK2* exons from genomic DNA templates have been reported.<sup>6-32</sup> To date an *RSK2* mutation has been identified in only 1 of 50 families analysed with non-specific mental retardation. Thus, at present, it is probably reasonable to limit *RSK2* mutation analysis to those cases and families with CLS-like features.

Both the widespread distribution of mutations and the rather large number of exons contribute to difficulties in systematically analysing the gene for CLS diagnosis using current techniques. In addition, some mutations, in particular in the intronic regions, may be missed by SSCP analysis. Therefore, functional tests have been set up that are of great value in the differential diagnosis of CLS. Western blot analysis has proved to be an important adjunct in identifying patients lacking protein product despite no detectable mutations by SSCP analysis<sup>58</sup> (submitted). Based upon current knowledge of the nature of mutations in *RSK2*, it can be estimated that western blot analysis of *RSK2* allows detection of up to 70% of the mutated *RSK2* proteins. Western blot analysis can be performed on lymphocyte protein extracts prepared directly from fresh (less than 24 hours) blood samples, or from a lymphoblast or a fibroblast cell line. An in vitro kinase assay has also been developed which would certainly be the diagnostic method of choice as potentially it can detect all classes of mutations and also provide information on possible residual enzyme activity. Both western and kinase assays can be used



for prenatal diagnosis since the RSK2 protein is readily detectable in cultured amniocytes. Unfortunately, female heterozygote detection is not feasible by western blot analysis or by kinase assay because of random X inactivation.

## PATHOGENESIS

The nature of the anatomical and physiological defects in CLS patients in relation to *RSK2* mutations is still poorly understood. However, the fact that cognitive impairment is a prominent feature of patients with Coffin-Lowry syndrome indicates an important role of RSKs in development and/or function of the central nervous system. At a macroscopic level, no reproducible pathological abnormalities have been reported, suggesting that *RSK2* is not required for major aspects of brain development. The possibility that RSKs are involved in more subtle processes like neuronal plasticity has recently begun to receive attention. The ERK/MAPK signalling cascade is required for both long term memory formation and synaptic plasticity.<sup>59,60</sup> A defect in CREB phosphorylation is also a potential cause of the cognitive impairment, because cells derived from CLS patients are deficient in EGF stimulated CREB phosphorylation.<sup>49</sup> A growing body of evidence documents CREB activation as an essential step in the process of learning and long term memory formation.<sup>61,62</sup> Long term potentiation (LTP), a long lasting increase in the efficacy of synaptic transmission, is postulated to be a model for cellular mechanisms underlying learning and memory acquisition.<sup>63</sup> LTP requires synthesis of proteins, and activation of the transcription factor CREB represents one step in the cascade of events leading to this protein synthesis. Recent results have provided evidence that CREB is activated by the MAPK/ERK pathway via RSK2.<sup>64</sup> In addition to several immediate early genes and transcription factors known to be regulated by CREB, there are numbers of other genes that contain one or more CREs and whose products are involved in learning, including BDNF, the transcription factor C/EBP, and the extracellular protease tissue plasminogen activator (tPA). RSK2 has also been identified in NMDAR multiprotein complexes isolated from mouse brain.<sup>65</sup> The NMDA receptor has been implicated in the induction of synaptic plasticity through activation of second messenger pathways.

It is also unclear how mutations in *RSK2* give rise to skeletal defects in CLS. The mechanism by which *RSK2* contributes to proper skeleton formation is unknown. However, studies with a fibroblast cell line derived from a CLS patient have indicated that the cells are defective in *c-fos* gene expression induced by EGF.<sup>49</sup> Various studies have established a unique role for the nuclear transcription factor *c-fos* in regulating the differentiation and activity of specific bone cell populations during development. Interestingly, phenotypic manifestations of mice lacking *c-fos* include growth retardation and deficiencies in bone remodelling and tooth eruption, highly reminiscent of those expressed by CLS patients.<sup>66</sup> It can be hypothesised that disruption of this pathway in CLS patients might be responsible, at least in part, for the skeletal changes.

A mouse model for CLS, obtained by homologous recombination and carrying targeted mutations at the *RSK2* locus, was recently described.<sup>67</sup> It provides a powerful tool to examine the role of *RSK2* in brain development, cognitive function, neuronal plasticity, and bone formation in more detail.

## ACKNOWLEDGEMENTS

We are deeply grateful to all the families and clinicians whose participation made the CLS genetic studies possible. We also wish to thank the past and present members of the group of A Hanauer who have contributed to the CLS studies, including E Trivier, S Jacquot, K Merienne, Maria Zeniou, and S Pannetier. We also thank Dr Margaret Barrow, Mrs Vivian Grainge, Dr Pat McKeever, and Mrs Sue Snook for their help in preparing this manuscript and Mrs Sue Kenney for expert secretarial assistance.

## Authors' affiliations

**A Hanauer**, Institut de Génétique et du Biologie Moléculaire et Cellulaire, CNRS INSERM, Université Louis Pasteur, Illkirch, CU de Strasbourg, France

**I D Young**, Department of Clinical Genetics, Leicester Royal Infirmary, Leicester LE1 5WW, UK

## REFERENCES

- Coffin GS, Siris E, Wegienka LC. Mental retardation with osteocartilaginous anomalies. *Am J Dis Child* 1966;**112**:205-13.
- Lowry B, Miller JR, Fraser FC. A new dominant gene mental retardation syndrome. *Am J Dis Child* 1971;**121**:496-500.
- Temtamy SA, Miller JD, Hussels-Maumenee I. The Coffin-Lowry syndrome: an inherited facioidigital mental retardation syndrome. *J Pediatr* 1975;**86**:724-31.
- Hanauer A, Alembik Y, Gilgenkrantz S, Mujica P, Nivelon-Chevallier A, Pembrey ME, Young ID, Mandel JL. Probable localisation of the Coffin-Lowry locus in Xp22.2-p22.1 by multipoint linkage analysis. *Am J Med Genet* 1988;**30**:523-30.
- Trivier E, De Cesare D, Jacquot S, Pannetier S, Zackai E, Young I, Mandel JL, Sassone-Corsi P, Hanauer A. Mutations in the kinase Rsk-2 associated with Coffin-Lowry syndrome. *Nature* 1996;**384**:567-70.
- Delauney JP, Abidi F, Zeniou M, Jacquot S, Merienne K, Pannetier S, Schmitt M, Schwartz CE, Hanauer A. Mutations in the X-linked RSK2 gene (RPS6KA3) in patients with Coffin-Lowry syndrome. *Hum Mutat* 2001;**17**:103-16.
- Manouvrier-Hanu S, Amiel J, Jacquot S, Merienne K, Moerman A, Coëslier A, Labarriere F, Vallée L, Croquette MF, Hanauer A. Unreported RSK2 missense mutation in two male sibs with an unusually mild form of Coffin-Lowry syndrome. *J Med Genet* 1999;**26**:775-8.
- Merienne K, Jacquot S, Pannetier S, Zeniou M, Bankier A, Gecz J, Mandel JL, Mulley J, Sassone-Corsi P, Hanauer A. A missense mutation in RPS6KA3 (RSK2) responsible for non-specific mental retardation. *Nat Genet* 1999;**22**:13-14.
- Martinelli B, Campailla E. Contributo alla conoscenza della sindrome di Coffin Siris Wegienka: report of a case. *G Psychiatr Neuropatol* 1969;**97**:449-58.
- Procopis PG, Turner B. Mental retardation, abnormal fingers, and skeletal anomalies; Coffin's syndrome. *Am J Dis Child* 1972;**124**:258-61.
- Fryns JP, Vinken L, van den Berghe H. The Coffin syndrome. *Hum Genet* 1977;**36**:271-6.
- Wilson WG, Kelly TE. Early recognition of the Coffin-Lowry syndrome. *Am J Med Genet* 1981;**8**:215-20.
- Hunter AGW, Partington MW, Evans JA. The Coffin-Lowry syndrome. Experience from four centres. *Clin Genet* 1982;**21**:321-35.
- Haspelagh M, Fryns JP, Beusen L, Van Dessel F, Vinken L, Moens E, Van Den Berghe H. The Coffin-Lowry syndrome. A study of two new index patients and their families. *Eur J Pediatr* 1984;**143**:82-6.
- Collacott RA, Warrington JS, Young I D. Coffin-Lowry syndrome and schizophrenia: a family report. *J Ment Defic Res* 1987;**31**:199-207.
- Kousseff BG. Coffin-Lowry syndrome in an Afro-American family. *Am J Med Genet* 1982;**11**:373-5.
- Gilgenkrantz S, Mujica P, Gruet P, Tridon P, Schweitzer F, Nivelon-Chevallier A, Nivelon JL, Couillault G, David A, Verloes A, Lambotte C, Prissan CP, Mathieu M. Coffin-Lowry syndrome: a multicenter study. *Clin Genet* 1988;**34**:230-45.
- Partington MW, Mulley JC, Sutherland GR, Thode A, Turner G. A family with the Coffin-Lowry syndrome revisited: localization of CLS to Xp21-pter. *Am J Med Genet* 1988;**30**:509-21.
- Plomp AS, De Die-Smulders CEM, Meinecke P, Ypma-Verhulst JM, Lissone DA, Fryns JP. Coffin-Lowry syndrome: clinical aspects at different ages and symptoms in female carriers. *Genet Couns* 1995;**6**:259-68.
- Hersh JH, Weisskopf B, DeCoster C. Forearm fullness in Coffin-Lowry syndrome: a misleading yet possible early diagnostic clue. *Am J Med Genet* 1984;**18**:185-9.
- Padley S, Hodgson SV, Sherwood T. The radiology of Coffin-Lowry syndrome. *Br J Radiol* 1990;**63**:72-5.
- Hartsfield JK, Hall BD, Grix AW, Kousseff BG, Salazar JF, Haufe SMW. Pleiotropy in Coffin-Lowry syndrome: sensorineural hearing deficit and premature tooth loss as early manifestations. *Am J Med Genet* 1993;**45**:552-7.
- Sivagamasundari U, Fernando H, Jardine P, Rao JM, Lunt P, Jayawardene SLW. The association between Coffin-Lowry syndrome and psychosis: a family study. *J Intell Dis Res* 1994;**38**:469-73.
- Machin GA, Walther GL, Fraser VM. Autopsy findings in two adult siblings with Coffin-Lowry syndrome. *Am J Med Genet* 1987;**suppl 3**:303-9.
- Krajewska-Walasek M, Kubicka K, Ryzko J. Cardiac involvement in Coffin-Lowry syndrome. *Eur J Pediatr* 1988;**147**:448.
- Massin MM, Radermecker MA, Verloes A, Jacquot S, Grenade T. Cardiac involvement in Coffin-Lowry syndrome. *Acta Paediatr* 1999;**88**:468-70.
- Nakamura M, Yamagata T, Momoi MY, Yamazaki T. Drop episodes in Coffin-Lowry syndrome: exaggerated startle responses treated with clonazepam. *Pediatr Neurol* 1998;**19**:148-50.
- Crow YJ, Zuberi SM, McWilliam R, Tolmie JL, Hollmann A, Pohl K, Stephenson JBP. "Cataplexy" and muscle ultrasound abnormalities in Coffin-Lowry syndrome. *J Med Genet* 1998;**35**:94-8.



- 29 **Ishida Y**, Oki T, Ono Y, Nogami H. Coffin-Lowry syndrome associated with calcium pyrophosphate crystal deposition in the ligamenta flava. *Clin Orthop Rel Res* 1992;**275**:144-51.
- 30 **Biancalana V**, Briard ML, David A, Gilgenkrantz S, Kaplan J, Mathieu M, Piussan C, Poncin J, Schintzel A, Oudet C, Hanauer A. Confirmation and refinement of the genetic localization of the Coffin-Lowry syndrome locus in Xp22.1-p22.2. *Am J Hum Genet* 1992;**50**:981-7.
- 31 **Biancalana V**, Trivier E, Weber C, Weissenbach J, Rowe PS, O'Riordan JL, Partington MW, Heyberger S, Oudet C, Hanauer A. Construction of a high-resolution linkage map for Xp22.1-p22.2 and refinement of the genetic localization of the Coffin-Lowry syndrome gene. *Genomics* 1994;**22**:617-25.
- 32 **Jacquot S**, Merienne K, De Cesare D, Pannetier S, Mandel JL, Sassone-Corsi P, Hanauer A. Mutation analysis of the RSK2 gene in Coffin-Lowry patients: extensive allelic heterogeneity and a high rate of de novo mutations. *Am J Hum Genet* 1998;**63**:1631-40.
- 33 **Erikson E**, Maller JL. A protein kinase from *Xenopus* eggs specific for ribosomal protein S6. *Proc Natl Acad Sci U S A* 1985;**82**:742-6.
- 34 **von Manteuffel SR**, Dennis PB, Pullen N, Gingras AC, Sonenberg N, Thomas G. The insulin-induced signalling pathway leading to S6 and initiation factor 4E binding protein 1 phosphorylation bifurcates at a rapamycin-sensitive point immediately upstream of p70s6k. *Mol Cell* 1997;**17**:5426-36.
- 35 **Grove JR**, Price DJ, Banerjee P, Balasubramanyam A, Ahmad MF, Avruch J. Protein regulation of an epitope-tagged recombinant Rsk-1 S6 kinase by phorbol ester and erk/MAP kinase. *Biochemistry* 1993;**32**:7727-38.
- 36 **Wassarman DA**, Solomon NM, Rubin GM. The *Drosophila melanogaster* ribosomal S6 kinase II-encoding sequence. *Gene* 1994;**144**:309-10.
- 37 **Zhao Y**, Bjorbaek C, Weremowicz S, Morton CC, Moller DE. RSK3 encodes a novel pp90rsk isoform with a unique N-terminal sequence: growth factor-stimulated kinase function and nuclear translocation. *Mol Cell Biol* 1995;**15**:4353-63.
- 38 **Sutherland C**, Alterio J, Campbell DG, Le Bourdelles B, Mallet J, Haavik J, Cohen P. Phosphorylation and activation of human tyrosine hydroxylase in vitro by mitogen-activated protein (MAP) kinase and MAP-kinase-activated kinases 1 and 2. *Eur J Biochem* 1993;**217**:715-22.
- 39 **Bjorbaek C**, Vik TA, Echwald SM, Yang, PY, Vestergaard H, Wang JP, Webb GC, Richmond K, Hansen T, Erikson RL, Gabor-Miklos GL, Cohen PTW, Pederson O. Cloning of a human insulin-stimulated protein kinase (ISPK-1) gene and analysis of coding regions and mRNA levels of the ISPK-1 and the protein phosphatase-1 genes in muscle from NIDDM patients. *Diabetes* 1995;**44**:90-7.
- 40 **Fisher TL**, Blenis J. Evidence for two catalytically active kinase domains in pp90rsk. *Mol Cell Biol* 1996;**16**:1212-19.
- 41 **Dalby KN**, Morrice N, Caudwell FB, Avruch J, Cohen P. Identification of regulatory phosphorylation sites in mitogen-activated protein kinase (MAPK)-activated protein kinase-1a/pp90rsk that are inducible by MAPK. *J Biol Chem* 1998;**273**:1496-505.
- 42 **Smith JA**, Poteet-Smith CE, Malarkey K, Sturgill TW. Identification of an extracellular signal-regulated kinase (ERK) docking site in ribosomal S6 kinase, a sequence critical for activation by ERK in vivo. *J Biol Chem* 1999;**274**:2893-8.
- 43 **Vik TA**, Ryder JW. Identification of serine 380 as the major site of autophosphorylation of *Xenopus* pp90rsk. *Biochem Biophys Res Commun* 1997;**235**:398-402.
- 44 **Frödin M**, Jensen CJ, Merienne K, Gammeltoft S. A phosphoserine-regulated docking site in the protein kinase RSK2 that recruits and activates PDK1. *EMBO J* 2000;**19**:2924-34.
- 45 **Leighton IA**, Dalby KN, Caudwell FB, Cohen PT, Cohen P. Comparison of the specificities of p70 S6 kinase and MAPKAP kinase-1 identifies a relatively specific substrate for p70 S6 kinase: the N-terminal kinase domain of MAPKAP kinase-1 is essential for peptide phosphorylation. *FEBS Lett* 1995;**375**:289-93.
- 46 **Blenis J**. Signal transduction via the MAP kinases; proceed at your own RSK. *Proc Natl Acad Sci USA* 1993;**90**:5889-92.
- 47 **Frödin M**, Gammeltoft S. Role and regulation of 90 kDa ribosomal S6 kinase (RSK) in signal transduction. *Mol Cell Endocrinol* 1999;**25**:65-77.
- 48 **Nakajima T**, Fukamizu A, Takahashi J, Gage FH, Fisher T, Blenis J, Montminy MR. The signal-dependent coactivator CBP is a nuclear target for pp90RSK. *Cell* 1996;**86**:465-74.
- 49 **De Cesare D**, Jacquot S, Hanauer A, Sassone-Corsi P. Rsk-2 activity is necessary for epidermal growth factor-induced phosphorylation of CREB protein and transcription of c-fos gene. *Proc Natl Acad Sci USA* 1998;**95**:12202-7.
- 50 **Sassone-Corsi P**, Mizzen CA, Cheung P, Crosio C, Monaco L, Jacquot S, Hanauer A, Allis CD. Requirement of Rsk-2 for epidermal growth factor-activated phosphorylation of histone H3. *Science* 1999;**285**:886-90.
- 51 **Yntema HG**, van den Helm B, Kissing J, van Duijnhoven G, Poppelaars F, Chelly J, Moraine C, Fryns JP, Hamel BC, Heilbronner H, Pander HJ, Brunner HG, Ropers HH, Cremers FP, van Bokhoven H. A novel ribosomal S6-kinase (RSK4; RPS6KA6) is commonly deleted in patients with complex X-linked mental retardation. *Genomics* 1999;**15**:332-43.
- 52 **Abidi F**, Jacquot S, Lassiter C, Trivier E, Hanauer A, Schwartz CE. Novel mutations in Rsk-2, the gene for Coffin-Lowry syndrome (CLS). *Eur J Hum Genet* 1999;**7**:20-6.
- 53 **Jacquot S**, Merienne K, Pannetier S, Blumenfeld S, Schinzel A, Hanauer A. Germline mosaicism in Coffin-Lowry syndrome. *Eur J Hum Genet* 1998;**6**:578-82.
- 54 **Horn D**, Delaunoy JP, Kunze J. Prenatal diagnosis in Coffin-Lowry syndrome demonstrates germinal mosaicism confirmed by mutation analysis. *Prenat Diagn* 2001;**21**:1-4.
- 55 **Donnelly AJ**, Choo KH, Kozman HM, Gedeon AK, Danks DM, Mulley JC. Regional localisation of a non-specific X-linked mental retardation gene (MRX19) to Xp22. *Am J Med Genet* 1994;**51**:581-5.
- 56 **Zeniou M**, Pannetier S, Fryns JP, Hanauer A. Unusual splice-site mutations in the RSK2 gene and suggestion of genetic heterogeneity in Coffin-Lowry syndrome. *Am J Med Genet* 2002;**70**:1421-33.
- 57 **McCandless SE**, Schwartz S, Morrison S, Garlapati K, Robin NH. Adult with an interstitial deletion of chromosome 10 [del(10)(q25.1q25.3)]: overlap with Coffin-Lowry syndrome. *Am J Med Genet* 2000;**13**:93-8.
- 58 **Merienne K**, Jacquot S, Trivier E, Pannetier S, Rossi A, Schinzel A, Castellani C, Kress W, Hanauer A. Rapid immunoblot and kinase assay tests for a syndromal form of X-linked mental retardation: Coffin-Lowry syndrome. *J Med Genet* 1998;**35**:890-4.
- 59 **Atkins CM**, Selcher JC, Petraitis JJ, Trzaskos JM, Sweatt JD. The MAPK cascade is required for mammalian associative learning. *Nat Neurosci* 1998;**1**:602-9.
- 60 **Blum S**, Moore AN, Adams F, Dash PK. A mitogen-activated protein cascade in the CA1/CA2 subfield of the dorsal hippocampus is essential for long-term spatial memory. *J Neurosci* 1999;**19**:3535-44.
- 61 **Gass P**, Wolfer DP, Balschun D, Rudolph D, Frey U, Lipp HP, Schutz G. Deficits in memory tasks of mice with CREB mutations depend on gene dosage. *Learn Mem* 1998;**5**:274-88.
- 62 **Silva AJ**, Kogan JH, Frankland PW, Kida S. CREB and memory. *Annu Rev Neurosci* 1998;**21**:127-48.
- 63 **Bliss TVP**, Collingridge GL. A synaptic model of memory: long-term potentiation in the hippocampus. *Nature* 1993;**361**:31-9.
- 64 **Impey S**, Smith DM, Obrietan K, Donahue R, Wade C, Storm DR. Stimulation of cAMP response element (CRE)-mediated transcription during contextual learning. *Nat Neurosci* 1998;**1**:595-601.
- 65 **Husi H**, Ward MA, Choudhary JS, Blackstock WP, Grant SG. Proteomic analysis of NMDA receptor-adhesion protein signaling complexes. *Nat Neurosci* 2000;**3**:661-9.
- 66 **Wang ZQ**, Ovit C, Grigoriadis AE, Mohle-Steinlein U, Ruther U, Wagner EF. Bone and haematopoietic defects in mice lacking c-fos. *Nature* 1992;**360**:741-5.
- 67 **Dufresne SD**, Bjorbaek C, El-Haschimi K, Zhao Y, Aschenbach WG, Moller DE, Goodyear LJ. Altered extracellular signal-regulated kinase signaling and glycogen metabolism in skeletal muscle from p90 ribosomal S6 kinase 2 knockout mice. *Mol Cell Biol* 2001;**21**:81-7.