

Letters to the Editor

J Med Genet 2000;37:533–536

Incidence of germline *hMLH1* and *hMSH2* mutations (HNPCC patients) among newly diagnosed colorectal cancers in a Slovenian population

EDITOR—Hereditary non-polyposis colorectal cancer (HNPCC) syndrome is a common autosomal dominant predisposition to colorectal cancer. Clinical diagnostic features of sporadic and HNPCC associated colorectal cancer do not differ significantly and until recently the identification of HNPCC patients was based mainly on their family history. Because of the importance for relatives of HNPCC patients to be clinically examined frequently in order to detect the disease at an early, curable stage, the International Collaborative Group (ICG) on HNPCC proposed criteria for identification of HNPCC families. According to the guidelines agreed by the ICG in Amsterdam in 1990, an HNPCC family has to fulfil the following criteria: there should be at least three relatives with colorectal cancer (one of whom is a first degree relative to the other two), at least two successive generations should be affected, and one relative should be diagnosed under the age of 50.¹ CRC patients with HNPCC syndrome can also develop cancer of the endometrium, stomach, ovary, and urinary and hepatobiliary tracts.^{2–5} In several epidemiological studies, the incidence of HNPCC has been estimated to be between 0.5%⁶ and 15%³ of all colorectal cancers. The identification of mismatch repair genes (MMR), of which at least five (*hMLH1*,^{7–8} *hMSH2*,^{9–10} *PMS1*,^{9–10} *PMS2*,⁷ and *hMSH6* (*GTBP*)¹¹) are associated with HNPCC, has enabled mutational analysis in families fulfilling complete or partial Amsterdam criteria. Carriers of germline MMR mutations have a higher than 80% risk for cancer by the age of 75.² The great majority of germline mutations were found in approximately equal proportions in *hMLH1* and *hMSH2*, while mutations in the other three MMR genes have been reported only in a limited number of cases.¹² Germline *hMLH1* and *hMSH2* mutations were also found in a considerable proportion of colorectal cancer patients from families not fulfilling the Amsterdam criteria,¹³ especially if they were young,^{14–15} indicating that some HNPCC families might be missed if they are preselected before mutational analysis.

Mutations in MMR genes result in microsatellite instability (MSI),¹⁶ which is characteristic of more than 90% of tumours in HNPCC patients but was also found in 12–15% of sporadic colorectal tumours.^{17–19} In the absence of other diagnostic criteria, MSI analysis of tumours could be valuable markers in HNPCC identification.

Here we report an effective MSI analysis of CRC and subsequent mutational analysis of the *hMLH1* and *hMSH2* genes in tumours with considerable MSI for identification of HNPCC among randomly collected, newly diagnosed colorectal cancers. This approach allowed us to identify HNPCC families and to estimate the minimal incidence of HNPCC in a Slovenian population based solely on molecular genetic analysis.

Primary colorectal adenocarcinomas and corresponding normal tissue samples were collected from patients who gave consent for testing of their DNA. Between 1996 and

1998, 300 newly diagnosed CRC patients from clinics all over Slovenia participated in this study. The sample of CRC is thus representative for the Slovenian population. All samples were gathered in a central institution where two physicians histologically evaluated each resection for a high proportion of tumour tissue. We also confirmed a high proportion of cancer cells versus normal cells in tumour tissue in many samples that exhibited LOH during MSI analysis. Normal colorectal mucosa taken from a site distant from the tumour was used as a normal control in the study.

We isolated DNA after tissue digestion using standard phenol/chloroform extraction and ethanol precipitation from frozen colorectal tumours and corresponding normal tissue samples. For MSI analysis of tumour and control

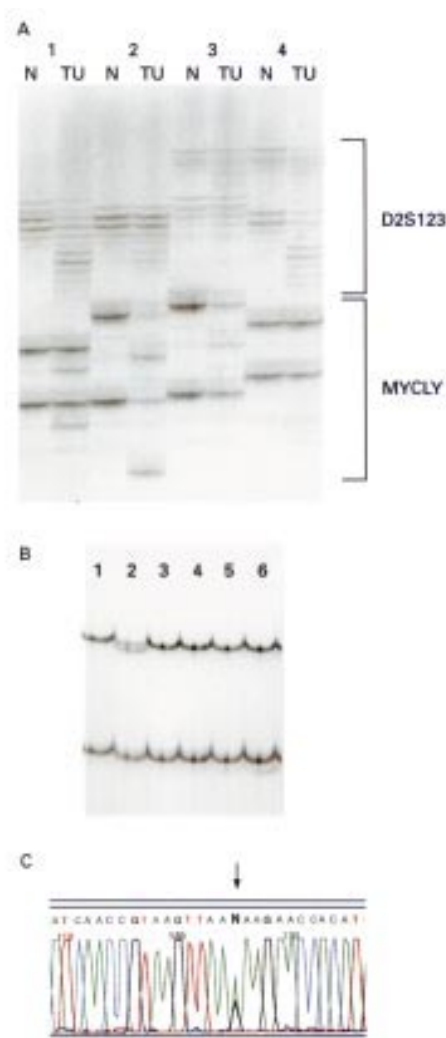


Figure 1 Strategy of molecular genetic based identification of HNPCC patients. (A) Microsatellite instability (MSI) analysis; D2S123 and MYCLY microsatellite markers were amplified in a multiplex PCR reaction and products were resolved on a 6% denaturing gel and silver stained. Tumour samples 1–3 exhibit MSI at both markers while sample 4 exhibits MSI only at D2S123. N=normal, TU=tumour. (B) SSCP analysis of *hMLH1* exon and exon/intron boundary 9; aberrant bands in sample 2 indicates sequence alteration. (C) Sequence analysis of exon/intron boundary 9 of *hMLH1* gene of sample 2. Arrow indicates heterozygous A→G substitution.

Table 1 Pathogenic germline *hMLH1* and *hMSH2* mutations identified in high MSI tumours

Gene and patient	Exon	Nucleotide change	Consequence	Reference
<i>hMLH1</i>				
OG/98-2989	2	199 G→A	G67R	31
OG/97-4266	15	1684 C→T	Q562X	This study
OG/97-3941	17	1964 T→C	I655T	32
<i>hMSH2</i>				
OG/97-2426	3	561 del TGAGGCTCT	In frame del of codons 188-190	33

tissue pairs, we tested the majority of samples with the following markers: mononucleotides BAT26,¹¹ BAT25,¹¹ and BAT40,²⁰ dinucleotides D2S123,²¹ D5S346,²² TP53,²³ D11S1294,²⁴ D112179,²⁴ D17S250,²⁵ D18S58,²⁶ and D18S69,²¹ and tetranucleotide MYCLY.²⁷ Tumours were scored as high MSI if more than 40% of tested markers were positive and were scored as low MSI if less than 20% of tested markers were positive. During the analysis, it turned out that for determination of high MSI status four selected markers were sufficient, BAT26, D2123, BAT25, and D5S346. Therefore, we analysed additional samples in multiplex PCR reactions for microsatellite markers BAT26 and D2123, and BAT25 and D5S346, respectively. In this case, tumour tissue was scored as high MSI if at least two of four markers were altered.

MSI analysis was performed as previously described.²⁸ Briefly, after PCR amplification products were run on a thin (0.4 mm) denaturing polyacrylamide gel matrix fixed on one of the glass plates followed by an optimised silver staining protocol that markedly improved the resolution. MSI was detected as some additional bands in tumour DNA compared to control DNA (fig 1A).

For mutational analysis of *hMLH1* and *hMSH2* mismatch repair genes (MMR), we used PCR/non-isotopic conformation analysis (article in preparation). The basic principle of this method is a combination of three analyses which are all based on changes in three dimensional DNA structures, that is, single strand conformation analysis (SSCA), heteroduplex analysis (HA), and double strand conformation analysis (DSCA). We conducted them simultaneously on the same thin polyacrylamide gel.

Altogether, of 300 randomly collected primary colorectal tumours, 29 (9.7%) were classified as high MSI tumours and 23 (7.7%) as low MSI tumours. The use of BAT26 only has been previously proposed for determination of high MSI status.²⁹⁻³⁰ Our results show that using only this marker we would have missed one of 29 high MSI tumours. On the other hand, no low MSI tumour was positive for BAT26 or BAT25.

Genomic DNA from 29 subjects with high microsatellite instability tumours were further analysed for the presence of germline mutations in two MMR genes. The whole coding regions as well as all exon/intron boundaries of *hMLH1* and *hMSH2* were tested with PCR/conformational analysis. We observed 17 different aberrant gel migrations in 29 DNA samples from patients with high

MSI tumours. All 17 alterations were detected as single stranded conformational polymorphisms, one sample also showed altered double stranded conformation, and in two samples heteroduplexes were also formed. Eleven alterations were in *hMLH1* and six in *hMSH2*. Sequencing showed four presumably pathogenic mutations, three in *hMLH1* and one in *hMSH2* (table 1). A new polymorphism IVS9+10A>G in *hMLH1* (allele frequency 0.02) has also been detected (fig 1B, C).

Mutations G67R and I655T in *hMLH1* have been previously reported³¹⁻³² in connection with hereditary bowel cancer, while Q562X has been detected for the first time among Slovenian patients with high MSI CRC tumours. We also detected a germline deletion of three consecutive amino acids from 188-190 in *hMSH2* in a person with a high MSI tumour (OG/97-2426-T). The same mutation was previously found in a Slovenian patient (HNPCC-8-2B) with a family history of CRC.³³ Although these two patients live in different parts of Slovenia and have different family names, a retrospective pedigree search showed common roots two generations back and resulted in the identification of an extensive Slovenian HNPCC pedigree (fig 2). Similarly, other patients with germline mutations were contacted for their family history. All patients with germline mutations accessed via MSI analysis had at least one first degree relative with HNPCC associated cancer.

In this study, we used a molecular genetic approach for identification of HNPCC families. Our approach was based firstly on microsatellite instability (MSI) analysis of newly diagnosed randomly collected CRC and subsequently on mutational analysis of mismatch repair genes (MMR) in MSI positive tumours. We used a solely molecular genetic approach for detecting HNPCC families because (1) a considerable proportion of germline MMR mutations were found in patients from families not fulfilling the Amsterdam criteria,¹³⁻¹⁵ and (2) access to well organised cancer registries is not available in many countries. In Slovenia, a cancer registry exists but it does not contain family data. No specialised registries for hereditary forms of cancer are available. In our first attempt to identify Slovenian HNPCC families, 600 colorectal cancer patients were questioned for their family history data. A total of 44 patients reported at least one first degree relative with CRC and 16 families agreed to contribute blood samples for DNA analysis. Germline mutation was detected in one family only.³³ This approach

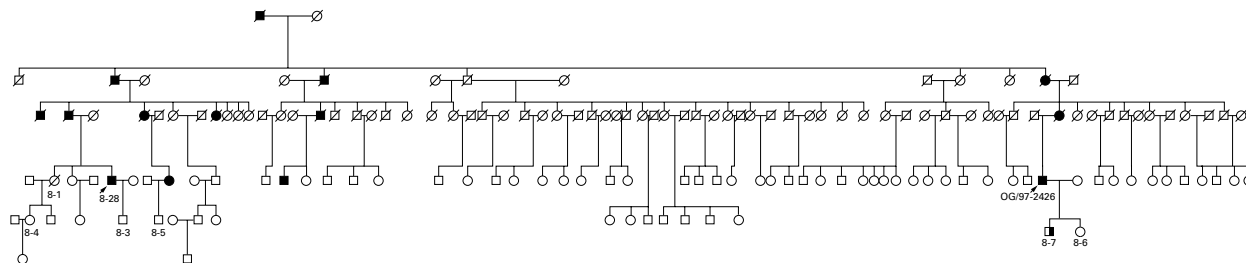


Figure 2 Extended Slovenian HNPCC family with deletion of three amino acids (188-190) in *hMSH2*. We found this germline deletion in a subject with high MSI tumour (OG/97-2426). We also previously detected the same mutation in a Slovenian patient (HNPCC-8-2B) with a family history of CRC.³² A retrospective pedigree search showed common roots of both patients' families two generations back. The resulting extended HNPCC family spans six generations and has 162 family members. Affected members are shaded. Presymptomatic DNA testing identified five non-carriers and one carrier of the mutation (8-7).

showed some inaccuracy of data obtained directly from patients and suggested that epidemiological studies of HNPCC incidence based on patients' answers should be treated with caution.

With a molecular genetic approach, we found germline mutations in four out of 300 newly diagnosed colorectal cancers. These four alterations are unambiguously pathogenic mutations; one is a deletion, one is nonsense, and two are missense mutations. Two mutations are so far specific for Slovenian families: a deletion of codons 188-190 in exon 3 of *hMSH2* (fig 2) and a C to T substitution in exon 15 of *hMLH1* resulting in a stop codon at 562. A substitution of Ile to Thr at codon 655 detected in a patient OG/97-3941 was previously reported in a patient with gastric carcinoma.³² Interestingly, also, Slovenian patient OG/97-3941 had a metachronic gastric cancer two years after colon cancer. The Gln to Arg substitution at codon 67 was previously described in a Swedish HNPCC family³¹ and its pathogenicity was proved in a functional assay in yeast.³⁴

It is possible that we missed some tumours with MMR gene mutation, because we analysed only MSI positive tumours. Cases with MMR mutations without MSI were also reported.¹⁵ However, 1.3% (4/300) tumours with germline MMR gene mutations in the Slovenian population is lower than the 2% observed in a similar study in a Finnish population. If the common ancestral Finnish specific mutation, which accounts for a half of all Finnish HNPCC families,³⁵ is excluded the percentage in our country is even higher than in Finland. No comparison with other populations using a similar approach is currently available. Finnish and Slovenian molecular genetic based estimations of HNPCC incidence are considerably lower than the 5-10% estimated in the majority of epidemiological studies.³⁶ However, Evans *et al*³⁷ also reported the incidence of HNPCC to be 1.4%. Their population based study of 1137 consecutive cases of colorectal cancer showed a lower frequency of familial bowel cancer than previous studies and may reflect a lower incidence of inherited mutations in the HNPCC MMR genes than is currently accepted.³⁷ Since germline mutation in MMR genes is a reliable indicator of HNPCC syndrome, the estimation of incidence of this hereditary disorder in a Slovenian population could be calculated. If we consider 19 000 newborns annually and 850 newly diagnosed colorectal cancer cases annually³⁸ (of which 1.3% have germline MMR gene mutation), the HNPCC incidence in the Slovenian population is approximately 1 in 1700. However, this estimate represents the absolute minimum. It is possible that we missed some mutations because of technical limitations and because we did not analyse three minor genes (*hPMS1*, *hPMS2*, and *hMSH6*), which are also predisposing factors for HNPCC. Another reason for underestimation of the disease frequency might be that we only searched for mutations in patients with colorectal cancer, but this cancer accounts for only approximately two thirds of cancers in HNPCC affected families.³⁹

The proportion of patients younger than 50 years in our study was the same as it is for colorectal cancer patients in the complete National Cancer Registry indicating that there was no bias in overestimation according to age.

With molecular genetic analysis of colorectal cancers, we were able to identify Slovenian families with a hereditary form of CRC. Only patients with germline MMR mutations who wished to be acquainted with the results of DNA testing were further contacted by both a gastroenterologist and a geneticist for future medical surveillance and family history data. Some extended HNPCC pedigrees have thus been detected. Through this study, we succeeded in providing more information about the role of molecular

genetic analysis to general physicians and HNPCC family members. Presymptomatic DNA testing was offered to well informed and consenting non-symptomatic relatives. A prevention programme in the sense of periodic clinical examination of relatives with a constitutional mutation has been initiated. In particular, records of young CRC patients have been re-examined for family and clinical data and additional potential HNPCC families have been identified. This enabled us to initiate building of a national HNPCC registry.

We conclude that a molecular genetic approach with evaluated genetic markers for efficient MSI analysis and subsequent MMR gene analysis of patients with MSI positive tumours is valuable for identification and surveillance of HNPCC families and may serve also as a model for detection of familial cases of CRC in other populations.

The Ministry of Science and Technology of the Republic of Slovenia supported this study (Project J3-7919-0381). The scope of the study was agreed by the Medical Ethical Commission of the Republic of Slovenia in October 1995. We are grateful to the patients who participated in the study. We thank Rastko Golouh and Anton Cerar for patients' tissue samples. We also thank Tomaz Krašovec and Aleš Novak for excellent technical assistance.

METKA RAVNIK-GLAVAČ†
UROŠ POTOČNIK*
DAMJAN GLAVAČ*

*University of Ljubljana, Medical Faculty, Institute of Pathology,
Laboratory of Molecular Genetics, Korytkova 2, 1000 Ljubljana, Slovenia
†Institute of Biochemistry, Medical Faculty, Ljubljana, Slovenia

Correspondence to: Dr Ravnik-Glavač, ravnik@ibmi.mf.uni-lj.si

- Vasen HF, Mecklin JP, Khan PM, Lynch HT. The International Collaborative Group on Hereditary Non-Polyposis Colorectal Cancer (ICG-HNPCC). *Dis Colon Rectum* 1991;34:424-5.
- Vasen HF, Wijnen JT, Menko FH, Kleibeuker JH, Taal BG, Griffioen G, Nagengast FM, Meijers-Heijboer EH, Bertario L, Varesco L, Bisgaard ML, Mohr J, Fodde R, Khan PM. Cancer risk in families with hereditary non-polyposis colorectal cancer diagnosed by mutation analysis (published erratum appears in *Gastroenterology* 1996;111:1402). *Gastroenterology* 1996;110:1020-7.
- Lynch HT, Smyrk TC, Watson P, Lanspa SJ, Lynch JF, Lynch PM, Cavalieri RJ, Boland CR. Genetics, natural history, tumor spectrum, and pathology of hereditary nonpolyposis colorectal cancer: an updated review. *Gastroenterology* 1993;104:1535-49.
- Aarnio M, Mecklin JP, Aaltonen LA, Nystrom-Lahti M, Jarvinen HJ. Life-time risk of different cancers in hereditary non-polyposis colorectal cancer (HNPCC) syndrome. *Int J Cancer* 1995;64:430-33.
- Dunlop MG, Farrington SM, Carothers AD, Wyllie AH, Sharp L, Burn J, Liu B, Kinzler KW, Vogelstein B. Cancer risk associated with germline DNA mismatch repair gene mutations. *Hum Mol Genet* 1997;6:105-110.
- Aaltonen LA, Sankila R, Mecklin JP, Jarvinen H, Pukkala E, Peltomaki P, de la Chapelle A. A novel approach to estimate the proportion of hereditary nonpolyposis colorectal cancer of total colorectal cancer burden. *Cancer Detect Prev* 1994;18:57-63.
- Nicolaides NC, Papadopoulos N, Liu B, Wei YF, Carter KC, Ruben SM, Rosen CA, Haseltine WA, Fleischmann RD, Fraser CM. Mutations of two PMS homologues in hereditary nonpolyposis colon cancer. *Nature* 1994;371:75-80.
- Bronner CE, Baker SM, Morrison PT, Warren G, Smith LG, Lescoe MK, Kane M, Earabino C, Lipford J, Lindblom A. Mutation in the DNA mismatch repair gene homologue hMLH1 is associated with hereditary non-polyposis colon cancer. *Nature* 1994;368:258-61.
- Fisher R, Lescoe MK, Rao MR, Copeland NG, Jenkins NA, Garber J, Kane M, Kolodner R. The human mutator gene homolog MSH2 and its association with hereditary nonpolyposis colon cancer (published erratum appears in *Cell* 1994;77:167). *Cell* 1993;75:1027-38.
- Leach FS, Nicolaides NC, Papadopoulos N, Liu B, Jen J, Parsons R, Peltomaki P, Sistonen P, Aaltonen LA, Nystrom-Lahti M. Mutations of a mutS homolog in hereditary nonpolyposis colorectal cancer. *Cell* 1993;75:1215-25.
- Papadopoulos N, Nicolaides NC, Liu B, Parsons R, Lengauer C, Palombo F, D'Arrigo A, Markowitz S, Willson JK, Kinzler KW. Mutations of GTBP in genetically unstable cells. *Science* 1995;268:1915-17.
- Peltomaki P, de la Chapelle A. Mutations predisposing to hereditary nonpolyposis colorectal cancer. *Adv Cancer Res* 1997;71:93-119.
- Nystrom-Lahti M, Wu Y, Moisio AL, Hofstra RM, Osinga J, Mecklin JP, Jarvinen HJ, Leisti J, Buys CH, de la Chapelle A, Peltomaki P. DNA mismatch repair gene mutations in 55 kindreds with verified or putative hereditary non-polyposis colorectal cancer. *Hum Mol Genet* 1996;5:763-9.
- Liu B, Farrington SM, Petersen GM, Hamilton SR, Parsons R, Papadopoulos N, Fujiiwara T, Jen J, Kinzler KW, Wyllie AH. Genetic instability occurs in the majority of young patients with colorectal cancer. *Nat Med* 1995;1:348-52.
- Farrington SM, Lin-Goerke J, Ling J, Wang Y, Burczak JD, Robbins DJ, Dunlop MG. Systematic analysis of hMSH2 and hMLH1 in young colon cancer patients and controls. *Am J Hum Genet* 1998;63:749-59.
- Parsons R, Li GM, Longley MJ, Fang WH, Papadopoulos N, Jen J, de la Chapelle A, Kinzler KW, Vogelstein B, Modrich P. Hypermutability and mismatch repair deficiency in RER+ tumor cells. *Cell* 1993;75:1227-36.

- 17 Aaltonen LA, Peltomaki P, Leach FS, Sistonen P, Pylkkanen L, Mecklin JP, Jarvinen H, Powell SM, Jen J, Hamilton SR. Clues to the pathogenesis of familial colorectal cancer. *Science* 1993;260:812-16.
- 18 Ionov Y, Peinado MA, Malkhosyan S, Shibata D, Perucho M. Ubiquitous somatic mutations in simple repeated sequences reveal a new mechanism for colonic carcinogenesis. *Nature* 1993;363:558-61.
- 19 Thibodeau SN, Bren G, Schaid D. Microsatellite instability in cancer of the proximal colon. *Science* 1993;260:816-19.
- 20 Liu B, Parsons R, Papadopoulos N, Nicolaides NC, Lynch HT, Watson P, Jass JR, Dunlop M, Wylie A, Peltomaki P, de la Chapelle A, Hamilton SR, Vogelstein B, Kinzler KW. Analysis of mismatch repair genes in hereditary non-polyposis colorectal cancer patients. *Nat Med* 1996;2:169-74.
- 21 Weissenbach J. A second generation linkage map of the human genome based on highly informative microsatellite loci. *Gene* 1993;135:275-8.
- 22 Spirio L, Joslyn G, Nelson L, Leppert M, White R. A CA repeat 30-70 kb downstream from the adenomatous polyposis coli (APC) gene (published erratum appears in *Nucleic Acids Res* 1992;20:642). *Nucleic Acids Res* 1991;19:6348.
- 23 Jones MH, Nakamura Y. Detection of loss of heterozygosity at the human TP53 locus using a dinucleotide repeat polymorphism. *Genes Chrom Cancer* 1992;5:89-90.
- 24 Vanagaite L, James MR, Rotman G, Savitsky K, Bar-Shira A, Gilad S, Ziv Y, Uchenik V, Sartiel A, Collins FS. A high-density microsatellite map of the ataxia-telangiectasia locus. *Hum Genet* 1995;95:451-4.
- 25 Weber JL, Kwitek AE, May PE, Wallace MR, Collins FS, Ledbetter DH. Dinucleotide repeat polymorphisms at the D17S250 and D17S261 loci. *Nucleic Acids Res* 1990;18:4640.
- 26 Dib C, Faure S, Fizames C, Samson D, Drouot N, Vignal A, Millasseau P, Marc S, Hazan J, Seboun E, Lathrop M, Gyapay G, Morissette J, Weissenbach J. A comprehensive genetic map of the human genome based on 5,264 microsatellites. *Nature* 1996;380:152-4.
- 27 Makela TP, Hellsten E, Vesa J, Alitalo K, Peltonen L. An Alu variable polyA repeat polymorphism upstream of L-myc at 1p32. *Hum Mol Genet* 1992;1:217.
- 28 Potočník U, Glavač D, Golouh R, Ravnik-Glavač M. Evaluation of microsatellite markers for efficient assessment of high microsatellite unstable colorectal tumors. *Pflug Arch* (in press).
- 29 Zhou XP, Hoang JM, Cottu P, Thomas G, Hamelin R. Allelic profiles of mononucleotide repeat microsatellites in control individuals and in colorectal tumors with and without replication errors. *Oncogene* 1997;15:1713-18.
- 30 Hoang JM, Cottu PH, Thuille B, Salmon RJ, Thomas G, Hamelin R. BAT-26, an indicator of the replication error phenotype in colorectal cancers and cell lines. *Cancer Res* 1997;57:300-3.
- 31 Tannergard P, Lipford JR, Kolodner R, Frodin JE, Nordenskjöld M, Lindblom A. Mutation screening in the hMLH1 gene in Swedish hereditary nonpolyposis colon cancer families. *Cancer Res* 1995;55:6092-6.
- 32 Keller G, Grimm V, Vogelsang H, Bischoff P, Mueller J, Siewert JR, Hofer H. Analysis for microsatellite instability and mutations of the DNA mismatch repair gene hMLH1 in familial gastric cancer. *Int J Cancer* 1996;68:571-6.
- 33 Ravnik-Glavač M, Potočník U, Kozelj M, Krizman I, Glavač D. A novel in frame deletion of codons 188-190 in the hMSH2 gene of a Slovenian patient with hereditary non-polyposis colorectal cancer. *Hum Hered* 1998;48:285-7.
- 34 Shimodaira H, Filosi N, Shibata H, Suzuki T, Radice P, Kanamaru R, Friend SH, Kolodner RD, Ishioka C. Functional analysis of human MLH1 mutations in *Saccharomyces cerevisiae*. *Nat Genet* 1998;19:384-9.
- 35 Aaltonen LA, Salovaara R, Kristo P, Canzian F, Hemminki A, Peltomaki P, Chadwick RB, Kaariainen H, Eskelinen M, Jarvinen H, Mecklin JP, de la Chapelle A. Incidence of hereditary nonpolyposis colorectal cancer and the feasibility of molecular screening for the disease. *N Engl J Med* 1998;338:1481-7.
- 36 Lynch HT, Lynch J. Genetics, natural history, surveillance, management, and gene mapping in the Lynch syndrome. *Pathol Biol* 1995;43:151-8.
- 37 Evans DG, Walsh S, Jeacock J, Robinson C, Hadfield L, Davies DR, Kingston R. Incidence of hereditary non-polyposis colorectal cancer in a population-based study of 1137 consecutive cases of colorectal cancer. *Br J Surg* 1997;84:1281-5.
- 38 Golouh R, Lindtner J, Pompe Kirn V, Zakelj Primic M, Ravnihar B, Rudolf Z, Zakotnik B, eds. *Cancer incidence in Slovenia*. Report No 37. Institute of Oncology, Ljubljana, 1998:22.
- 39 Mecklin JP, Svendsen LB, Peltomaki P, Vasen HF. Hereditary nonpolyposis colorectal cancer. *Scand J Gastroenterol* 1994;29:673-7.

J Med Genet 2000;37:536-539

Does the survival motor neuron protein (SMN) interact with Bcl-2?

EDITOR—Spinal muscular atrophy (SMA) is an autosomal recessive disease resulting from mutations in the telomeric copy of the survival motor neuron gene (*SMN1*),¹⁻⁷ which results in reduced expression of the survival of motor neuron protein (SMN).⁴⁻⁷ The SMN protein is ubiquitously expressed but is found at high levels in motor neurons.^{4-7,8} The SMN protein associates with Sm proteins,⁹⁻¹⁰ SIP-1 protein,⁹⁻¹⁰ and itself.⁸⁻¹¹ SMN is found in structures termed gems⁸ that are associated with coiled bodies in the nucleus. The SMN protein is involved in RNA biogenesis¹⁰ and is important for the maturation of a functional snRNP complex that performs splicing.¹² The complete loss of SMN is lethal¹³ whereas the low levels of SMN found in SMA cause loss of the motor neurons.⁴⁻⁷ The mechanism by which the reduction of SMN protein results in the loss of motor neurones is unknown. Some groups have suggested it occurs by apoptosis.¹⁴⁻¹⁵ Apoptosis is a conserved, highly regulated mechanism of non-chronic cell death for the removal of surplus, aged, or damaged cells.¹⁵ Apoptosis is regulated by the interactions of apoptosis agonists and antagonist with the Bcl-2 protein being one of the key inhibitors of apoptosis.¹⁶

Recently Iwahashi *et al.*¹⁷ have suggested a direct interaction between SMN and Bcl-2 using transfected constructs. In an effort to confirm and extend their results, we have attempted to coimmunoprecipitate SMN and Bcl-2 both in a native environment and using transfected cells. The SMN protein and Bcl-2 are expressed in Jurkat cells and in spinal cord. Jurkat cells are a human lymphoblast T cell line that has been previously shown to express Bcl-2 and can be induced to undergo apoptosis.¹⁸⁻¹⁹

Immunoprecipitation experiments were performed using two different methods.¹⁷⁻²⁰ Fig 1A shows a western blot of the immunoprecipitation reactions using the

method of Iwahashi *et al.*¹⁷ Jurkat cell lysate was precipitated with anti-SMN (MANSMA2), anti-Bcl-2 (Bcl-2(100)), and anti-dystrophin (MANDYS-1) monoclonal antibodies. The precipitated proteins were western blotted and probed with anti-SMN or anti-Bcl-2 polyclonal antibodies. As shown in fig 1A-1, anti-SMN polyclonal antibody SMN-C3 detects SMN only in the immunoprecipitation using anti-SMN monoclonal antibody MANSMA2 and not in the immunoprecipitation reaction using anti-Bcl-2 monoclonal Bcl-2(100). The reciprocal experiment is shown in fig 1A-2 in which the blot is probed with anti-Bcl-2 polyclonal antibody Bcl-2 (Δ C21). Bcl-2 is detected only in the immunoprecipitation reaction using Bcl-2(100) but not in the sample immunoprecipitated with MANSMA2. The blots were stripped and re-probed with the anti-Bag-1 (fig 1A-3) and anti-Sm antibody Y12 (fig 1A-4). Sm proteins and Bag-1 have been previously shown to interact with SMN and Bcl-2 respectively and act as controls for the immunoprecipitation procedure.^{8,21} The expected results were obtained with Bcl-2 antibodies immunoprecipitating Bag-1 and SMN antibodies precipitating Sm proteins. Similar results were obtained using Jurkat cells undergoing apoptosis after induction with phytohaemagglutinin (data not shown).

In normal spinal cord (fig 1B), SMN-C3 detects a 38 kDa band in the immunoprecipitation reaction using MANSMA2 but not in the immunoprecipitation reactions using Bcl-2(100) or MANDYS-1. Similarly, in the reciprocal experiment, the anti-Bcl-2 rabbit polyclonal antibody Bcl-2 (Δ C21) detects a 29 kDa band only in the sample immunoprecipitated with Bcl-2(100) and not in the other immunoprecipitation reactions.

As immunoprecipitation experiments failed to show a direct interaction of native SMN and Bcl-2 in proliferating and apoptotic Jurkat cells and in spinal cord, we investigated cells transfected with SMN/Bcl-2 expression constructs. We have prepared various SMN expression constructs with or without the HA epitope tag at the amino-terminus. Immunoprecipitations were performed

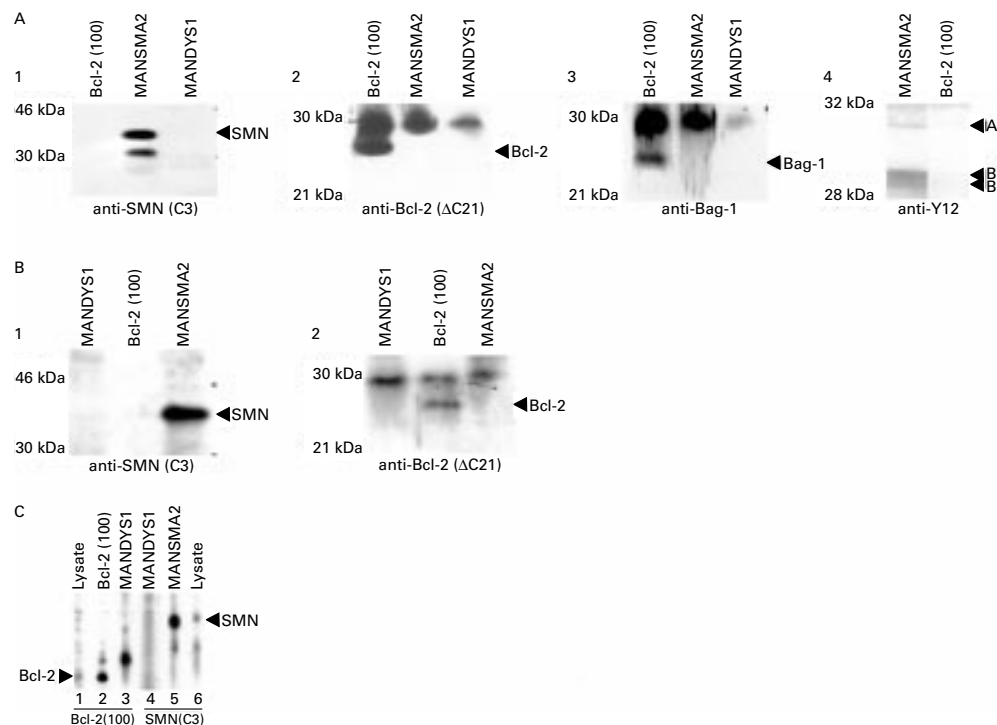


Figure 1 (A). Endogenous SMN and Bcl-2 are not coimmunoprecipitated from Jurkat cells. Shown is a western blot of proteins immunoprecipitated with anti-Bcl-2 (Bcl-2(100)), anti-SMN (MANSMA2), and control (MANDYS-1)²² monoclonal antibodies. The western blot was serially probed with the antibodies shown below the blot as previously described.⁷ 1 SMN protein (arrow), as detected with anti-SMN chicken polyclonal antibody C3,⁷ is immunoprecipitated with MANSMA2 and not coimmunoprecipitated with Bcl-2. 2 Bcl-2 protein (arrow), as detected with the anti-Bcl-2 polyclonal antibody Bcl-2(ΔC21), is immunoprecipitated with the Bcl-2(100), but is not coimmunoprecipitated with SMN. The 30 kDa band present in all three lanes is non-specific and is probably the IgG light chain, as previously reported.¹⁷ 3 Bag-1 protein, which is known to associate with Bcl-2, is coimmunoprecipitated only with Bcl-2. This indicates immunoprecipitation conditions were suitable to precipitate associated proteins. 4 SM proteins coprecipitate with SMN as detected with anti-SM polyclonal antibody Y12 as previously reported and are not immunoprecipitated with Bcl-2. This also shows conditions were suitable to precipitate associated proteins. (B) Endogenous SMN and Bcl-2 are not coimmunoprecipitated from non-SMA spinal cord. Shown is a western blot of spinal cord proteins immunoprecipitated with anti-Bcl-2 (Bcl-2(100)) (lane 2), anti-SMN (MANSMA2), and control (MANDYS-1) monoclonal antibodies. The western blot was serially probed with the antibodies shown below the blot. 1 SMN is detected only in the sample precipitated with MANSMA2 and is not coprecipitated with Bcl-2. 2 The reciprocal experiment shows Bcl-2 is precipitated only with Bcl-2(100) and is not coimmunoprecipitated with SMN. (C) Western blot of unprecipitated Jurkat cell lysate and immunoprecipitations probed with anti-Bcl-2 (Bcl-2(100)) and anti-SMN (SMN C3) antibodies. Methods. Approximately 1.5×10^8 cells from subconfluent cultures were lysed with 1 ml of ice cold lysis buffer.^{17, 20} The lysate was preclarified by incubating the lysate with washed Omnisorb cells (Calbiochem) for 30 minutes on ice. The Omnisorb cells were removed by centrifugation, and the preclarified lysate was divided into 3 aliquots of 300 μ l each. Approximately 1 μ g of anti-SMN (MANSMA2) was added to the first aliquot, 1 μ g of Bcl-2 (100) monoclonal (Santa Cruz Biotechnology, Santa Cruz, CA) was added to the second aliquot, and 1 μ g of the anti-dystrophin MANDYS-1 hybridoma supernatant was added to the last aliquot. MANDYS-1 was made from the same myeloma cell line used to make MANSMA2. The antibodies were rocked on ice with the lysate for one hour to overnight. Immune complexes were captured with protein G sepharose (Sigma). Briefly, 40 μ l of a 50% suspension of protein G sepharose was washed with 1 ml of lysis buffer. The protein G sepharose was pelleted and the pellet resuspended with the lysate. The lysate was rocked on ice for 30 minutes. The protein G sepharose was washed with 1 ml of lysis buffer five times for five minutes on ice. The residual wash buffer was removed by aspiration and sepharose was boiled in 30 μ l of SDS buffer for two minutes. The samples were resolved by SDS-PAGE on 12% gels as described previously.⁷ Spinal cord collected from a type I SMA and a non-SMA subject was dissected and ground into a fine powder in liquid nitrogen using a mortar and pestle. The powder was dissolved in 1 ml of Empigen BB (1% Empigen BB, 5 mmol/l EDTA, 1 mmol/l PMSE, 5 mmol/l DTT, and 100 mmol/l Tris, pH 8, 10 μ mol/l aprotinin, 1 μ mol/l leupeptin, 1 μ mol/l pepstatin A)²⁰ or the Iwahashi lysis buffer.¹⁷ The insoluble material was removed by centrifugation and immunoprecipitations carried out on the supernatant as described above.

on the transfected cells using an HA epitope monoclonal and the Bcl-2 antibodies described above. The HA antibodies resulted in immunoprecipitation of SMN and not Bcl-2 whereas Bcl-2 antibodies immunoprecipitated Bcl-2 alone (fig 2A). The transfection studies provided no evidence for interaction of SMN and Bcl-2.

Dual labelling of COS-7 cells cotransfected with SMN and HA tagged SIP-1 expression constructs shows SMN and SIP-1 are colocalised as previously reported (fig 2B).⁹ Dual labelling of SMN and Bcl-2 using cotransfection of a HA tagged SMN expression construct and a Bcl-2 expression construct failed to show convincing colocalisation of SMN and Bcl-2 in either COS-7 (fig 2C) or HeLa cells (not shown). As seen in fig 2C, in the cotransfected cell Bcl-2 is expressed abundantly throughout the cytoplasm. Similarly, overexpressed SMN is located in gems, cytoplasmic particles, and throughout the cytoplasm. Even under these conditions of extreme overexpression, there is no clear example of colocalisation, as would be expected if they associate. The apparent associ-

ation of diffuse staining of SMN and Bcl-2 in the cytoplasm most likely arises from overlapping expression distributions as supported by the immunoprecipitation results.

Although we cannot exclude the possibility that SMN and Bcl-2 interact indirectly with each other in cell death pathways, these results strongly indicate that SMN and Bcl-2 do not directly interact in vivo. It is most likely that the high expression levels in the experiments of Iwahashi *et al*¹⁷ resulted in artefactual aggregation of Bcl-2 and SMN and that this interaction does not exist in vivo. In order to show clearly a synergistic effect of Bcl-2 and SMN either by direct or indirect mechanisms, it is important to eliminate the possibility that transfection of SMN increases Bcl-2 levels. It appears most likely that the reduction in SMN levels results in inefficient splicing which leads to a reduction or accumulation of a critical product that causes death of the motor neurons.

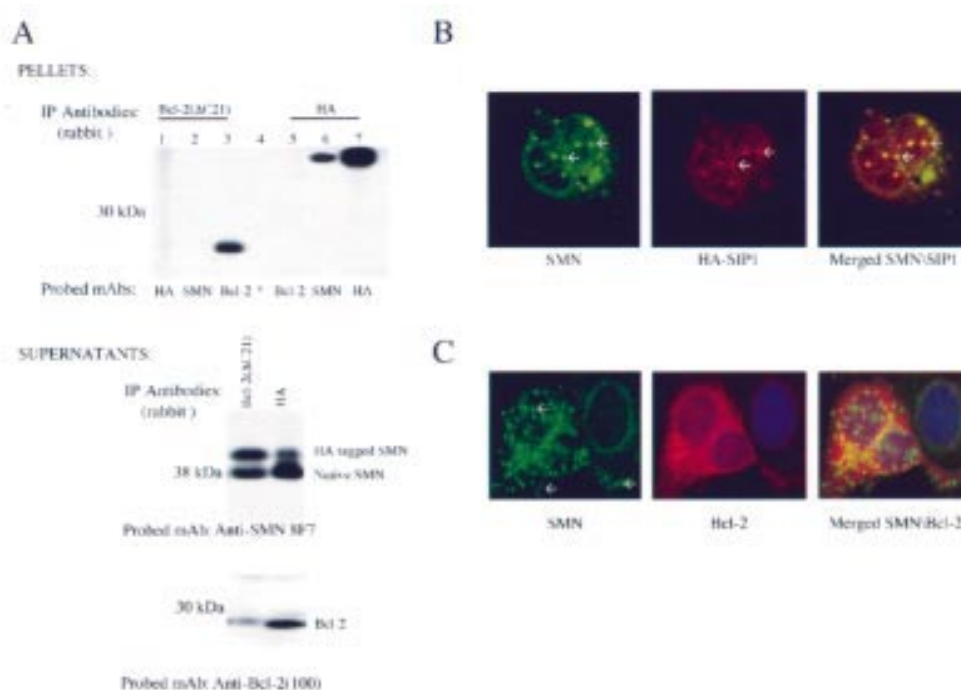


Figure 2 (A) Immunoprecipitation of transiently transfected HA tagged SMN and Bcl-2 from COS-7 cells. COS-7 cells, transiently cotransfected with Bcl-2 and HA tagged SMN expression constructs, were immunoprecipitated using rabbit anti-Bcl-2 polyclonal (lanes 1-3) and rabbit anti-HA (lanes 5-7) polyclonal antibody as indicated above the blot. As indicated below the blot, lanes 1 and 7 were probed with anti-HA monoclonal antibody. Lanes 2 and 6 were probed with anti-SMN monoclonal antibody MANSMA2. Lanes 3 and 5 were probed with anti-Bcl-2(100) monoclonal antibody. As seen in lanes 1 and 2, HA-SMN is not coprecipitated when using the anti-Bcl-2 polyclonal antibody. In the reciprocal experiment (lane 5), Bcl-2 is not coimmunoprecipitated with HA-SMN. The middle and lower panels show western blots of the proteins remaining in the supernatants following the immunoprecipitation reactions. These are included to indicate the relative levels of Bcl-2, SMN, and HA-SMN expression in the transfected cells. Additionally, neither SMN nor HA-SMN are depleted from the supernatant incubated with anti-Bcl-2 polyclonal antibody (middle panel), but Bcl-2 is depleted (bottom panel). The reciprocal experiment shows only HA-SMN is depleted by the anti-HA monoclonal antibody (middle panel), but neither SMN nor Bcl-2 (bottom panel) is depleted. (B) Immunofluorescent detection of SMN and HA tagged SIP-1 in transiently cotransfected COS-7 cells. SMN (left panel), indirectly labelled with an FITC conjugated antibody, is located in gems, cytoplasmic particles, and diffusely in the cytoplasm. HA tagged SIP-1 (middle panel), indirectly labelled with TRITC conjugated antibodies, shows a similar distribution pattern. Merging the left and middle images (right panel) clearly shows the association of SMN and SIP1 as previously reported.⁹ (C) Dual labelling of HA tagged SMN and Bcl-2 detected with anti-HA polyclonal and anti-Bcl-2 monoclonal antibodies. SMN (left panel), indirectly labelled with an FITC conjugated antibody, is localised in gems, cytoplasmic particles, and faint diffuse staining (green indicated by arrows). Bcl-2 (middle panel), indirectly labelled with a TRITC conjugated secondary antibody, is expressed throughout the cytoplasm (red, diffuse fluorescence). In contrast to the SIP-1/SMN merged image above, the merged image (right panel) indicates a lack of colocalisation of SMN and Bcl-2. **Methods.** COS-7 cells (~10⁶) were seeded onto coverslips and prepared as described previously.⁷ Bcl-2(100) and Bcl-2(AC21) (Santa Cruz Biotechnology Inc) and anti-HA polyclonal antibody (BabCO) were used at 1/500 dilution. The secondary antibodies, rabbit anti-haemagglutinin antibody conjugated to TRITC (Sigma) and donkey anti-chicken F(ab)₂ antibody conjugated to FITC (Jackson ImmunoResearch) were used at 1/400 dilution. SIP-1 cDNA was ligated to haemagglutinin (HA) tag and subcloned into the pcDNA3 vector. Bcl-2 was subcloned into pcDNA3 vector. DNA plasmids were prepared for transfection using Endo Free Plasmid Kit (Qiagen). COS-7 cells were transfected with lipofectamine (Life Technologies) according to the manufacturer's instructions. Images were obtained using a Zeiss microscope equipped with an Optronics colour digital camera using FITC and TRITC/DAPI double pass filters. Total magnification of images is 945x.

This work was funded by MDA, Families of SMA, and the Preston Fund, and NIH grant NS 38650.

DANIEL D COOVERT*†
THANH T LE*†
GLENN E MORRIS‡
NGUYEN THI MAN‡
MARTINA KRALEWSKI§
MICHAEL SENDTNER§
ARTHUR H M BURGHESES*¶

*Department of Medical Biochemistry, Ohio State University, College of Medicine, Columbus OH 43210, USA

‡MRIC Biochemistry Group, NE Wales Institute, Wrexham, UK

§Department of Neurology, University of Wurzburg, 97080 Wurzburg, Germany

¶Department of Neurology Ohio State University, College of Medicine and Dept of Molecular Genetics, College of Biological Sciences, Columbus, OH 43210, USA

Correspondence to: Dr Burghes, Department of Medical Biochemistry, 363 Hamilton Hall, 1645 Neil Avenue, Columbus, OH 43210, USA, burghes.1@osu.edu

†These authors contributed equally to this work.

- Crawford TO. From enigmatic to problematic: the new molecular genetics of childhood spinal muscular atrophy. *Neurology* 1996;**46**:335-40.
- Burghes AHM. When is a deletion not a deletion? When it is converted. *Am J Hum Genet* 1997;**61**:9-15.
- Lefebvre S, Burglen L, Reboullet S, et al. Identification and characterization of a spinal muscular atrophy-determining gene. *Cell* 1995;**80**:155-65.

- Lefebvre S, Burtel P, Liu Q, et al. Correlation between severity and SMN protein level in spinal muscular atrophy. *Nat Genet* 1997;**16**:265-9.
- McAndrew PE, Parsons DW, Simard LR, et al. Identification of proximal spinal muscular atrophy carriers and patients by analysis of SMN^T and SMN^C gene copy number. *Am J Hum Genet* 1997;**60**:1411-22.
- Parsons DW, McAndrew PE, Monani UR, Mendell JR, Burghes AHM, Prior TW. An 11 bp duplication in exon 6 of the SMN gene produces a type I spinal muscular atrophy (SMA) phenotype: further evidence for SMN as the primary SMA-determining gene. *Hum Mol Genet* 1996;**5**:1727-32.
- Coovert D, Le TT, McAndrew P, et al. The survival motor neuron protein in spinal muscular atrophy. *Hum Mol Genet* 1997;**6**:1205-14.
- Liu Q, Dreyfuss G. A novel nuclear structure containing the survival of motor neurons protein. *EMBO J* 1996;**15**:3555-65.
- Liu Q, Fischer U, Wang F, Dreyfuss G. The spinal muscular atrophy disease gene product, SMN, and its associated protein SIP1 are in a complex with spliceosomal snRNP proteins. *Cell* 1997;**90**:1013-21.
- Fischer U, Liu Q, Dreyfuss G. The SMN-SIP1 complex has an essential role in spliceosomal snRNP biogenesis. *Cell* 1997;**90**:1023-9.
- Lorson CL, Strasswimmer J, Yao JM, et al. SMN oligomerization defect correlates with spinal muscular atrophy severity. *Nat Genet* 1998;**19**:63-6.
- Pellizzoni L, Kataoka N, Charroux B, Dreyfuss G. A novel function for SMN, the spinal muscular atrophy disease gene product, in pre-mRNA splicing. *Cell* 1998;**95**:615-24.
- Schrank B, Gotz R, Gunnerson J, et al. Inactivation of the survival motor neuron gene, a candidate gene for human spinal muscular atrophy, leads to massive cell death in early mouse embryos. *Proc Natl Acad Sci USA* 1997;**94**:9920-25.
- Roy N, Mahadevan MS, McLean M, et al. The gene for neuronal apoptosis inhibitory protein is partially deleted in individuals with spinal muscular atrophy. *Cell* 1995;**80**:167-78.
- Mazarakis ND, Edwards AD, Mehmet H. Apoptosis in neural development and disease. *Arch Dis Child Fetal & Neonatal Ed* 1997;**77**:F165-70.
- Adams JM, Cory S. The Bcl-2 protein family: arbiters of cell survival. *Science* 1998;**281**:1322-6.

- 17 Iwahashi H, Eguchi Y, Yasuhara N, Hanafusa T, Matsuzawa Y, Tsujimoto Y. Synergistic anti-apoptotic activity between Bcl-2 and SMN implicated in spinal muscular atrophy. *Nature* 1997;390:413-17.
- 18 Bazar LS, Deeg HJ. Ultraviolet B-induced DNA fragmentation (apoptosis) in activated T-lymphocytes and Jurkat cells is augmented by inhibition of RNA and protein synthesis. *Exp Hematol* 1992;20:80-6.
- 19 Ruiz-Ruiz MC, Oliver FJ, Izquierdo M, Lopez-Rivas A. Activation-induced apoptosis in Jurkat cells through a myc-independent mechanism. *Mol Immunol* 1995;32:947-55.
- 20 Choi YD, Dreyfuss G. Monoclonal antibody characterization of the C proteins of heterogeneous nuclear ribonucleoprotein complexes in vertebrate cells. *J Cell Biol* 1984;99:1997-204.
- 21 Takayama S, Sato T, Krajewski S *et al.* Cloning and functional analysis of BAG-1: a novel Bcl-2-binding protein with anti-cell death activity. *Cell* 1995;80:279-84.
- 22 Man N, Cartwright AJ, Morris GE, Love D, Bloomfield JF, Davies KE. Monoclonal antibodies against defined regions of the muscular dystrophy protein, dystrophin. *FEBS Lett* 1990;262:237-40.

J Med Genet 2000;37:539-542

Novel mutations in the homogentisate-1,2-dioxygenase gene identified in Slovak patients with alkaptonuria

EDITOR—Alkaptonuria (AKU, McKusick No 203500), a rare autosomal recessive disorder (1:250 000),¹ is a classical example of a specific biochemical lesion leading to degenerative disease. As a result of deficiency of homogentisic acid 1,2-dioxygenase activity (HGO, E.C. 1.13.11.5), AKU patients are unable to degrade homogentisic acid (HGA), an intermediary metabolite in phenylalanine and tyrosine catabolism.² Accumulated HGA is excreted into the urine in large amounts, which darkens on standing. Over the years, benzoquinone acetic acid, an oxidation product of HGA, is deposited in connective tissues, causing their pigmentation (ochronosis), which leads to painful and disabling arthropathy of the large joints and spine (ochronotic arthropathy).

AKU was the first disease interpreted in terms of Mendelian inheritance.³ The *HGO* gene in humans is located on chromosome 3q21-23.⁴⁻⁵ Fernandez-Canon *et al*⁶ cloned the human *HGO* gene and by identifying the first loss of function mutations also provided formal proof that AKU results from a defect in this gene. So far, 24 different mutations have been identified in the *HGO* gene in patients from various populations.⁵⁻¹⁰

Notable exceptions to the low prevalence of AKU in all ethnic groups studied are the Dominican Republic and Slovakia (1:19 000).^{11,12} Founder effects as the consequence of genetic isolation have been postulated to explain this observation. Here, we present results of mutation screening of the *HGO* gene in 32 AKU chromosomes carried by 17 Slovak AKU patients (in two families, one chromosome was shared by two patients from different generations). All 14 exons of the *HGO* gene were amplified from genomic DNA, using PCR primers and conditions as described by Fernandez-Canon *et al*.⁶ PCR products were analysed for the presence of mutations by non-radioactive single strand conformation polymorphism analysis (SSCP).¹³ DNA was visualised by

silver staining essentially as described by Budowle *et al*.¹⁴ Fragments showing SSCP shifts were sequenced directly using the dye terminator cycle sequencing kit (Perkin Elmer) with *Taq* FS DNA polymerase. Sequences were resolved on an ABI-310 Automatic Analyser.

In our patients, we identified nine different mutations (tables 1 and 2). Four of them were novel mutations, two missense (S47L, G270R), a frameshift (P370fs), and a splice site mutation (IVS5+1G→A), increasing the total number of known AKU causing nucleotide changes within the *HGO* gene to 28. The remaining five mutations have been described previously: G161R and G152fs,⁶ P230S and V300G,^{5,7} and IVS1-1G→A.⁹

Novel mutation S47L is caused by a transition C→T at the second position of codon 47 (fig 1A). This transition abolishes a restriction site for *Mbo*I in exon 3 PCR fragments. The presence of the S47L mutation in our patient was confirmed by *Mbo*I digestion (fig 2A).

Mutation G270R is caused by transition G→A at the first position of codon 270, which creates a novel *Eco*NI restriction site (fig 1C). Therefore, its presence in our patients was confirmed by restriction digestion of exon 11 PCR fragments with *Eco*NI (fig 2B). Glycine at position 270, affected by this mutation, is conserved in man, mouse, and *Aspergillus nidulans* (fig 3).

Splice site mutation IVS5+1G→A affects the donor splice sites of intron 5 (fig 1B). Interestingly, Beltran-Valero de Bernabé *et al*⁹ identified in one patient from Holland a transversion G→T affecting the same position of intron 5 as our mutation IVS5+1G→A. This mutation, however, was not identified in our patients.

Mutation IVS1-1G→A⁹ abolishes restriction sites for *Rsa*I, so the presence of this mutation on one AKU chromosome was confirmed by restriction analysis of the corresponding PCR fragment with this enzyme (fig 2A).

A novel P370fs frameshift mutation, caused by a single base insertion c1273insC (fig 1D), brings about a premature translation stop four codons downstream and subsequent

Table 2 Genotypes of all analysed AKU patients from 15 families indicating identified disease causing mutations within the *HGO* gene

Patient No	Family code	<i>HGO</i> mutations	
		Allele 1	Allele 2
1	ALK1	G152fs	V300G
2	ALK2	IVS5+1G→A	G152fs
3	ALK2	IVS5+1G→A	IVS5+1G→A
4	ALK3	G152fs	P370fs
5	ALK4	G270R	P370fs
6	ALK5	G270R	P370fs
7	ALK6	IVS1-1G→A	P370fs
8	ALK7	G152fs	G152fs
9	ALK8	G161R	P370fs
10	ALK9	S47L	G161R
11	ALK11	G161R	G270R
12	ALK12	G152fs	G152fs
13	ALK13	G152fs	G270R
14	ALK13	G152fs	G161R
15	ALK14	G161R	G161R
16	ALK15	G161R	G161R
17	ALK16	P230S	P230S

Table 1 List and frequencies of the mutations identified in 32 AKU chromosomes from Slovak patients. Positions of nucleotide changes are related to the transcription start site as described in Granadino *et al*.¹⁵ (Human *HGO* transcript: AF 045167; the ATG initiation codon is located at position c168)

Mutation	Type	Nucleotide change	No and % of chromosomes (out of 32)	Reference
IVS 1-1 G→A	Splice site	c183-1G→A	1 (3.125%)	9
S 47 L	Missense	c307 C→T	1 (3.125%)	Present report
IVS 5+1 G→A	Splice site	c509+1 G→A	2 (6.25%)	Present report
G 152 fs	Frameshift	c621 ins G	8 (25%)	6
G 161 R	Missense	c648 G→A	8 (25%)	6
P 230 S	Missense	c855 C→T	2 (6.25%)	5
G 270 R	Missense	c975 G→A	4 (12.5%)	Present report
V 300 G	Missense	c1066 T→G	1 (3.125%)	5
P 370 fs	Frameshift	c1273 ins C	5 (15.625%)	Present report

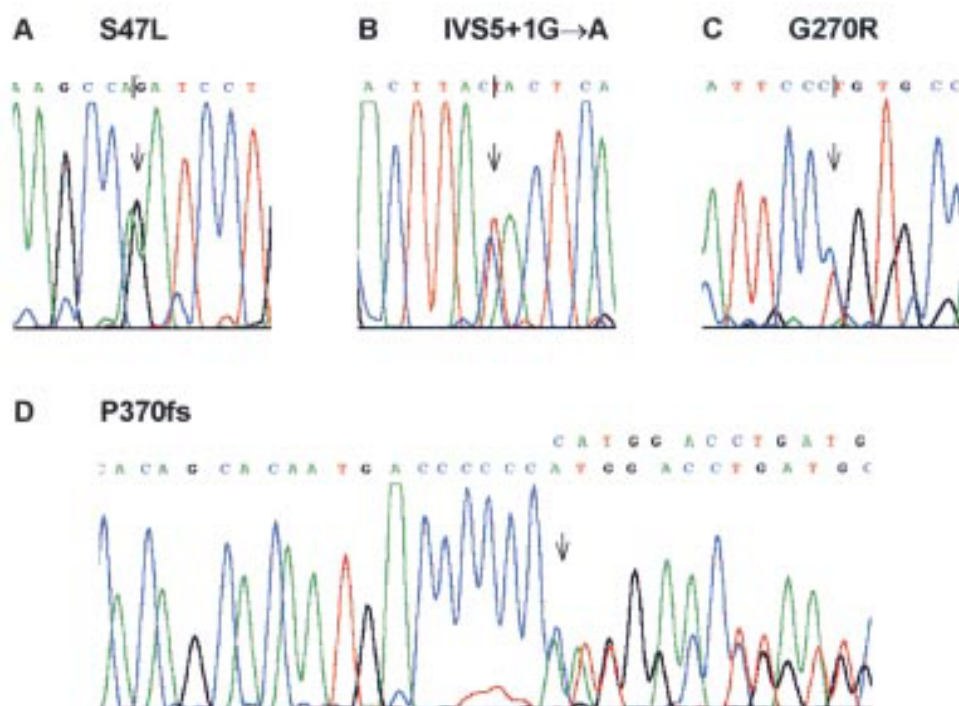


Figure 1 Part of the direct sequencing of exons 3 (A), 5 (B), 11 (C), and 13 (D) in patients heterozygous for mutations S47L, IVS5+1G→A, G270R, and P370fs, respectively (ABI 310, Perkin Elmer). In the case of exons 3, 5, and 11, reverse primers were used.

shortening of translated HGO protein from 445 to 373 amino acids.

The novel mutations were not identified in any of the 50 healthy controls, supporting the evidence that they are disease causing mutations, rather than polymorphisms.

Segregation of all mutations with AKU was confirmed in all families, except for the S47L mutation, where no DNA from family members was available (fig 4). However, serine at position 47 of the HGO protein molecule is conserved in man and mouse (fig 3). In *Aspergillus nidulans*, threonine is found at this site, which, as well as serine, belongs to the group of hydrophilic amino acids with uncharged polar side chains that are usually on the outside of the protein. Conversely, leucine, which is introduced into the HGO protein by transition c307C→T, is an amino acid with non-polar side chains that tend to cluster together on the inside of proteins. This indicates that substitution S47L

may influence the HGO protein conformation and therefore also affect its function.

Recently, Beltran-Valero de Bernabé *et al*⁹ provided the evidence that the CCC triplet or its inverted complement (GGG) are mutational hotspots in the *HGO* gene, because 34.5% (10/29) of *HGO* nucleotide changes identified so far involve these sequence motifs. Data shown in our report further support their finding, since 55.5% (5/9) of the mutations identified in our patients lie within or are adjacent to these triplets. Taking into account the novel mutations found in Slovak patients and one identified by Felbor *et al*,¹⁰ the total number of *HGO* nucleotide variations involving the CCC/GGG motif identified so far can be increased to 38.2% (13/34).

In all 17 analysed Slovak AKU patients, both disease causing mutations were found (table 2). The identification of nine different mutations in this sample was not expected

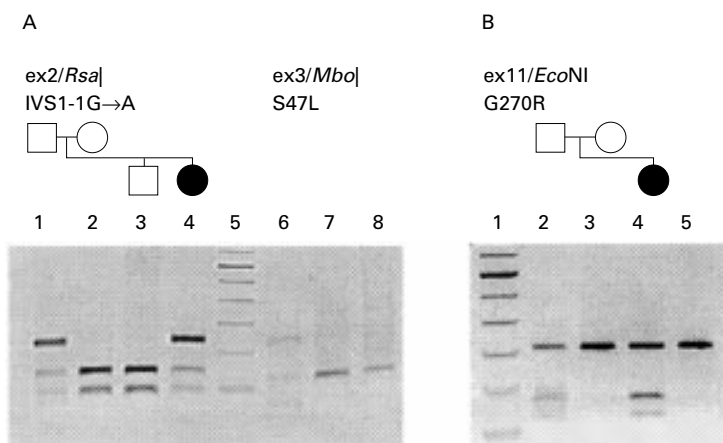


Figure 2 Detection of the (A) IVS1-1G→A, S47L (c307C→T) and (B) G270R (c975G→A) mutations by *RsaI*, *MboI*, and *EcoNI* restriction analysis, respectively. Mutations IVS1-1G→A and S47L abolish restriction sites for corresponding enzymes, while G270R creates a novel site for *EcoNI*. The figure also shows segregation of mutations IVS1-1G→A in family ALK6 (A) and G270R in family ALK4 (B). In both families, the fathers and affected daughters are heterozygous for screened mutations ((A) lanes 1 and 4, (B) lanes 2 and 4, as well as the patient in (A) lane 6). In (A) lanes 2, 3, 7, and 8 and (B) lanes 3 and 5 are subjects without corresponding mutations. In (A) lane 5 and (B) lane 1 is a 100 bp ladder.


```

HGO      -----MAELKYISGFGNECSSEDPKPCGSLPEGQNNPQVCPYNLYAEQL
MHGO     -----MAELKYISGFGNECASEDPKPCGSLPEGQNNPQVCPYNLYAEQL
HMGA     MPVTEFSFKDPYTYQNGFDSYHESEAELEGALPVGHNSPQKAPYGLYAEKL
          *      *      *      *      *      *      *      *      *
          ↓ HGO S47L
HGO      SGSAFTCPRSTNKRSWLYRILPFSVSHKPFESIDEG--HVTHNWDEVDPDF
MHGO     SGSAFTCPRNTNKRSWLYRILPFSVSHKPFESIDQG--HVTHNWDEVGPDF
HMGA     SGTAFATAPRHENKQTWVYRILPAAAHENFVEEDASSYHTLSDAKKLQHIP
          * * * * * * * * * * * * * * * * * * * * * * * * * * *
          ↓ HGO G161R
HGO      ENRCFYNSDGDFLIVPQKGNLLIYTEFGKMLVQNEICVIQRGMRFSDIV
MHGO     ENRCFYNSDGDFLIVPQKGLLIYTEFGKMSLQNEICVIQRGMRFSDIV
HMGA     GKEAFYSADGDFLIVAQHGVLDIQTELGRLVLRPNEICVIQRGMRFSDIV
          * * * * * * * * * * * * * * * * * * * * * * * * * * *
          ↓ HGO P230S
HGO      FE-ETRGYILEVYGVHFEPLDLPVIGANGLANPRDFLIPVWYEDRQVPG
MHGO     FE-ETRGYILEVYGVHFEPLDLPVIGANGLANPRDFLIPVWYEDRVRPG
HMGA     PDGPFVRYICELYQGHYQLPELGPVIGSNGLANARDFQAEVAFDDEEGPT
          * * * * * * * * * * * * * * * * * * * * * * * * * * *
          ↓ HGO G270R
HGO      GYTVINKYQKGLFAAQDVSFPNVVAWHGNYTPYKYNLKNFMVINSVAFD
MHGO     GYTVINKYQKGLFAAQDVSFPNVVTHGNYTPYKYNLENFMVINAVAFD
HMGA     EYRLYSKFNHLSARQDHTPFDIVAWHGNYYPYKYDLGRFNTMGSVSFD
          *      *      *      *      *      *      *      *      *
          ↓ HGO V300G
HGO      HADPSIFTVLTAKSVRPGVAIADFVIFPPRWGVADKTFRPPYHRCMSE
MHGO     HADPSIFTVLTAKSLRPGVAIADFVIFPPRWGVADKTFRPPYHRCMSE
HMGA     HPDPSIYTVLTGPSDHVGTAIADFVIFPPRWLVAEKTFRPPYHRCMSE
          * * * * * * * * * * * * * * * * * * * * * * * * * * *
HGO      FMGLIRGHYEAKQGG-FLPGGSLHSTMTPHGPDADCFEKASKVKLAPER
MHGO     FMGLIKGHYEAKQGG-FLPGGSLHSAAMTPHGPDADCFEKASKAKLEPER
HMGA     FMGLITGNYDAKTGGGFQAGASLHNIMSAGHPDMHAFEGASNADLKPTK
          * * * * * * * * * * * * * * * * * * * * * * * * * * *
HGO      IADGTMAFMFESSLSLAVTKWGLKASRCLDENY-HKCWEPLKSHFTPNR
MHGO     IADGTMAFMFESSLSLAVTKWGLKTCSCLDENY-YKCWEPLRSHFTPNR
HMGA     IGDGSMFMFESSLMVGVSEWGLKTCQKQVEYNEHSWQPLKRHFK----
          * * * * * * * * * * * * * * * * * * * * * * * * * * *
HGO      NPAEPN
MHGO     SPTEPK
HMGA     DPRKAQ
          *
    
```

Figure 3 Comparison of primary structure of homogentisate-1,2-dioxygenase protein from man (HGO, AF000573¹⁵), mouse (MHGO, U58988¹⁶), and *Aspergillus nidulans* (HMGA, U30797¹⁷) using ClustalX 1.3b. Positions conserved in all three organisms are indicated by (*). Arrows mark sites of identified missense mutations, novel mutations are shown in bold.

because the founder effect had been considered to be the main reason responsible for an increased incidence of AKU in Slovakia. The most frequent mutations, G161R and G152fs (previously identified in two Slovak families by Gehrig *et al*⁶), were present on 50% of 32 screened AKU chromosomes (table 1). So far, these mutations have not been identified in any other screened population. This indicates that they might be specific for Slovakia. The high proportion of these two mutations can be explained by founder effect and subsequent genetic isolation. In addition,

however, there must have been at least four other founders contributing to the gene pool of the Slovak AKU population (table 1). Three further mutations were each found on only one AKU chromosome, thus indicating that this mechanism is not the only one responsible for the high incidence of this disease in Slovakia (1:19 000).

Possible common origins of chromosomes carrying the same AKU mutations can be further traced by the analysis of DNA polymorphisms in the HGO gene and construction of haplotypes. This work is now in progress.

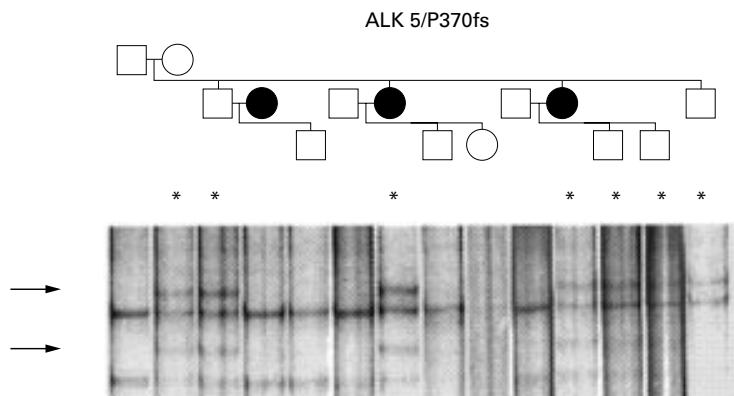


Figure 4 Non-radioactive SSCP analysis of exon 13 indicating segregation of mutation P370fs in family ALK5. Arrows mark the SSCP shifts corresponding to this mutation. The presence of the mutation in heterozygous state is indicated by (*). Patients were also heterozygous for mutation G270R (exon 11) (table 2).

Links in electronic databases involve: primary structure of HGO from man (HGO, AF00573,¹³), mouse (MHGO, U58988,¹⁴), and *Aspergillus nidulans* (HMGA, U30797¹⁵), and human HGO transcript (AF045167¹⁵).

A ZATKOVÁ*
H POLÁKOVÁ*
L MICUTKOVÁ†
M ZVARIK‡
V BOŠÁK‡
E FERÁKOVÁ†
J MATUŠEK§
V FERÁK†
L KÁDASI*

*Institute of Molecular Physiology and Genetics, Slovak Academy of Sciences, Vlárská 5, SK 833 34 Bratislava, Slovakia

†Department of Molecular Biology, Faculty of Natural Sciences, Comenius University Bratislava, Mlynská dolina, B2, 842 15 Bratislava, Slovakia

‡Research Institute of Rheumatic Disease, Nábresie I Krasku 4, 921 01 Piešťany, Slovakia

§Institute of Criminalistics, Sklabinská 1, 812 72 Bratislava, Slovakia

Correspondence to: Dr Zatková, zatkova@fns.uniba.sk

- 1 Janocha S, Wolz W, Srsen S, Srsnova K, Montagutelli X, Guenet J-L, Grimm T, Kress W, Muller CR. The human gene for alkaptonuria (AKU) maps to chromosome 3q. *Genomics* 1994;19:5-8.
- 2 La Du BN, Zannoni VG, Laster L, Seegmiller JE. The nature of the defect in tyrosine metabolism in alkaptonuria. *J Biol Chem* 1958;230:251-60.
- 3 Garrod AE. The incidence of alkaptonuria: a study in chemical individuality. *Lancet* 1902;2:1616-20.
- 4 Pollak MR, Chou YH W, Cerda JJ, Steinmann B, La Du BN, Seidman JG, Seidman CE. Homozygosity mapping of the gene for alkaptonuria to chromosome 3q2. *Nat Genet* 1993;5:201-4.
- 5 Fernandez-Canon JM, Granadino B, Beltran-Valero de Bernabe D, Renedo M, Fernandez-Ruiz E, Penalva MA, Rodriguez de Cordoba S. The molecular basis of alkaptonuria. *Nat Genet* 1996;14:19-24.

- 6 Gehrig A, Schmidt SR, Muller CR, Srsen S, Srsnova K, Kress W. Molecular defects in alkaptonuria. *Cytogenet Cell Genet* 1997;76:14-16.
- 7 Beltran-Valero de Bernabe D, Granadino B, Chiarelli I, Porfirio B, Mayatepek E, Aquaron R, Moore MM, Festen JJ, Sanmarti R, Penalva MA, Rodriguez de Cordoba SR. Mutation and polymorphism analysis of the human homogentisate 1,2-dioxygenase gene in alkaptonuria patients. *Am J Hum Genet* 1998;62:776-84.
- 8 Higashino K, Liu W, Ohkawa T, Yamamoto T, Fukui K, Ohno M, Imanishi H, Iwasaki A, Amuro Y, Hada T. A novel point mutation associated with alkaptonuria. *Clin Genet* 1998;53:228-9.
- 9 Beltran-Valero de Bernabe D, Jimenez FJ, Aquaron R, Rodriguez de Cordoba SR. Analysis of alkaptonuria (AKU) mutations and polymorphisms reveals that the CCC sequence motif is a mutational hot spot in the homogentisate 1,2-dioxygenase gene (HGO). *Am J Hum Genet* 1999;64:1316-22.
- 10 Felber U, Mutsch Y, Grehn F, Muller CR, Kress W. Ocular ochronosis in alkaptonuria patients carrying mutations in the homogentisate 1,2-dioxygenase gene. *Br J Ophthalmol* 1999;83:680-3.
- 11 Milch RA. Studies of alkaptonuria: inheritance of 47 cases in eight highly inter-related Dominican kindreds. *Am J Hum Genet* 1960;12:76-85.
- 12 Srsen S, Cisarik F, Pasztor L, Harmecko L. Alkaptonuria in the Trencin district of Czechoslovakia. *Am J Med Genet* 1978;2:159-66.
- 13 Orita M, Iwahana H, Kanazawa H, Hayashi K, Sekiya T. Detection of polymorphisms of human DNA by gel electrophoresis as single-strand conformation polymorphisms. *Proc Natl Acad Sci USA* 1989;86:2766-70.
- 14 Budowle B, Chakraborty R, Giusti AM, Eisenberg AJ, Allen RC. Analysis of the VNTR locus D1580 by the PCR followed by high resolution PAGE. *Am J Hum Genet* 1991;48:137-44.
- 15 Granadino B, Beltran-Valero de Bernabe D, Fernandez-Canon JM, Penalva MA, Rodriguez de Cordoba S. The human homogentisate 1,2-dioxygenase (HGO) gene. *Genomics* 1997;43:115-22.
- 16 Schmidt SR, Gehrig A, Koehler MR, Schmid M, Muller CR, Kress W. Cloning of the homogentisate 1,2-dioxygenase gene, the key enzyme of alkaptonuria in mouse. *Mamm Genome* 1997;8:168-71.
- 17 Fernandez-Canon JM, Penalva MA. Molecular characterisation of a gene encoding homogentisate dioxygenase from *Aspergillus nidulans* and identification of its human and plant homologues. *J Biol Chem* 1995;270:21199-205.

J Med Genet 2000;37:542-543

Clinical and molecular correlates of somatic mosaicism in neurofibromatosis 2

EDITOR—Neurofibromatosis 2 (NF2) is an autosomal dominant disorder that is characterised by benign nervous system tumours (such as vestibular schwannomas (VSs), intracranial meningiomas, and spinal tumours) and other abnormalities.¹ Somatic mosaicism (the presence of a mutation, deletion, or chromosomal abnormality in a subpopulation of somatic cells) is thought to be relatively common in NF2, affecting perhaps 15% of sporadic cases.^{2,3}

There can be considerable clinical variability in mosaics because somatic mutation can occur at different stages of the postzygotic cell lineage. Evans *et al*² reported the degree of mosaicism for five NF2 patients. Two patients with an estimated <10% of peripheral lymphocytes with NF2 mutations had ages of onset of symptoms of 41-48 years, while three patients with an estimated 21-44% of affected cells had ages of onset of symptoms of 21-28 years. This is consistent with a relationship between degree of mosaicism and disease severity, although there are too few patients to draw firm conclusions.

Few NF2 somatic mosaics have been reported, and clinical and molecular differences between mosaics and sporadic non-mosaic NF2 patients have not been quantified. To examine this question, we compared somatic mosaic and sporadic non-mosaic NF2 patients selected from NF2 populations in the United Kingdom (341 patients)^{4,5} and Germany (118 patients).^{6,7} The study groups included 13 previously identified somatic mosaics^{2,3} and 86 sporadic non-mosaic NF2 patients, all of whom had head and spine gadolinium enhanced magnetic resonance imaging. Sporadic NF2 patients were defined as non-mosaic if they had identified germline NF2 mutations with

normal strength gel bands. In theory, somatic mosaic patients could have near normal band strength, but in practice band strength will be reduced when <50% of peripheral lymphocytes have NF2 mutations.² Clinical data were not available in sufficient detail to determine if the distribution of lesions was non-uniform, which could result from somatic mosaicism.

The covariates that were examined were age at onset of symptoms, age at diagnosis, number of VSs (none or unilateral versus bilateral), presence and number of intracranial meningiomas, presence of spinal tumours, and germline NF2 mutation type (frameshift or nonsense versus other identified mutations). In univariate analyses, the two tailed *t* test was used for continuous variables and the two tailed Fisher exact test for binary variables. Multiple logistic regression was then used to examine the association between somatic mosaic status and covariates that differed between groups; interaction terms of age with number of tumours were also considered.

The characteristics of somatic mosaics and sporadic non-mosaics are compared in table 1. Age at onset of

Table 1 Characteristics of somatic mosaic and sporadic non-mosaic NF2 patients

Characteristic	Somatic mosaic	Sporadic non-mosaic	<i>p</i>
No of patients	13	86	
Age at onset of symptoms, years, mean (SE)	26.5 (2.4)	18.7 (1.1)	0.012
Age at diagnosis, years, mean (SE)	33.6 (2.7)	24.7 (1.3)	0.013
Germline mutation type (%)			0.055
Frameshift or nonsense	92.3	62.8	
Other	7.7	37.2	
Vestibular schwannomas (%)			0.391
None or unilateral	30.0	12.9	
Bilateral	70.0	87.1	
Spinal tumours (%)			0.733
Absent	30.8	24.4	
Present	69.2	75.6	
Intracranial meningiomas (%)			0.773
Absent	46.2	41.9	
Present	53.8	58.1	
Intracranial meningiomas, number, mean (SE)	1.5 (1.0)	1.5 (0.2)	0.993

symptoms, age at diagnosis, and the distribution of germline *NF2* mutation types were significantly different between the two groups. On average, somatic mosaics were 7.8 years younger than non-mosaics at onset of symptoms ($p=0.012$) and 8.9 years younger at diagnosis ($p=0.013$). Nonsense or frameshift mutations were identified in 92.3% of somatic mosaics, compared to 62.8% of non-mosaics ($p=0.055$). The prevalence of no VSs or unilateral VSs was higher in mosaics than in non-mosaics (30.0% versus 12.9%), but this difference was not statistically significant. The prevalence and number of other central nervous system tumours were similar in the two groups.

Since age at onset of symptoms and age at diagnosis were highly correlated ($r^2=0.65$, $p<0.001$), age at diagnosis was used in the multiple logistic regression model because tumour burden was evaluated at diagnosis. In the multiple logistic regression model, age at diagnosis and germline *NF2* mutation type were significantly associated with somatic mosaic status and number of VSs was of marginal statistical significance. Interaction terms were not statistically significant. Patients with frameshift or nonsense mutations had 23.1-fold greater odds of somatic mosaicism than patients with other types of identified mutations (95% confidence interval 1.7–316.4, $p=0.019$). This may be a bias that results from milder disease in somatic mosaic patients and more severe disease in *NF2* patients with nonsense or frameshift mutations, so that somatic mosaic *NF2* patients with nonsense or frameshift mutations are more likely to be clinically detected as having *NF2*.^{2,3}

The odds of somatic mosaicism increased 11.1-fold per decade increase in age at diagnosis (95% confidence interval 10.3–11.8, $p=0.004$). Patients with no VSs or unilateral VSs were 7.1-fold more likely to be mosaic (95% confidence interval 1.0–53.7, $p=0.056$). Considering two sporadic *NF2* patients (one 40 years old at diagnosis with a unilateral VS and another 20 years old at diagnosis with bilateral VSs, both with non-truncating mutations), the former patient has 157.6-fold greater odds of being a somatic mosaic than the latter patient.

This study is based on relatively few mosaic patients, but if substantiated by other studies, these findings may be a useful adjunct in identifying somatic mosaics. For example,

sporadic *NF2* patients who are >40 years old at diagnosis with no VSs or unilateral VSs could be evaluated for somatic mosaicism. This is an unusual clinical presentation in *NF2*, occurring less frequently than the estimated 15% prevalence of somatic mosaicism in sporadic *NF2* cases. In the United Kingdom *NF2* patient series, nine of 206 sporadic patients (4.4%) meet this description. These patients include only one previously identified somatic mosaic; the rest have unidentified germline *NF2* mutations. The eight patients with unidentified mutations have ages at onset of symptoms ranging from 29–45 years (median 36 years) and ages at diagnosis ranging from 42–59 years (median 48 years). We are currently analysing tumours from these patients to determine the proportion that are mosaic.

We thank the *NF2* patients and their families for participating and Drs L Kluwe, V F Mautner, and J M Friedman for helpful comments.

M E BASER*
A J WALLACE†
T STRACHAN‡
D G R EVANS‡

*11746 Bellagio Road, No 308, Los Angeles, CA 90049, USA

†Department of Medical Genetics, St Mary's Hospital, Manchester, UK

‡University Department of Human Genetics, University of Newcastle upon Tyne, UK

Correspondence to: Dr Baser, baser@earthlink.net

- 1 Gutmann DH, Aylsworth A, Carey JC, *et al*. The diagnostic evaluation and multidisciplinary management of neurofibromatosis 1 and neurofibromatosis 2. *JAMA* 1997;278:51–7.
- 2 Evans DGR, Wallace AJ, Wu CL, Trueman L, Ramsden RT, Strachan T. Somatic mosaicism: a common cause of classic disease in tumor-prone syndromes? Lessons from type 2 neurofibromatosis. *Am J Hum Genet* 1998;63:727–36.
- 3 Kluwe L, Mautner VF. Mosaicism in sporadic neurofibromatosis 2 patients. *Hum Mol Genet* 1998;7:2051–5.
- 4 Evans DGR, Huson SM, Donnai D, *et al*. A clinical study of type 2 neurofibromatosis. *Q J Med* 1992;84:603–18.
- 5 Evans DGR, Trueman L, Wallace A, Collins S, Strachan T. Genotype/phenotype correlations in type 2 neurofibromatosis (*NF2*): evidence for more severe disease associated with truncating mutations. *J Med Genet* 1998;35:450–5.
- 6 Mautner VF, Lindenau M, Baser ME, *et al*. The neuroimaging and clinical spectrum of neurofibromatosis 2. *Neurosurgery* 1996;38:880–6.
- 7 Kluwe L, Bayer S, Baser ME, *et al*. Identification of *NF2* germ-line mutations and comparison with neurofibromatosis 2 phenotypes. *Hum Genet* 1996;98:534–8.

J Med Genet 2000;37:543–547

Many $\Delta F508$ heterozygote neonates with transient hypertrypsinaemia have a second, mild *CFTR* mutation

EDITOR—Mutations of the cystic fibrosis transmembrane conductance regulator (*CFTR*) gene have an extremely wide phenotypic spectrum.¹ The “classical” severe form of cystic fibrosis (CF) is characterised by pancreatic insufficiency and chronic endobronchial infection.² Milder forms may show pancreatic sufficiency, though the degree of pulmonary involvement varies.^{3,4} Several other pathologies have now been linked with mutations in the *CFTR* gene, including congenital bilateral absence of the vas deferens, liver disease, pancreatitis, and disseminated bronchiectasis.^{5–7}

There are now over 850 documented mutations in the *CFTR* gene.⁸ The most common is $\Delta F508$, which appears on 66% of CF chromosomes in western Europe.⁹ The pancreatic status of patients has a strong correlation to the genotype, whereas the severity of lung disease shows little or no relation to genotype.^{10–12} Generally, mutations that

result in no *CFTR* protein, such as truncating mutations, or those, such as $\Delta F508$, which result in mislocalisation of the protein, result in a severe phenotype with pancreatic insufficiency. Missense mutations, particularly in the transmembrane domains, result in a milder, more variable disease.^{13,14} The sweat test, long regarded as the gold standard diagnostic test for cystic fibrosis, may give normal results in these milder forms.

Neonatal screening for CF relies on an increased immunoreactive trypsinogen (IRT) concentration in blood of affected babies during the first two months of life.¹⁵ However, this method has low specificity, particularly with samples taken in the first week of life, so mutation analysis is increasingly being used as a second tier. In the Trent region of the United Kingdom (UK), where $\Delta F508$ accounts for over 80% of CF mutations, we currently use a three stage IRT-DNA-IRT protocol, which has a low requirement for second blood samples and for sweat testing.¹⁵ Any initial blood sample with IRT readings above the threshold is analysed for the $\Delta F508$ *CFTR* mutation. Subjects who are heterozygous for $\Delta F508$ are resampled at 27 days; if the IRT level is again above the threshold the child is referred for sweat testing. The families of heterozygous neonates

Table 1 CFTR primers, PCR and SSCP analysis conditions

Region amplified	Primer sequence	Anneal temp (°C)	Product size (bp)	Enzyme digest	SSCP conditions % glycerol
Exon 1	F 5' - GCC AAA TGA CAT CAC AGC AGG - 3' R 5' - TGT CTT TCC GAA GCT CGG TTG - 3'	61	211	None	3
Exon 2	2i-5 F 5' - CCA AAT CTG TAT GGA GAC CA - 3' R 5' - TCT CTC TTC AAC TAA ACA ATG TAC - 3'	56	203	None	3
Exon 3	3i-5 F 5' - CTT GGG TTA ATC TCC TTG GA - 3' R 5' - ATT CAC CAG ATT TCG TAG TC - 3'	55	309	<i>MboI</i>	2
Exon 4	4i-5 F 5' - TCA CAT ATG GTA TGA CCC TC - 3' R 5' - TTG TAC CAG CTC ACT ACC TA - 3'	56	438	<i>BstI</i>	2
Exon 5	F 5' - GAG AAG ATA GTA AGC TAG ATG AAT - 3' R 5' - CAT ATC TCA TCA AAT TTG TTC AGG - 3'	56	212	None	3
Exon 6a	F 5' - GGA AGA TAC AAT GAC ACC TGT TTT - 3' R 5' - TAC TAA AGT GGG CTT TTT GAA AAC - 3'	58	275	None	2
Exon 6b	F 5' - CCT TGA GCA GTT CTT AAT AGA TAA - 3' R 5' - GGA AGT CTA CCA TGA TAA ACA TAT - 3'	56	285	None	2
Exon 7	F 5' - CAG AAC TGA AAC TGA CTC GG - 3' R 5' - TGC TCC AAG AGA GTC ATA CC - 3'	58	230	None	2
Exon 8	F 5' - GCA CAA TGA GAG TAT AAA GTA GAT - 3' R 5' - AAA CAG TTA GGT GTT TAG AGC AAA - 3'	56	223	None	3
Exon 9 (1)	F 5' - TAA TGG ATC ATG GGC CAT GT - 3' R 5' - ACA GTG TTG AAT GTG GTG CA - 3'	55	560	N/A	N/A
Exon 9 (2)	F 5' - GGG GAA TTA TTT GAG AAA GC - 3' R 5' - TTC CAG CAC TAC AAA CTA GAA - 3'	55	258	None	3
Exon 10	10i-5 F 5' - GCA GAG TAC CTG AAA CAG GA - 3' 10i-3 R 5' - CAT TCA CAG TAG CTT ACC CA - 3'	58	491	<i>NsiI/HinfI</i>	2
Exon 11	11i-5 F 5' - CAA CTG TGG TTA AAG CAA TAG TGT - 3' 11i-3 R 5' - GCA CAG ATT CTG AGT AAC CAT AAT - 3'	58	425	<i>HincII</i>	See text 10
Exon 12	12i-5 F 5' - GTG AAT CGA TGT GGT GAC CA - 3' 12i-3 R 5' - CTG GTT TAG CAT GAG GCG GT - 3'	60	426	<i>BstNI</i>	2
Exon 13.1	F 5' - GAC ATA TTG CAA TAA AGT ATT TAT - 3' R 5' - AGT TAG GAT TGA ATT TCT TCT TT - 3'	53	280	None	2
Exon 13.2	F 5' - TTT AGC TCA AAA CTC ATG GGA - 3' R 5' - AGA ATC TGG TAC TAA GGA CAG - 3'	56	309	None	2
Exon 13.3	F 5' - AAT CCA ATC AAC TCT ATA CGA A - 3' R 5' - GAT TCT ACT CAA TTG CAT TCT GT - 3'	55	444	<i>HincII</i>	2
Exon 13.4	F 5' - CCT GAA CCT GAT GAC ACA C - 3' R 5' - GAT TCT ACT CAA TTG CAT TCT GT - 3'	58	239	None	2
Exon 14a	F 5' - GGT GGC ATG AAA CTG TAC TGT CTT - 3' R 5' - GTA TAC ATC CCC AAA CTA TCT TAA TTT AAC - 3'	60	250	None	2
Exon 14b	14Ai-3 F 5' - TGG GAG GAA TAG GTG AAG ATG TTA - 3' R 5' - GCT TGG GAG AAA TGA AAC AAA GTG - 3'	60	208	None	2
Exon 15	F 5' - ATT CAG TAA GTA ACT TTG GCT GCC - 3' R 5' - AAG GCA CAT GCC TCT GTG CA - 3'	60	413	<i>HinfI</i>	4
Exon 16	F 5' - GCG TCT ACT GTG ATC CAA ACT TAG - 3' R 5' - TAG ACA GGA CTT CAA CCC TCA ATC - 3'	62	289	<i>RsaI</i>	3
Exon 17a	F 5' - TGA AAA TGT TTA CTC ACC AAC ATG - 3' R 5' - AGA ATC TCA AAT AGC TCT TAT AGC - 3'	56	254	None	2
Exon 17b	17Bi-5 F 5' - TTC AAA GAA TGG CAC CAG TGT - 3' 17Bi-3 R 5' - ATA ACC TAT AGA ATG CAG CA - 3'	57	463	<i>HincII</i>	2
Exon 18	F 5' - ACA TGA GGT TCA TTT ACG TCT TTT - 3' R 5' - TAC TCA TAC TTT GTT ACT TGT CTG - 3'	56	201	None	3
Exon 19	19i-5 F 5' - GCC CGA CAA ATA ACC AAG TGA - 3' 19i-3 R 5' - GCT AAC ACATTG CTT CAG GCT - 3'	58	454	<i>HincII</i>	2
Intron 19	F 5' AGG CTT CTC AGT GAT CTG TTG - 3' R 5' - GAA TCA TTC AGT GGG TAT AAG CAG - 3'	60	477	<i>HphI</i>	See text 0
Exon 20	F 5' - GGT CAG GAT TGA AAG TGT GCA - 3' R 5' - CTA TGA GAA AAC TGC ACT GGA - 3'	56	473	<i>HinfI</i>	2
Exon 21	21i-5 F 5' - AAT GTT CAC AAG GGA CTC CA - 3' 21i-3 R 5' - CAA AAG TAC CTG TTG CTC CA - 3'	62	477	<i>DraI</i>	2
Exon 22	F 5' - GCT TGA GTG TTT TTA ACT CTG TGG - 3' R 5' - GTT CCC ACT GTG CTA TTA AGT AAC - 3'	61	266	None	2
Exon 23	F 5' - AGC TGA TTG TGC GTA ACG CT - 3' R 5' - TAA AGC TGG ATG GCT GTA TG - 3'	58	400	<i>MboI</i>	2
Exon 24	F 5' - AGA TCT CAC TAA CAG CCA TTT CCC - 3' R 5' - CAT GAG CAA ATG TCC CAT GTC AAC - 3'	62	263	None	3

with a second IRT level below the threshold are referred for genetic counselling on the assumption that such neonates are unaffected carriers.

It has previously been shown that neonates with transient hypertrypsinemia carry the $\Delta F508$ mutation at a higher frequency than the general population.¹⁶ Additionally, IRT remains on average higher in the repeat blood sample in babies who are heterozygous for $\Delta F508$ than in non- $\Delta F508$ babies.¹⁵ Thus, it is possible that a proportion of infants with transient hypertrypsinemia and $\Delta F508$ may have a second (mild) CF mutation. We have examined this hypothesis in a cohort of infants assessed through the Trent (UK) neonatal screening programme.

A cohort of 88 $\Delta F508$ heterozygous neonates with transient hypertrypsinemia born between April 1991 and

November 1996 were available for testing.¹⁵ All had exceeded the IRT cut off value for the 6th day blood sample (usually 90 ng/ml but adjusted periodically to select approximately 0.5% of tested babies) and had an IRT concentration below 80 ng/ml in the 27th day sample. Cases with meconium ileus were excluded. There was a sample available from every subject fulfilling the selection criteria for the trial period. All samples were irreversibly anonymised but the IRT data were retained and the subjects in the cohort were known. In addition, three transiently hypertrypsinemic babies who would otherwise have qualified for the cohort had already been identified as compound heterozygotes for $\Delta F508/R117H$ CF mutations through extended mutation analysis of their parents.

DNA for PCR was obtained from the blood spot by elution in 100 μ l of 50 mmol/l NaOH for 30 minutes at room

Table 2 Compound heterozygotes detected

Domain and mutation type	Genotype	Exon	1st IRT	2nd IRT
Transmembrane, missense	ΔF508/P67L	3	129	34*
	ΔF508/R117H	4	110	21*
	ΔF508/R117H	4	84	34
	ΔF508/R117H	4	95	39
	ΔF508/R117H	4	104	40
	ΔF508/R117H	4	146	41
	ΔF508/R117H	4	104	48*
	ΔF508/R117H	4	120	53
	ΔF508/R117H	4	111	54
	ΔF508/R117H	4	175	72*
	ΔF508/R117L	4	129	70
	ΔF508/L967S	15	122	15
	ΔF508/F1052V	17b	189	29
	ΔF508/R1066H	17b	94	18
	Transmembrane, nonsense	ΔF508/R75X	3	86
ΔF508/R75X		3	171	27
ΔF508/R851X		14a	112	76
Regulatory, missense	ΔF508/F693L	13	109	29
Alternate splice site	ΔF508/3849+10KB C→T	i19	99	26*
	ΔF508/3849+10KB C→T	i19	112	36*

None of these samples had the IVS8-5T variant sequence.

*These patients have presented with symptoms of lung involvement.

temperature. The samples were then boiled for five minutes, cooled, and neutralised with 15 µl of 1 mol/l Tris-HCl (pH 8.0).

Primers used for amplification comprised both published¹⁸ (nomenclature as reference) and unpublished sets. PCR was performed in 25 µl reactions under standard conditions. The IVS8-nT tract was amplified and identified as described elsewhere.¹⁹ Exon 9 was amplified using the IVS8-nT protocol and the primer sets 9 (1) followed by 9 (2). This excluded the two highly polymorphic regions before the exon (TG(n) + IVS8-nT) from amplification and greatly simplified mutation analysis. Full details of primer sequences and annealing temperatures can be found in table 1.

Amplified fragments were screened for sequence alterations by single stranded conformational polymorphism analysis (SSCP)/heteroduplex analysis (HA) using standard conditions and procedures as in table 1 with 14% v/v (59:1 acrylamide:bisacrylamide) polyacrylamide gels and electrophoresis at 12°C in 0.5 × TBE except exon 11, which used a 14% (37:1 acryl:bis) polyacrylamide gel. Intron 19 used non-denaturing electrophoresis on 8% (29:1 acryl:bis) polyacrylamide gels in 1 × TBE. Any samples displaying shifts (indicative of a sequence alteration) were investigated further by direct DNA sequencing (as per manufacturer's instructions). This methodology identifies >95% of all mutations in our laboratory.

Second mutations were identified in 20 subjects (table 2) giving a compound heterozygote frequency of 22%. R117H was the most common second mutation found,

constituting 45% of the compound heterozygotes identified. Fig 1 shows the range of second IRT reading displayed by non-ΔF508 babies, the putative ΔF508 heterozygotes, and the compound heterozygotes. The IRT distributions of the putative ΔF508 heterozygotes (19) and particularly the compound heterozygotes are shifted to the right. Forty one percent of ΔF508 heterozygote neonates with >25 ng IRT/ml in the 27th day blood sample possessed a second mutation compared to ~6% for those with <25 ng/ml, an enrichment factor of 2.35.

Recent work has suggested that "polyvariant mutant CFTR genes" may, when combined, result in less functional or pathologically insufficient CFTR.²¹ In the light of this, we determined the incidence of the intronic poly-T tract, IVS8-nT, which interacts with the R117H mutation. The IVS8-5T allele was present in three of the 91 neonates, none of whom were identified as being compound heterozygotes for a second CF mutation. The 71 remaining subjects are likely to be true heterozygotes with transient hypertrypsinemia arising from causes other than CF.

In this study, we have confirmed that the combination of heterozygosity for ΔF508 and persisting mild hypertrypsinemia in the newborn period carries a substantial risk of that infant having a second CF mutation. In addition, the concentration of IRT in whole blood at 27 days is a biochemical marker to refine this risk further.

All the mutations found in our cohort have been reported previously and for the more common ones there are data on phenotypic presentation. In general, the severity of lung disease is less predictable than the degree of pancreatic involvement.²²

The R117H has been associated with a range of phenotypes and the intronic variant polyT tract (IVS8-nT) is known to affect expression. The IVS8-5T variant is an inefficient splice acceptor site and with R117H, in trans with ΔF508, results in a pancreatic sufficient phenotype. The 7T variant and R117H combination in ΔF508 heterozygotes is associated with congenital bilateral absence of the vas deferens and, in some cases, mild lung disease.^{19, 23} Some females with this genotype are completely asymptomatic. Three ΔF508:R117H compound heterozygotes with the 7T variant from the cohort have already presented with symptoms of lung disease. An increased frequency of IVS8-5T in non-CF transient neonatal hypertrypsinemia, with or without heterozygosity for ΔF508, has been reported in two studies.^{23, 24} However, in our cohort, IVS8-5T was not present in any of the compound heterozygotes detected and its overall frequency was not significantly different from that reported in the general population.

Five other neonates screened had missense mutations in transmembrane domains. These have been reported in patients with presenting phenotypes ranging from "cystic fibrosis" to oligospermia, but there have been too few cases

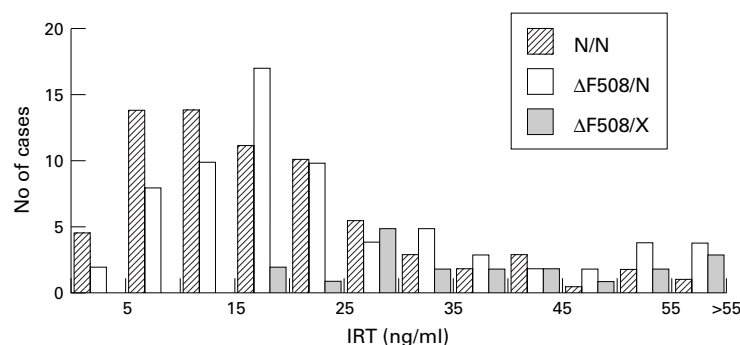


Figure 1 Distribution of immunoreactive trypsin concentrations in 27th day blood spots. The data from the non-ΔF508 sample have been normalised to the number of ΔF508/N samples.

described to define genotype-phenotype correlations. The missense mutation F693L is located in the regulatory domain of *CFTR* and was first identified in a young girl with $\Delta F508$ on her other allele who was diagnosed with pancreatic insufficient cystic fibrosis.²⁶

Three subjects had nonsense mutations which are normally associated with severe disease as they introduce a stop codon, leading to truncated, usually inactive, *CFTR* protein being transcribed.

The 3849+10 kb C→T mutation, identified in two subjects in our cohort, activates a partially active, cryptic splice site within the intron that causes an 84 bp "exon" to be inserted, in frame, within exon 19.²⁷ Homozygotes for this mutation usually have relatively mild lung disease, while compound heterozygotes may show pancreatic insufficiency and may have more severe lung disease.

Compared to other neonatal metabolic screening tests, that for CF has a relatively low sensitivity; the more successful programmes detect approximately 90% of severe, "classical" CF.²⁸ With the increasing recognition of milder forms of *CFTR* deficiency, and the tendency to use DNA analysis rather than the sweat test as the ultimate diagnostic arbiter, the perceived effectiveness of neonatal screening is being further eroded. Nevertheless, provided that the prime aim of the programme remains the detection of classical cystic fibrosis, in the way the term was understood 10 years ago, performance using either a two stage IRT method or one of the newer IRT-DNA protocols may be regarded as acceptable.

The difficulties with DNA based protocols arise from the need to provide explicit counselling to families where the baby has been found to be heterozygous for $\Delta F508$ but has given a normal sweat test or had a normal IRT concentration in a second blood sample. In most screening programmes more babies will fall into this group than will be diagnosed with classical cystic fibrosis (representative figures are given in reference 15). The present study shows that such babies, particularly the subgroup with IRT in the second blood sample >25 ng/ml, have a high likelihood of a second *CFTR* mutation. Should further testing of $\Delta F508$ heterozygotes be restricted to mutations associated with a severe phenotype or should extended mutation analysis, at least in the higher risk group with second IRT >25 ng/ml, become part of routine investigation? Would such investigation improve the accuracy of counselling of such families?

The majority of compound heterozygotes detected in this study have mutations usually associated with milder forms of *CFTR* disease. However, some of our hypertrypsinaemic cohort have genotypes previously reported in severe forms of CF and may be regarded as having given false negative screening test results. Genotype-phenotype correlation is complicated by the existence of polyvariant *CFTR* genes and modifier polymorphisms,²⁹ as well as possible modifiers at other loci. It is probably unsound to extrapolate data from clinically selected cases to a cohort which was selected on an entirely different basis. The clinical significance of compound heterozygosity detected through neonatal screening will only become apparent through systematic follow up. Preliminary indications are that some of the expectedly mild cases develop significant early symptoms; six of the compound heterozygotes in our cohort (indicated in table 2) were unblinded by being diagnosed with cystic fibrosis, enabling them to be traced forwards from their neonatal screening results. All have developed symptomatic respiratory infections associated with positive bacterial cultures. A prospective study is under way to

determine the clinical spectrum present in such compound heterozygotes.

It is generally agreed that diagnosing adult onset disease during childhood is undesirable if there is no effective preventative treatment. One would not normally wish to predict fertility problems in an otherwise healthy male neonate. However, in so far as early active treatment can reduce the impact of lung disease in moderate *CFTR* deficiency, previous warning that a child is thus predisposed would be valuable. Thus, the increased possibility of mild *CF* spectrum disease should be raised during counselling for $\Delta F508$ heterozygosity detected on newborn screening. There may be a case for more active clinical follow up, particularly in the persistent mild hypertrypsinaemia group. However, until we are more confident in predicting outcome from genotype, the prospective identification of "milder" mutations should not be included in routine neonatal screening protocols.

The support of the Sheffield Children's Hospital Research and Development Fund and the Cystic Fibrosis Trust(UK) is gratefully acknowledged.

JIM BOYNE*
STEVE EVANS*
RODNEY J POLLITT†
CHRISTOPHER J TAYLOR‡
ANN DALTON*

*North Trent Molecular Genetics Service, Centre for Human Genetics,
117 Manchester Road, Sheffield S10 5DN, UK

†Neonatal Screening Laboratory, Sheffield Children's Hospital, Western Bank, Sheffield S10 2TH, UK

‡University Department of Paediatrics, Sheffield Children's Hospital, Western Bank, Sheffield S10 2TH, UK

- Dean M, Santis G. Heterogeneity in the severity of cystic fibrosis and the role of *CFTR* gene mutations. *Hum Genet* 1994;93:364-8.
- Welsh MJ, Tsui LC, Boat TF, Beaudet AL. Cystic fibrosis. In: Scriver CL, Beaudet AL, Sly WS, Valle D, eds. *The metabolic and molecular basis of inherited disease*. 7th ed. New York: McGraw-Hill, 1995:3799-876.
- Corey M, Gaskin K, Durie PC, et al. Improved prognosis in CF patients with normal fat absorption. *J Pediatr Gastroenterol Nutr* 1984;3(suppl 1):S99-105.
- Gaskin K, Gurwitz D, Durie PC, et al. Improved respiratory prognosis in patients with cystic fibrosis with normal fat absorption. *J Pediatr* 1982;100:857-62.
- Dumur V, Gervais R, Rigot JM, et al. Congenital bilateral absence of the vas deferens (CBAVD) and cystic fibrosis transmembrane regulator (*CFTR*): correlation between genotype and phenotype. *Hum Genet* 1996;97:7-10.
- Braekeleer MD, Férec C. Mutations in the cystic fibrosis gene in men with congenital bilateral absence of the vas deferens. *Mol Hum Reprod* 1996;9:669-77.
- Pignatti PF, Bombieri C, Marigo C, et al. Increased incidence of cystic fibrosis gene mutations in adults with disseminated bronchiectasis. *Hum Mol Genet* 1995;4:635-9.
- <http://www.genet.sickkids.on.ca/cftr/>
- Cystic Fibrosis Genetic Analysis Consortium (CFGAC). Worldwide survey of the $\Delta F508$ mutation - report from the cystic fibrosis analysis consortium. *Am J Hum Genet* 1990;47:345-59.
- Kristidis P, Bozon D, Corey M, et al. Genetic determination of exocrine pancreatic function in cystic fibrosis. *Am J Hum Genet* 1992;50:1178-84.
- Santis G, Osborne L, Knight R, et al. Genetic influences on pulmonary severity in cystic fibrosis. *Lancet* 1990;335:294.
- Corey M, Durie P, Moore D, et al. Familial concordance of pancreatic function in cystic fibrosis. *J Pediatr* 1989;115:274-7.
- Kerem E, Corey M, Kerem BS, et al. The relation between genotype and phenotype in cystic fibrosis: analysis of the most common mutation ($\Delta F508$). *N Engl J Med* 1990;323:1517-22.
- Dean M, White MD, Amos J, et al. Multiple mutations in highly conserved residues are found in mildly affected cystic fibrosis patients. *Cell* 1990;61:863-70.
- Heeley AF, Bangert SK. The neonatal detection of cystic fibrosis by measurement of immunoreactive trypsin in blood. *Ann Clin Biochem* 1992;29:361-76.
- Pollitt RJ, Dalton A, Evans S, et al. Neonatal screening for cystic fibrosis in the Trent region (UK): two-stage immunoreactive trypsin screening compared with a three-stage protocol with DNA analysis as an intermediate step. *J Med Screening* 1997;4:23-8.
- Laroche G, Travert G. Abnormal frequency of $\Delta F508$ mutation in neonatal transient hypertrypsinaemia. *Lancet* 1991;337:55.
- Zielenski J, Rozmahel R, Bozon D, et al. Genomic DNA sequence of the cystic fibrosis transmembrane conductance regulator (*CFTR*) gene. *Genomics* 1991;10:214-28.
- Chillon M, Casals T, Mercier B. Mutations in patients with congenital absence of the vas deferens. *N Engl J Med* 1995;332:1475-80.
- Nørgaard-Pedersen B, Høgdall E, Iltis A, et al. Immunoreactive trypsin and a comparison of two $\Delta F508$ mutation analyses in newborn screening for cystic fibrosis: an anonymous pilot study in Denmark. *Screening* 1993;2:1-11.
- Cuppens H, Teng H, Raeymaekers P, et al. *CFTR* haplotype backgrounds on normal and mutant *CFTR* genes. *Hum Mol Genet* 1994;3:607-14.
- Estivill X. Complexity in a monogenic disease. *Nat Genet* 1996;12:348-50.

- 23 Kiesewetter S, Macek M, Davis C, *et al.* A mutation in CFTR produces different phenotypes depending on chromosomal background. *Nat Genet* 1993;5:274-8.
- 24 Castellani C, Bonizzato A, Mastella G. CFTR mutations and IVS8-5T variant in newborns with hypertrypsinemia and normal sweat test. *J Med Genet* 1997;34:297-301.
- 25 Chin S, Ranieri E, Gerace RL, *et al.* Frequency of intron 8 CFTR polythymidine sequence variant in neonatal blood specimens. *Lancet* 1997;350:1368-9.
- 26 Audrezet MP, Novelli G, Mercier B, *et al.* Identification of three novel cystic fibrosis mutations in a sample of Italian cystic fibrosis patients. *Hum Hered* 1993;43:295-300.
- 27 Highsmith WE, Burch LH, Zhou Z, *et al.* A novel mutation in the cystic fibrosis gene in patients with pulmonary disease but normal sweat chloride concentrations. *N Engl J Med*. 1994;331:974-80.
- 28 Travert G. Analyse de l'expérience mondiale de dépistage neonatal de la mucoviscidose par la dosage de la trypsine immunoreactive sanguine. *Mucoviscidose Depistage Neonatal et Prise en Charge Precoce*. Université de Caen, 1988, 1-23.
- 29 Cuppens H, Lin W, Jaspers M, *et al.* Polyvariant mutant cystic fibrosis transmembrane conductance regulator genes. The polymorphic (TG)_m locus explains the partial penetrance of the T5 polymorphism as a disease mutation. *J Clin Invest* 1998;101:487-96.

J Med Genet 2000;37:547-548

Further evidence for genetic heterogeneity of autosomal dominant disorders with accumulation of multiple deletions of mitochondrial DNA

EDITOR—Disorders of oxidative phosphorylation are highly heterogeneous from both a clinical and a genetic point of view. The nuclear as well as the mitochondrial genomes contain genes that are necessary for respiratory chain function. Consequently, different modes of inheritance are encountered in disorders of oxidative phosphorylation.

Single large scale deletions of mitochondrial DNA (mtDNA) usually occur in sporadic cases.¹ However, multiple deletions of mtDNA also occur in autosomal dominant disorders.² These deletions are generated de novo as somatic mutations in each affected subject. The nuclear gene defects predisposing to secondary mtDNA deletions in these patients remain unknown.

The disorder discovered by Zeviani *et al*³ was later found in several families and was called autosomal dominant progressive external ophthalmoplegia (ADPEO),³ as ptosis and external ophthalmoplegia are the major clinical findings.⁴⁻⁷ More generalised weakness of the skeletal muscles and sudden unexpected death are also common clinical features.⁴⁻⁷ Additional features vary among different families.⁴⁻⁶⁻⁸

Linkage analysis provided direct evidence for genetic heterogeneity of ADPEO. One locus predisposing to ADPEO in a Finnish family was assigned to chromosome 10q23.3-q24.3.³ Another locus was assigned to chromosome 3p14.1-p21.2 in three Italian families.⁹ In another Italian ADPEO family the disorder is linked to chromosome 4q34-q35.¹⁰

We previously reported three unrelated Belgian families with progressive external ophthalmoplegia and multiple deletions of mtDNA.⁶ Only one of these families was of sufficient size to examine cosegregation of PEO with the known loci on chromosomes 10q, 3p, and 4q.

Fig 1 shows the updated pedigree of the Belgian PEO family. Several male to male transmissions indicate clear autosomal dominant inheritance. The diagnosis of ADPEO was based on the clinical symptoms and the presence of multiple mtDNA deletions on Southern blots of muscle biopsy specimens in two patients. The detailed clinical features and the muscle biopsy findings with mtDNA analysis have been described elsewhere.⁶

Blood samples were obtained after informed consent. The primer sequences for the polymorphic DNA markers on chromosomes 3, 4, and 10 were obtained from the Genome Database (<http://gdbwww.gdb.org>). The linkage analysis was carried out by MLINK 5.1 using a disease gene frequency of 1/10 000. Since variable penetrance of the disease was shown in the 10q linked Finnish family,³ only affected subjects were included in our linkage analyses. Subjects were considered affected when clinical examination showed PEO and absent Achilles tendon reflexes (fig 1). Dead, but not clinically examined subjects were considered affected if there was a positive family history obtained from relatives and the appearance of PEO in photographs.

The average expected maximum lod score in computer simulation analysis was 1.5, assuming a 80% informative linked marker at 5% recombination distance from the PEO gene. In 500 simulated replicates, the maximum lod score obtained was 3.60. Linkage analysis excluded all three known loci (table 1). Few markers generated minor positive lod scores (Z) of 0.5 to 1 at large recombination distances (θ), but flanking markers and haplotype analysis clearly excluded the candidate regions.

Our data provide further evidence for the genetic heterogeneity of autosomal dominant PEO, indicating that

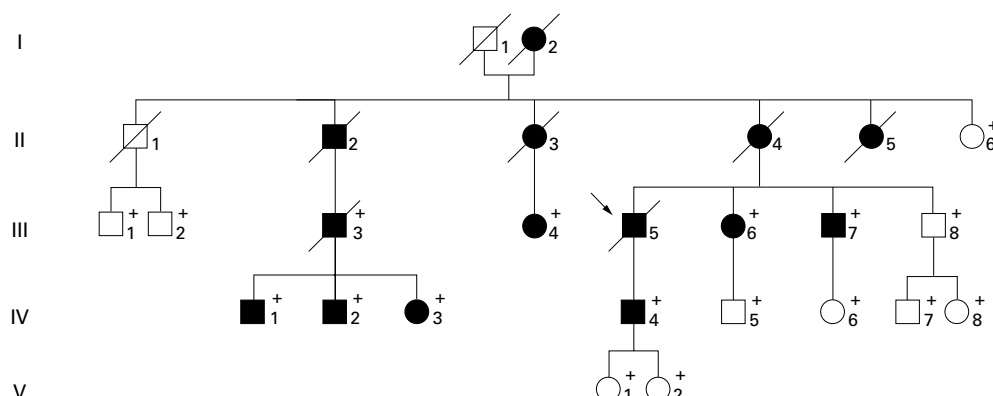


Figure 1 Pedigree of the autosomal dominant Belgian PEO family. Filled symbols indicate affected subjects. Subjects III.5 and III.7 had multiple mtDNA deletions on Southern blots of DNA isolated from skeletal muscle biopsies.⁶ Open symbols indicate healthy subjects. A plus sign (+) denotes subjects from whom DNA samples were available for genetic analysis. The proband is indicated by an arrow.

Table 1 Pairwise lod scores of chromosomes 3p, 4q, and 10q DNA markers in a Belgian ADPEO family. The 3p DNA markers are ordered from telomere to centromere and the 10q and 4q markers from centromere to telomere conform with their position on the genetic map (Whitehead Institute, <http://www-genome.wi.mit.edu/cgi-bin/contig/physmap>). For each marker the genetic distance excluded (exclusion limit) was calculated from the recombination distance at $Z=-2$

Marker	Lod score at $\theta=$								Exclusion limit
	0.00	0.01	0.05	0.10	0.20	0.30	0.40		
D3S3666	-3.59	-1.31	-0.48	-0.14	0.10	0.11	0.04	0.01	
D3S3553	-7.76	-3.02	-1.49	-0.84	-0.28	-0.08	-0.01	0.03	
D3S1300	-3.60	-1.02	-0.39	-0.18	-0.05	-0.02	-0.01	0.00	
D3S1312	-7.96	-2.87	-1.54	-1.03	-0.59	-0.36	-0.17	0.04	
D3S1600	-3.39	-1.22	-0.60	-0.38	-0.20	-0.12	-0.05	0.00	
D3S3571	-12.31	-4.63	-2.60	-1.78	-0.98	-0.51	-0.20	0.09	
D10S1750	-7.12	-2.05	-0.79	-0.35	-0.06	0.00	0.01	0.01	
D10S1773	-11.36	-4.23	-2.21	-1.40	-0.68	-0.33	-0.12	0.04	
D10S1731	-15.89	-5.79	-3.06	-1.95	-0.92	-0.42	-0.14	0.10	
D10S187	-11.48	-4.13	-2.10	-1.28	-0.56	-0.24	0.08	0.06	
D10S190	1.11	1.09	0.97	0.82	0.52	0.26	0.08		
D10S1757	-6.82	-2.00	-0.73	-0.30	0.02	0.03	0.02	0.01	
D10S1483	-3.66	-0.98	-0.35	-0.13	0.01	0.04	0.03	0.01	
D10S587	-7.34	-2.56	-1.19	-0.65	-0.19	-0.02	-0.02	0.04	
D10S1723	-11.36	-4.50	-2.41	-1.53	-0.72	-0.33	0.11	0.08	
D10S1656	-7.82	-3.10	-1.70	-1.09	-0.52	-0.23	-0.07	0.04	
D10S186	-2.62	0.04	0.58	0.68	0.58	0.35	0.12	0.00	
D10S1782	-7.22	-2.40	-1.09	-0.58	-0.18	-0.03	0.01	0.03	
D4S1554	-11.57	-3.96	-1.96	-1.18	-0.53	-0.24	-0.09	0.05	
D4S2924	-7.39	-2.49	-1.18	-0.68	-0.28	-0.12	-0.05	0.03	
D4S2299	-11.48	-4.36	-2.34	-1.52	-0.76	-0.37	-0.13	0.07	

at least four loci in the nuclear genome predispose to somatic mutations of mtDNA with accumulation of multiple mtDNA deletions. To localise the fourth disease locus, we will perform a random genome search in this Belgian family.

The different genes involved in autosomal dominant PEO may encode different functional polypeptide subunits of a single multi-enzyme complex or may be independently functioning molecules. The gene products may play a role in one single or even in several pathogenetic mechanisms resulting in this complex human disease. Indeed, there are several hypotheses of different pathogenetic mechanisms such as defects in mtDNA replication, defects in repair of damaged mtDNA, or in effective elimination of free oxygen radicals and secondary mtDNA damage. Cloning of one of the ADPEO genes may improve our understanding of how the nuclear and the mitochondrial genome interact. In mitochondrial neurogastrointestinal encephalomyopathy (MNGIE), an autosomal recessive disease, also associated with multiple deletions of skeletal muscle mtDNA deletions, functional mutations in the thymidine phosphorylase gene were recently reported.¹¹ A similar demonstra-

tion of molecular defects in autosomal dominant PEO genes might provide a rational basis for treatment or prevention of these disorders.

This work was supported in part by a grant of the Fund for Scientific Research-Flanders (FWO-6.3009.94.N).

GERT VAN GOETHEM*†‡
ANN LÖFGREN†‡
JEAN-JACQUES MARTIN*§
CHRISTINE VAN BROECKHOVEN†‡

*Division of Neurology, University Hospital of Antwerp (UZA), Antwerpen, Belgium

†Flanders Interuniversity Institute for Biotechnology (VIB), Born-Bunge Foundation (BBS), University of Antwerp (UIA), Antwerpen, Belgium

‡Laboratory of Molecular Genetics, Born-Bunge Foundation (BBS), University of Antwerp (UIA), Department of Biochemistry, Antwerpen, Belgium

§Laboratory of Neuropathology, Born-Bunge Foundation (BBS), University of Antwerp (UIA), Department of Medicine, Antwerpen, Belgium

Correspondence to: Dr Van Goethem, Laboratory of Molecular Genetics, Neurogenetics Group, University of Antwerp (UIA), Department of Biochemistry, Universiteitsplein 1, B-2610 Antwerpen, Belgium, vgoethe@uia.ua.ac.be

- Holt IJ, Harding AE, Morgan-Hughes JA. Deletions of muscle mitochondrial DNA in patients with mitochondrial myopathies. *Nature* 1988;331:717-19.
- Zeviani M, Servidei S, Gellera C, Bertini EW, DiMauro S, DiDonato S. An autosomal dominant disorder with multiple deletions of mitochondrial DNA starting at the D-loop region. *Nature* 1989;339:309-11.
- Suomalainen A, Kaukonen J, Amati P, Timonen R, Haltia M, Weissenbach J, Zeviani M, Somer H, Peltonen L. An autosomal locus predisposing to deletions of mitochondrial DNA. *Nat Genet* 1995;9:146-51.
- Servidei S, Zeviani M, Manfredi G, Ricci E, Silvestri G, Bertini E, Gellera C, Di Mauro S, Di Donato S, Tonali P. Dominantly inherited mitochondrial myopathy with multiple deletions of mitochondrial DNA: clinical, morphologic and biochemical studies. *Neurology* 1991;41:1053-9.
- Suomalainen A, Majander A, Wallin M, Setälä K, Kontula K, Leinonen H, Salmi T, Paetau A, Haltia M, Valanne L, Lonnqvist J, Peltonen L, Somer H. Autosomal dominant progressive ophthalmoplegia with multiple deletions of mtDNA: clinical, biochemical, and molecular genetic features of the 10q-linked disease. *Neurology* 1997;48:1244-53.
- Van Goethem G, Martin JJ, Löfgren A, Dehaene I, Tack P, Van Zandycke M, Ververken D, Ceuterick C, Van Broeckhoven C. Unusual presentation and clinical variability in Belgian pedigrees with progressive external ophthalmoplegia and multiple deletions of mitochondrial DNA. *Eur J Neurol* 1997;4:476-84.
- Zeviani M, Bresolin N, Gellera C, Bordoni A, Pannaci M, Amati P, Moggio M, Servidei S, Scarlato G, Di Donato S. Nucleus-driven multiple large scale deletions of the human mitochondrial genome: a new autosomal dominant disease. *Am J Hum Genet* 1990;47:904-14.
- Cormier V, Rötig A, Tardieu M, Colonna M, Saudubray JM, Munnich A. Autosomal dominant deletions of the mitochondrial genome in a case of progressive encephalomyopathy. *Am J Hum Genet* 1991;48:643-8.
- Kaukonen JA, Amati P, Suomalainen A, Rötig A, Piscaglia MG, Salvi F, Weissenbach J, Zeviani M, Somer H, Peltonen L. An autosomal locus predisposing to multiple deletions of mtDNA on chromosome 3p. *Am J Hum Genet* 1996;58:763-9.
- Kaukonen JA, Zeviani M, Comi G, Piscaglia MG, Peltonen L, Suomalainen A. Identification of the third autosomal locus predisposing to multiple deletions of mitochondrial DNA. *Am J Hum Genet* 1998;63(suppl 4):A163.
- Nishino I, Spinazzola A, Hirano M. Thymidine phosphorylase gene mutations in MNGIE, a human mitochondrial disorder. *Science* 1999;283:689-92.

J Med Genet 2000;37:548-551

Liebenberg syndrome: brachydactyly with joint dysplasia (MIM 186550): a second family

EDITOR—In 1973, Liebenberg¹ described a five generation pedigree with unusual anomalies of the elbows, wrists, and hands and autosomal dominant inheritance (MIM 186550). The same family was re-examined in 1985 by Beighton with corroboration of the distinctive phenotype.^{2,3} The most prominent features were dysplasia of all the bony components of the elbow joint, abnormally

shaped carpal bones, and brachydactyly. Since then, no other families have been described.

We report on a mother and two sons whose clinical and radiological features closely resemble those of Liebenberg syndrome.

The pedigree of our patients is showed in fig 1. When last examined, the two affected children, III.4 and III.5, were 3 years and 1 year old, respectively. Their older sister, III.3, was aged 6 and was thought to be unaffected. The affected mother, II.2, was 33 and her husband, II.3, 36 years old and were healthy and non-consanguineous. The mother's parents, I.1 and I.2, were said to be unaffected.

Patient III.5 was born at term. Pregnancy and delivery were uneventful. Birth weight was 3800 g, length 50 cm, and head circumference 35 cm. His development mile-

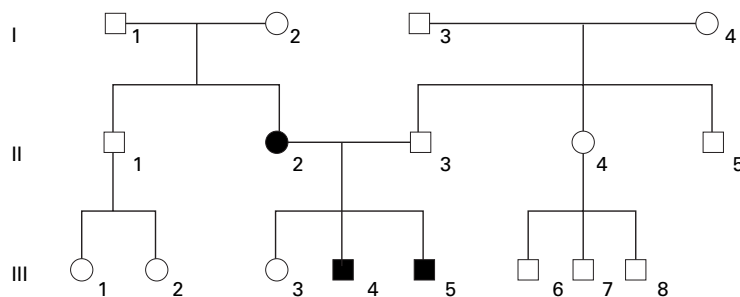


Figure 1 Pedigree of the patients. II.2 is 33 years old, III.4 is 3 years old, and III.5 is 1 year old.

stones were normal. At 1 year he was able to sit alone and spoke his first words. There were no health problems. His joint anomalies were noticed at birth.

We examined the patient at the ages of 6 months and 1 year. At 1 year weight was 12 kg (>90th centile), height 80.6 cm (>97th centile), and OFC 47 cm (>50th centile). In the "anatomical position", the elbow joints were slightly flexed and active extension from that position was not possible. Pronosupination was slightly limited. The wrist joints were radially deviated. Flexion, extension, abduction, and adduction at the wrists were somewhat stiff but almost normal in range. The fingers were short and bilateral camptodactyly of the fifth finger was present.

X rays of the arms, forearms, and hands showed enlarged and poorly modelled distal humeral, proximal radial, and proximal ulnar metaphyses, abnormally long radius and ulna, a very large triquetrum the size of that of a 3½ year old child, and shortness of all the components of the digital rays, but especially marked in the distal phalanges (fig 2). No synostoses were noted. X rays of the whole skeleton showed no other relevant anomalies.

Patient III.4 was born at term. Pregnancy and delivery were uneventful. Birth weight was 3400 g, length 45 cm, and head circumference 35 cm. Development milestones

were normal. He was able to sit alone at 9 months and to walk at 12 months. He spoke his first words at 12 months and the first sentences at 2 years. He had no health problems. His joint anomalies were noticed at birth.

We examined the patient at the ages of 2½ and 3 years. At 3 years weight was 18.5 kg (>97th centile), height was 106 cm (>97th centile), and OFC was 49.6 (>25th centile). Flexion at the elbow joints, radial deviation of the wrists, and limitation in the range of movement at the elbow and wrist joints were slightly more marked than in his younger brother. Brachydactyly, bilateral camptodactyly of the fifth fingers and partial bilateral syndactyly between the second and third fingers were evident. The x ray features were very similar to those of III.5. The size of the triquetrum was that of an 8 year old child (fig 3). His symptoms improved after one year of physiotherapy.

The mother, II.2, was 33 years old at the time of examination. Weight was 60 kg (>50th centile), height was 165 cm (>50th centile), and OFC was 53 cm (>25th centile). She denied any health problems and was of normal intelligence. Her joint anomalies had been present since birth and she had not noticed any worsening of her symptoms. She had never received any rehabilitation therapy.

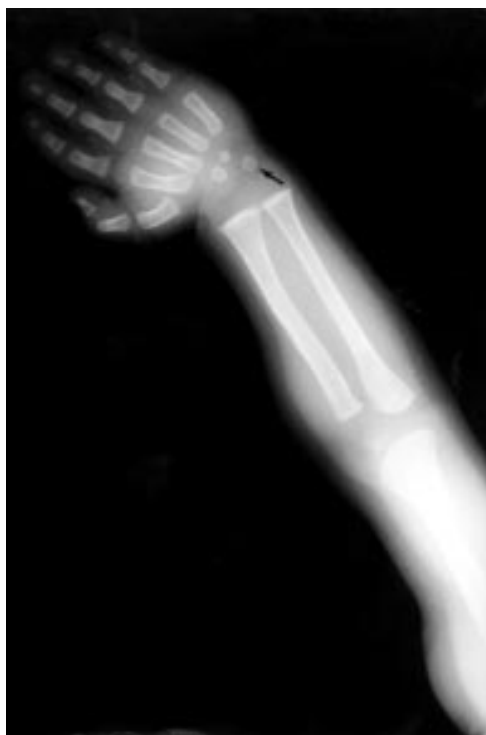

Figure 2 X ray of the hand and forearm of III.5 at 6 months showing enlarged and poorly modelled bony components of the elbow joint, a very large triquetrum (arrow) of the size of that of a 3½ year old child, and brachydactyly.

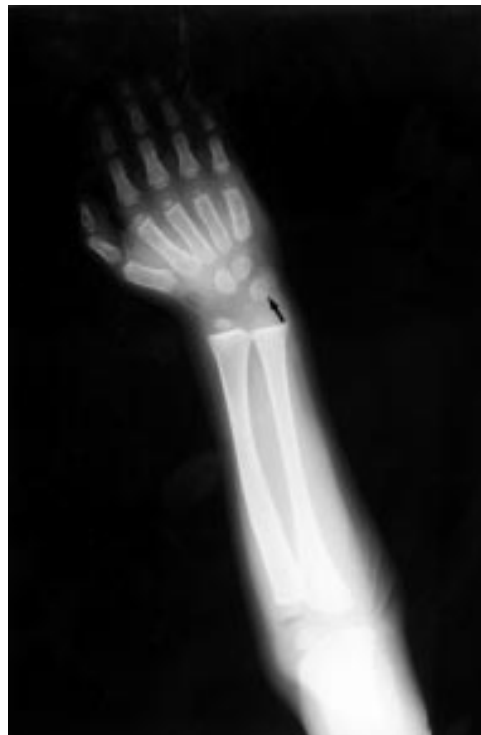

Figure 3 X ray of the hand and forearm of III.4 at 2½ years showing enlarged and poorly modelled bony components of the elbow joint, a very large triquetrum (arrow) of the size of an 8 year old child, and brachydactyly.

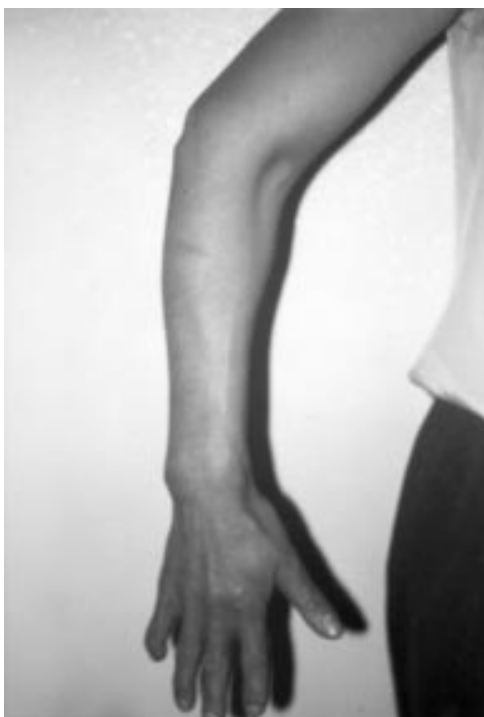

Figure 4 Elbow and forearm of II.2 at 33 years. Extension from this position was not possible.

In the anatomical position, flexion at the elbow joints was 10° and active extension from that position was impossible (fig 4). Pronosupination was slightly limited. The wrist joints were radially deviated. At the wrist, flexion was limited to about 60° while extension, abduction, and adduction were almost normal. The hands showed brachydactyly and bilateral camptodactyly of the fifth finger (fig 5).

X rays of the arms, forearms, and hands showed enlarged and poorly modelled distal humeral, proximal radial, and

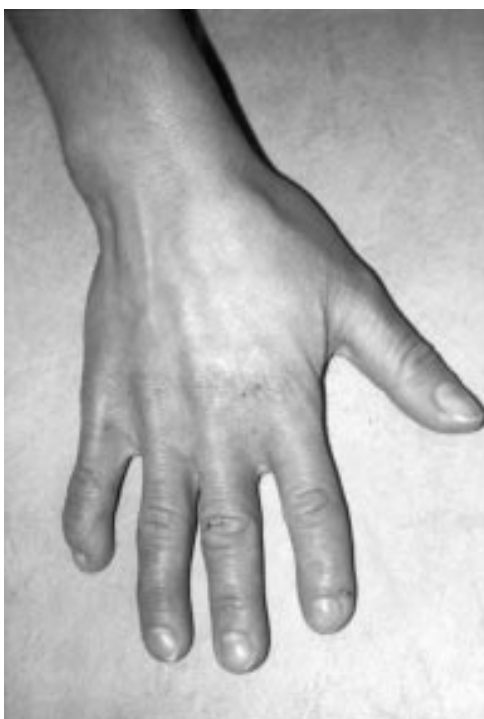

Figure 5 Hand of II.2 at 33 years showing brachydactyly and fifth finger camptodactyly.

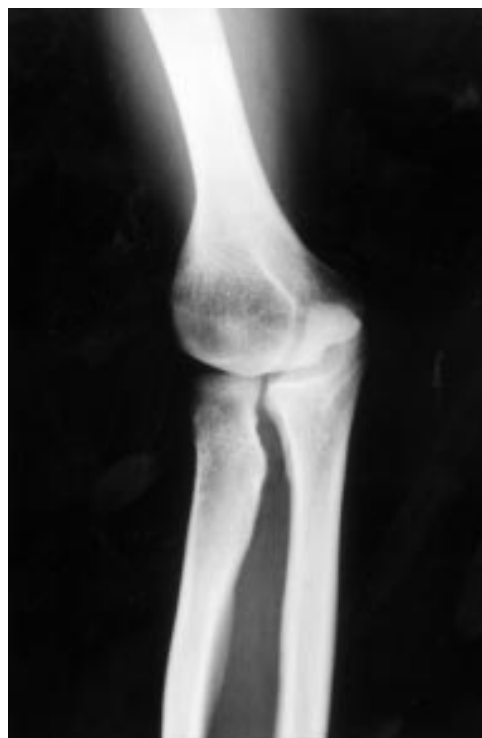

Figure 6 X ray of the elbow joint of II.2 at 33 years showing enlarged and poorly modelled bony components.

proximal ulnar metaphyses, abnormally shaped carpal bones, scaphoid-lunate fusion, large triquetrum, and shortness of all the components of the digital rays, especially marked at the distal phalanges (figs 6 and 7). No synostoses were present. X rays of the whole skeleton showed no other relevant anomalies.

The unusual association of brachydactyly, abnormally shaped carpal bones, and elbow dysplasia in our family and

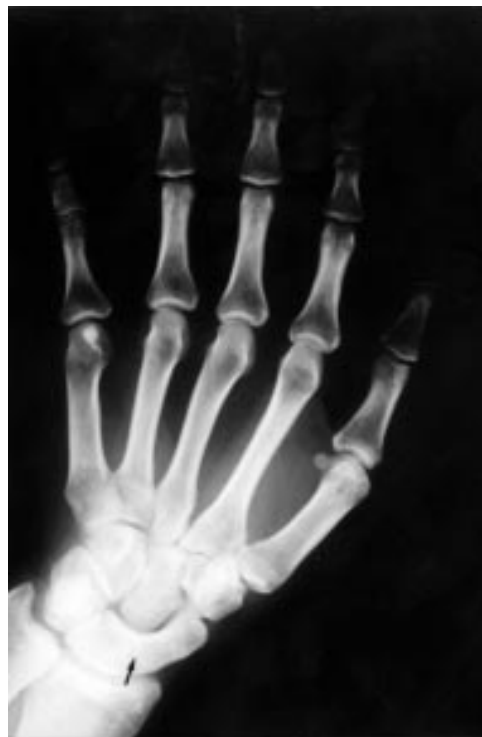

Figure 7 X ray of the hand of II.2 at 33 years showing abnormally shaped carpal bones, scaphoid-lunate fusion (arrow), large triquetrum, and brachydactyly.

that described by Liebenberg in 1973¹ could be ascribed to the same autosomal dominant clinical condition. Our patients showed only some slight differences from Liebenberg's family.

In our family, the bony components of the elbow joints were consistently enlarged and poorly modelled. In Liebenberg's patients the radial head had a "bulbous appearance" while the humeral condyles and the ulnar olecranon and coronoid processes were "underdeveloped". The large triquetrum and camptodactyly of the fifth fingers, which were described only in the 7 year old child of the family of Liebenberg,¹ were constant findings in our patients. Moreover, patient III.4 had bilateral partial syndactyly between the second and third fingers. Triquetropisiform fusion, which was present in all Liebenberg's patients, was not found in our family. However, since the ossification centre of the pisiform appears at about 10 years,⁴ triquetropisiform fusion would not be expected to be seen in the children III.4 and III.5. Yet, in the mother, II.2, the fusion is between the scaphoid and lunate.

The differential diagnosis between Liebenberg syndrome and the other skeletal disorders involving elbow dysplasia/carpal synostoses and brachydactyly, such as the multiple synostoses or facioaudiosymphalangism syndrome (MIM 186500),⁵ the tarsal, carpal, and digital synostoses syndrome (MIM 186400),⁶ and the Banki syndrome (MIM 109300)⁷ is essential for prognosis and genetic counselling. Indeed, Liebenberg syndrome seems to cause no other relevant problem apart from limited flexion-extension of the elbows and wrists while the evolution of the other disorders is often more severe.

The presence of tarsal synostoses and symphalangism clearly differentiates both the multiple synostoses syndrome (SYNS1) (MIM 186500) and the tarsal, carpal, and digital synostoses syndrome (MIM 186400) from Liebenberg syndrome which features only carpal synostosis. Moreover, most SYNS1 patients have conductive deafness and a characteristic facies with a broad hemicylindrical nose without alar flare. Our patients do not show any facial dysmorphism and, although audiological evaluation was not performed, they apparently have no significant hearing problem. No mention of facial dysmorphism and deafness was made in the paper of Liebenberg.¹ Finally, elbow dysplasia is not a feature of Banki syndrome.

The recent discovery that point mutations in the *NOG* gene in the 17q22 region are the cause of both proximal symphalangism (SYM1) and SYNS1⁸ raises the question of whether Liebenberg syndrome is also caused by mutations in the same gene. The *NOG* gene codes for the polypeptide noggin that acts as an inhibitor of bone morphogenetic proteins (BMP), which are members of the transforming growth factor β superfamily of signalling proteins (TGF β -FM).^{8,9} Thus, mutations in the *NOG* gene are likely to cause an increased BMP activity which leads to excess cartilage and failure of joint formation.⁹ Considering the wide variability of the phenotypic effects of *NOG* gene mutations, which range from simple symphalangism to the full SYNS1 syndrome, it would not be surprising if Liebenberg syndrome and some of the other syndromes featuring synostoses were also caused by *NOG* gene mutations.

G TIBERIO*
M C DIGILIO*
M GRAZIANI†
F TESTA‡
A GIANNOTTI*

*Servizio di Genetica Medica, IRCCS "Bambino Gesù", Piazza S Onofrio 4, 00165 Roma, Italy

†Servizio di Radiologia, IRCCS "Bambino Gesù", 00165 Roma, Italy

‡Reparto di Ortopedia, IRCCS "Bambino Gesù", 00165 Roma, Italy

Correspondence to: Dr Giannotti, giannotti@opbg.net

- 1 Liebenberg F. A pedigree with unusual anomalies of the elbows, wrists and hands in five generations. *S Afr Med J* 1973;47:745-7.
- 2 Beighton P. Cape Town, South Africa, personal communication to McKusick VA, Mar 13, 1985. McKusick VA. *Mendelian inheritance in man. Catalogs of human genes and genetic disorders*. 12th ed. Baltimore: Johns Hopkins University Press, 1998:entry 186550.
- 3 Beighton P. *Inherited disorders of the skeleton*. 2nd ed. Edinburgh: Churchill Livingstone, 1998:330.
- 4 Greulich WW, Pyle SI. *Radiographic atlas of skeletal development of the hand and wrist*. 2nd ed. California: Stanford University Press, 1959:16.
- 5 Hurvitz SA, Goodman RM, Hertz M, Katznelson MBM, Sack Y. The facio-audio symphalangism syndrome: report of a case and a review of the literature. *Clin Genet* 1985;28:61-85.
- 6 da-Silva EO, Filho SM, de Albuquerque SC. Multiple synostosis syndrome: study of a large Brazilian kindred. *Am J Med Genet* 1984;18:237-47.
- 7 Banki Z. Kombination erblicher Gelenk- und Knochenanomalien an der Hand. Zwei neue Roentgenzeichen. *Fortschr Roentgenstr* 1965;103:598-604.
- 8 Gong Y, Krakow D, Marcelino J, Wilkin D, Chitayat D, R Babul-Hirji, Hudgins L, Cremers CW, Cremers FPM, Brunner HG, Reinker K, Rimoin DL, Cohn DH, Goodman FR, Reardon W, Patton M, Francomano CA, Warman ML. Heterozygous mutations in the gene encoding noggin affect human joint morphogenesis. *Nat Genet* 1999;21:302-4.
- 9 Brunet LJ, McMahon JA, McMahon AP, Harland RM. Noggin, cartilage morphogenesis, and joint formation in the mammalian skeleton. *Science* 1998;280:1455-7.

J Med Genet 2000;37:551-553

Prenatal detection of trisomy for the entire long arm of chromosome 7

EDITOR—Duplication of the long arm of chromosome 7 is extremely rare; most of the reported cases are partial trisomies. The first and only previous case of complete 7q duplication was reported in 1978 by Wahrman *et al.*,¹ who described a proband at 3 years of age with a phenotype including a large face with sloping forehead, downward slanting palpebral fissures, bilateral epicanthic folds, low set, malformed ears, short neck, and genitourinary and renal anomalies. Here we report a case of duplication of the whole of 7q with phenotypic characteristics similar to most reported cases of partial trisomy 7q, which include frontal bossing, low set, malformed ears, micrognathia, hypertelorism, and skeletal abnormalities.^{2,3} The extent of the duplication and verification of breakpoints were determined using FISH probes.

The patient was delivered by caesarian section at 34 weeks' gestation to a G1, P0, 15 year old female. She was first seen at 33 weeks' gestation when a sonogram showed multiple congenital anomalies including severe hydrocephalus, a two vessel umbilical cord, bowed femur, clubbed feet, and dilated kidneys.

At birth, the infant was cyanotic with Apgar scores of 3 and 4 at one and five minutes, respectively. She weighed 3000 g and was 41 cm long. Head circumference was 44 cm (average at 34 weeks' gestation is 31.5 cm). Multiple congenital anomalies were noted in addition to those seen on sonogram and included contractures of both hands and feet, missing digits from the left hand, contorted right hand, bilateral hip dislocation, low set, malformed ears, micrognathia, small mouth, high arched palate, hypertelorism, wide, beak-like bridge of the nose, increased intermammary distance, and pulmonary hypoplasia (fig 1). Mild to moderate tricuspid regurgitation was present. The infant was placed on a ventilator with 100% oxygen, but saturation did not improve. The infant died six hours after birth from respiratory failure.

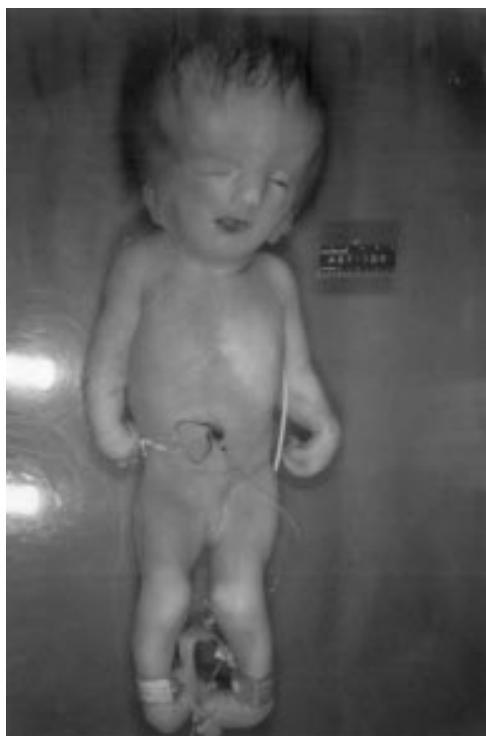

Figure 1 The patient showing the physical features including hydrocephalus, low set ears, micrognathia, deformed hands and feet, hypertelorism, and small mouth.

At necropsy, additional congenital anomalies were noted, including a dilated, tortuous right ureter with kinking (fig 2). The lungs were markedly hypoplastic with dilated airways and apical blebs. The hydrocephalic brain contained about 500 ml of CSF in markedly dilated ventricles. The mesencephalic aqueduct was markedly stenotic.

Cytogenetic studies on percutaneous umbilical blood sampling (PUBS) obtained at 33 weeks' gestation and cultured fibroblasts obtained from the umbilical cord at birth showed a duplication of the entire long arm of chromosome 7. This was confirmed by a FISH probe for the elastin gene at 7q11.2 (Oncor). Three copies of the FISH probes for the elastin gene and markers at 7q36 were present in each metaphase analysed, indicating that the patient was trisomic for chromosome 7q.

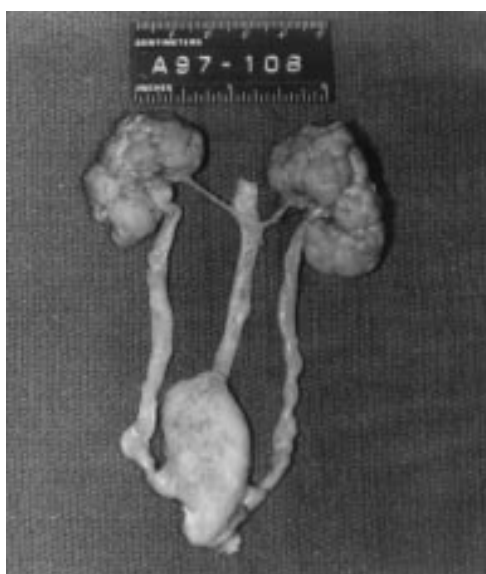


Figure 2 Dilated, tortuous right ureter with kinking noted at necropsy.

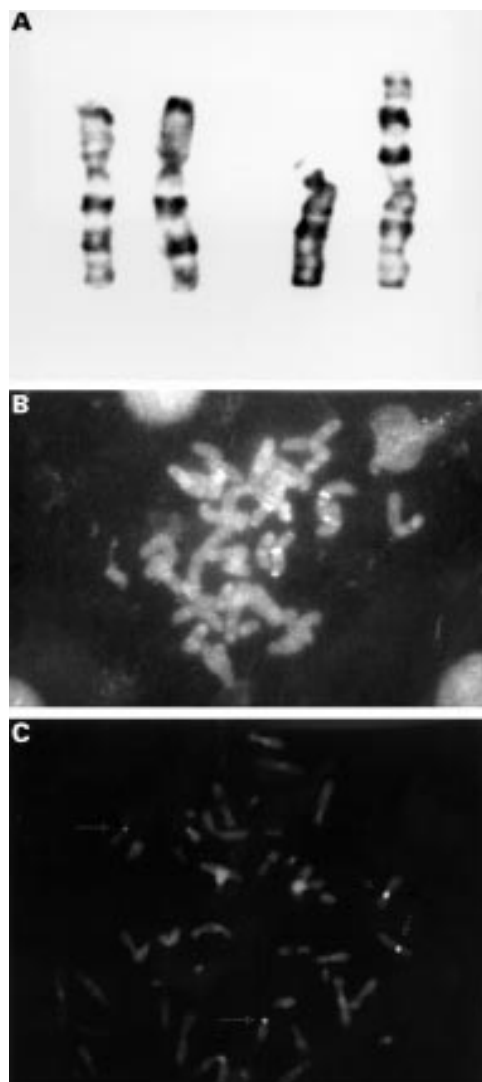


Figure 3 Cytogenetics. (A) Partial karyotype of the patient chromosomes 7 and 15, with the duplicated 7q translocated onto the short arm of chromosome 15 (on far right), (B) FISH confirmation of 7q duplication with three sets of signals for elastin and marker probes, and (C) FISH centromeric probes for 15 (long arrow) and 7 (short arrow). The *der*(15) is on the far left (long arrow).

Dual labelled centromere probes for 7 (Oncor) and 15 (Vysis) identified two centromeres each, with the 15 centromere on the derivative chromosome, confirming 7q and 15p breakpoints. The patient's karyotype was 46,XX,der(15)t(7;15)(q11.2;p11.2) (fig 3). The mother's karyotype was normal, 46,XX; however, no sample was available from the father for analysis. A fibroblast cell line established from umbilical cord on the patient is available through Coriell Cell Repositories (Camden, NJ).

Of all previously reported cases of trisomy 7q, there has been only one reported case involving duplication of the entire long arm of chromosome 7; we report the second case. Trisomy 7q produces abnormalities affecting virtually every system in the body including the central nervous system, the face, the musculoskeletal system, the heart, and the genitourinary system, but the combination of specific malformations may vary among patients. Our case showed a number of features similar to the previously reported case of duplication of the whole of 7q by Wahrman *et al.*¹ including frontal bossing, hypertelorism, low set, malformed ears, short neck, downward slanting palpebral fissures, and skeletal and kidney abnormalities. The features in our case not reported by Wahrman *et al.*¹ include hydrocephalus, bilateral clubbing

Table 1 Clinical characteristics of duplication 7q and trisomy 7

Clinical features	Our pt	q11,2 qter ¹	tri 7 ^{1,5}	q11.22 q11.23 ⁶	q11 q22 ⁷	q21.2 q22.1 ⁸	q22 q31 ^{2,3}	q22 q36.1 ⁹	q31 qter ^{2,3}	q32 qter ^{2,3}	q33 qter ¹⁰	q34 qter ¹¹	q36 qter ¹²
Developmental retardation		+			+	+	+		+	+	+	+	+
Hypertelorism	+	+	+		+	+	+	+	+	+	+	+	
Epicanthus		+											
Strabismus						+	+			+		+	
Low set ears	+	+	+	+	+	+	+		+	+	+	+	
Small palpebral fissures						+	+		+				
Frontal bossing	+	+			+	+	+	+			+		
Hypotonia			+			+	+			+	+	+	
Low birth weight		+							+	+	+		
Wide open fontanelle				+					+			+	
Small nose									+	+		+	
Cleft palate									+				
Microretrognathia	+		+			+			+		+		
Skeletal abnormalities	+	+	+						+	+	+	+	
Neonatal death	+		+					+	+				
Kyphoscoliosis										+		+	
Large head	+			+		+		+			+		+
High arched palate	+			+	+	+						+	
Short neck	+	+	+	+	+			+			+	+	
Widely spaced nipples	+			+									
Kidney abnormalities	+	+	+		+								
Lung hypoplasia	+		+										
Cardiac defect	+	+		+									

of the hands and feet, micrognathia, increased intermammary distance, and pulmonary hypoplasia.

The features in our case were also similar to those described in partial trisomies of 7q. The majority of reports of partial trisomy 7 result from a parental balanced translocation (reciprocal or insertion) or inversion 7. Clinical findings for duplications for 7q22q31, 7q31qter, and 7q32qter have been well accepted as having characteristic abnormalities.²⁻³ Because trisomies of other regions usually involve deletion of another chromosome region owing to missegregation of a balanced translocation or crossing over of an inverted 7, review of cases included those that only contained duplicated 7q material (table 1). Kidney abnormalities and lung hypoplasia have been reported in trisomy 7 and mosaic trisomy 7 cases.

We wish to thank Mrs Cindy Cutenese for her technical expertise.

B V NDAH*
JEFFREY A STEAD*
LEO R BRANCAZIO†
MARYBETH HUMMEL‡
SHARON L WENGER*

*Department of Pathology, West Virginia University, PO Box 9203, Morgantown, WV 26506-9203, USA

†Department of Obstetrics/Gynecology, West Virginia University, Morgantown, WV, USA

‡Department of Pediatrics, West Virginia University, Morgantown, WV, USA

Correspondence to: Dr Wenger, swenger@hsc.wvu.edu

- 1 Wahrman J, Cohen MM, Rosenmann A, Goitein R, Richler C, Dagan J. A long unidentifiable extra chromosomal segment - a possible duplication of human 7q. *Cytogenet Cell Genet* 1978;20:160-8.
- 2 Novales MA, Fernandez-Novoa C, Hevia A, San Martin V, Galera H. Partial trisomy for the long arm of chromosome 7. Case report and review. *Hum Genet* 1982;62:378-81.
- 3 Johnson DD, Michels VV, Aas MA, Dewald GW. Duplication of 7q31.2→7qter and deficiency of 18qter: report of two patients and literature review. *Am J Med Genet* 1986;25:477-88.
- 4 Yunis E, Ramirez E, Uribe JG. Full trisomy 7 and Potter syndrome. *Hum Genet* 1980;54:13-18.
- 5 Verp MS, Amarose AP, Esterly JR, Moawad AH. Mosaic trisomy 7 and renal dysplasia. *Am J Med Genet* 1987;26:139-43.
- 6 Hoo JJ, Lorenz R, Fischer A, Fuhrmann W. Tiny interstitial duplication of proximal 7q in association with a maternal paracentric inversion. *Hum Genet* 1982;62:113-16.
- 7 Kardon NB, Pollack L, David J, Broekman A, Krauss M. De novo duplication of the 7q11→q22 region. *J Med Genet* 1983;20:471-3.
- 8 Lukusa T, Fryns JP. Syndrome of facial, oral, and digital anomalies due to 7q21.2→q22.1 duplication. *Am J Med Genet* 1998;80:454-8.
- 9 Haslam JS, Norman AM. De novo inverted duplication of chromosome 7q. *J Med Genet* 1992;29:837-8.
- 10 Bartsch O, Kalbe U, Ngo TKN, Lettau R, Schwinger E. Clinical diagnosis of partial duplication 7q. *Am J Med Genet* 1990;37:254-7.
- 11 Romain DR, Cairney H, Stewart D, Columbano-Green LM, Garry M, Parslow MI, Parfitt R, Smythe RH, Chapman CJ. Three cases of partial trisomy 7q owing to rare structural rearrangements of chromosome 7. *J Med Genet* 1990;27:109-13.
- 12 Verma RS, Conte RA, Pitter JH. Tandem duplication of the terminal band of the long arm of chromosome 7 (dir dup(7)(q36→qter)). *J Med Genet* 1992;29:344-5.

J Med Genet 2000;37:553-557

Cockayne syndrome associated with low CSF 5-hydroxyindole acetic acid levels

EDITOR—Cockayne syndrome is a rare, clinically heterogeneous disorder, characterised by severe growth failure, cognitive impairment, characteristic facies, and photosensitivity. In the older patient the face has a characteristic aged appearance with sunken orbits, a relatively large, “beak-like” nose, and narrow mouth and chin. Both the central and peripheral nervous systems are involved in this neurodegenerative disorder with pigmentary retinopathy, delayed nerve conduction velocities, sensorineural hearing loss, progressive spasticity, and cerebellar involvement with

dysarthria, tremor, and ataxia. The cerebral histopathological changes most commonly seen are patchy demyelination of the subcortical white matter and microscopic calcifications throughout the central nervous system. Calcification of the basal ganglia may be visible on CT scan.¹⁻³ The diagnosis of Cockayne syndrome is made on clinical grounds in association with the failure of RNA synthesis in cultured fibroblasts or lymphoblastoid cells to recover to normal rates after UV-C irradiation.^{2,4} Inheritance is presumed to be autosomal recessive.¹

Here we report a patient with Cockayne syndrome in whom cerebrospinal fluid 5-hydroxyindole acetic acid was markedly reduced. To date there are no reports of abnormalities of the cerebrospinal fluid neurotransmitters in association with Cockayne syndrome. This finding may provide insight into the pathogenesis of the central nervous system abnormalities. Furthermore we have described the

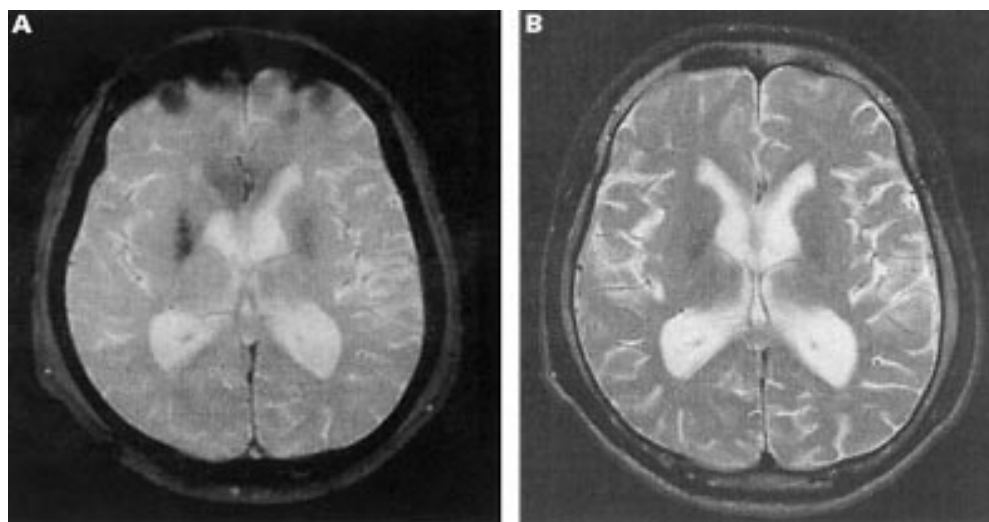


Figure 1 Spin echo T_2 weighted image and axial fast field sequence (A) shows decreased signal intensity foci in the globus pallidus, consistent with calcification. There is global cerebral atrophy with thinning of the white matter and ventricular dilatation. The pattern of myelination (B) approximates that of a 12 month old child.

patient's body composition in terms of resting energy expenditure, total body protein, fat, and bone mineral density which are relevant to management of the progressive cachexia associated with this disorder.

The proband, a 16 year old male, is the third child of consanguineous Sri Lankan parents and was born at term with a birth weight of 2722 g. His early expressive speech development was delayed, but gross and fine motor development were within normal limits. He initially presented at 8 years of age with tremor and poor motor coordination. A cerebral CT scan at that time was normal. He was re-evaluated at the age of 14 years. At this time he had an obvious intention tremor, gait ataxia, mild cognitive impairment, bilateral high tone sensorineural hearing loss, and poor growth. His parents reported extreme sun sensitivity, dry skin, and poor sweating in hot conditions.

On physical examination at 14 years, the proband had slightly sunken eyes, thin hair, and dry skin. His speech was

slow and mildly dysarthric. His height, 136 cm, and weight, 32 kg, were both below the 3rd centile (50th centile for 9 years) and head circumference, 52.5 cm, was on the 2nd centile (50th centile for 8 years). He had normal secondary sexual characteristics. Neurological examination showed cerebellar dysfunction with a marked, coarse, irregular intention tremor with overshooting, slow fine finger movements, and heel-shin incoordination. His gait was broad based and unsteady with flexed posture and toe walking. Dystonic posturing of his left arm and fingers were noted intermittently. There was minimal involuntary movement at rest. Muscle tone and power were within normal limits. Deep tendon reflexes were brisk, but his plantar reflexes were downward. There was no clinical evidence of peripheral neuropathy. Examination of his cranial nerves showed saccadic hypermetria, but no nystagmus. The pupils were poorly reactive to light and he was unable to converge. On neuropsychological testing there were specific deficits in

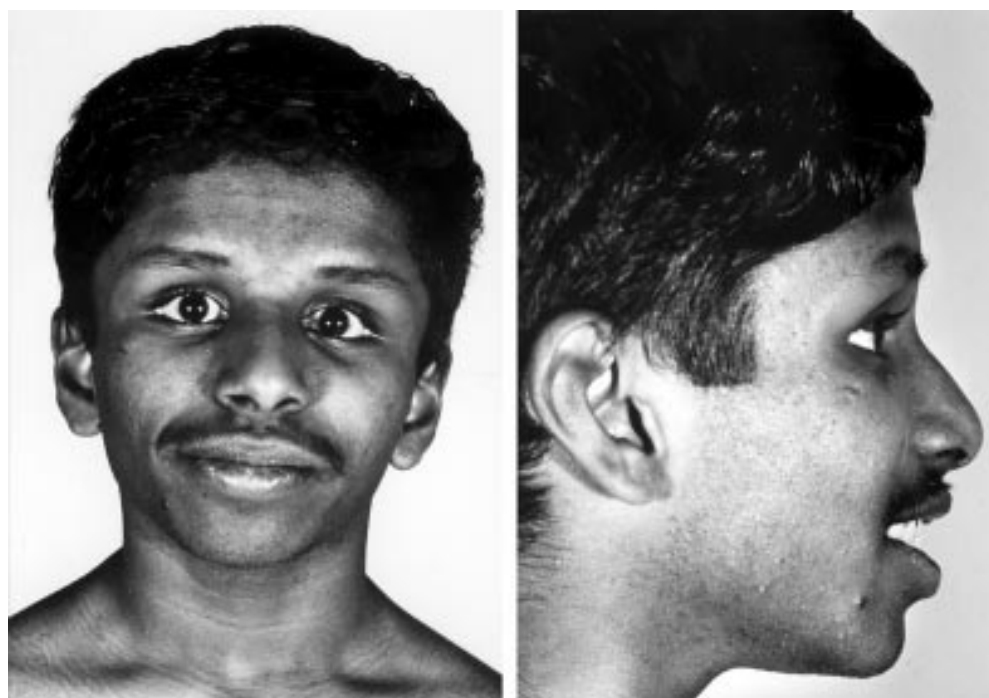


Figure 2 The proband at 16 years of age with the characteristic facial features of Cockayne syndrome with sunken eyes, "bird-like nose", and aged appearance.

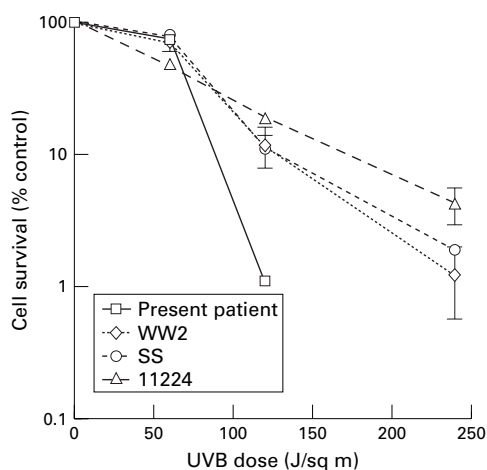


Figure 3 Survival of Epstein-Barr virus transformed B cells after irradiation with UVB. Results are expressed as % of the incorporation of ^3H -thymidine three days after irradiation. The results of our patient are shown together with those from cell strains from three normal controls (WW2, SS, 11224). These results illustrate the marked sensitivity to UVB light, with only 1% of cells surviving 100 J/sq m as compared to doses of 250 J/sq m and over required to achieve similar survival rates in the control cells.

short term memory, abstract reasoning, skills of generativity, and mental flexibility.

A repeat CT scan at 14 years of age showed generalised cerebral atrophy and calcification of the globus pallidus, which on MRI scan presented as decreased signal intensity of the globus pallidus (fig 1). In addition, there was atrophy of the cerebellum, temporal lobe structures, hippocampal formation, and brain stem. The pattern of myelination approximated that of a 12 month old child. Nerve conduction studies showed absent sensory action potentials and moderately slowed motor conduction (29 m/sec at the right common peroneal nerve). There was segmental demyelination and onion bulb formation on sural nerve biopsy.

Other investigations at this time included a full blood count, serum electrolytes, liver function tests, calcium, phosphorus, glucose, parathyroid hormone, copper, caeruloplasmin, 25-hydroxycalciferol, uric acid, cholesterol, triglycerides, thyroid function tests, vitamin A, vitamin D, vitamin E, vitamin B12, α -fetoprotein, urinary amino and organic acid analyses, very long chain fatty acids, phytanic acid, lysosomal enzymes, transferrin isoforms, trinucleotide repeat expansion studies for spinocerebellar ataxia types 1, 2, and 3, Friedrich's ataxia, Machado-Joseph disease, dentatorubropallidoluysian atrophy, and a karyotype. All investigations were normal. Analysis of mitochondrial respiratory chain enzymes in skeletal muscle showed a borderline low complex III activity relative to protein (36% relative to control mean), but normal relative to citrate synthase (74% of control mean). The common mitochondrial DNA point mutations for MELAS, MERFF, NARP, and Leigh syndrome were not detected in skeletal muscle DNA.

Cerebrospinal fluid protein was raised above the normal range on two occasions, 0.76 g/l and 0.65 g/l (normal range <0.3 g/l). Cerebrospinal fluid and plasma lactates were normal. On analysis of cerebrospinal fluid neurotransmitters, there was a low 5-hydroxyindole acetic acid level, 0.03 $\mu\text{mol/l}$ (normal range 0.13-0.21 $\mu\text{mol/l}$) and a normal homovanillic acid level with a ratio of 5-hydroxyindole acetic acid:homovanillic acid of 0.1 (normal 0.3-0.8).⁵ Cerebrospinal fluid amino acid levels including tryptophan were normal.⁶ Peripheral serotonin levels, urinary 5-hydroxyindole acetic acid, and platelet serotonin were also normal, as were plasma phenylalanine levels and dihydropteridine reductase activity. In view of these findings a

primary disorder of central serotonin metabolism was considered and the proband started treatment with 5-hydroxytryptophan, 1 mg/kg/day.

Over a two year period the dose of 5-hydroxytryptophan was gradually increased to 5 mg/kg/day. There was no obvious clinical improvement, but on the other hand, his cognitive function, tremor, and gait have not deteriorated and cerebral MRI scan showed no change. During this period, however, he developed a pigmentary retinopathy, lost 3 kg in weight, and his facial appearance came to resemble a "cachectic bird-nose dwarf"⁷ with sunken eyes (fig 2). Despite continued treatment with 5-hydroxytryptophan, cerebrospinal fluid levels of 5-hydroxyindole acetic acid on two further occasions have remained markedly low (0.02 and 0.03 $\mu\text{mol/l}$).

The clinical diagnosis of Cockayne syndrome was confirmed by survival studies of Epstein-Barr virus transformed B cells after irradiation with UVB⁷ (fig 3). These studies show that the proband's cells were very sensitive to irradiation, with only 1% of cells surviving a dose of 100 J/sq m UVB. In comparison, the normal controls' cells did not approach 1% survival until irradiated with doses of 250 J/sq m and over. To confirm the Cockayne phenotype further, the rate of RNA polymerase II transcription in the lymphoblastoid cells was compared with control lymphoblastoid cells. The constitutive incorporation of ^{14}C -uridine over 90 minutes was found to be $64 \pm 2\%$ ($n=4$) of the control lymphoblastoid cells (after normalisation against thymidine incorporation). This is within the 40-70% range for Cockayne syndrome lines reported by Balajee *et al.*,⁴ who also found that xeroderma pigmentosa cells had the same rate of RNA synthesis as controls.

Because of progressive weight loss, the proband was referred for nutritional assessment. The resting energy expenditure measured by indirect calorimetry was 75% of the predicted value, 3856 kJ/24 h, with a predicted resting energy expenditure based on age, sex, height, and weight for healthy children of 5135 kJ/24 h.⁸ The respiratory quotient was 0.89, indicative of appropriate nutritional intake.

Table 1 Clinical features previously reported in Cockayne syndrome and those seen in our patient

Clinical feature	Reported in Cockayne syndrome*	Present in this patient
Age of onset	3-5 y ²	8 y
Psychomotor development		
Delayed	50/131 (38) ¹	+
Central nervous system		
Movement disorder	4/131 (<5) ¹	+
Tremor	42/131 (32) ¹ 12/24 (50) ³	+
Speech abnormality	28/131 (21) ¹	+
Gait abnormality	35/131 (27) ¹ 25/27 (92) ³	+
Basal ganglia calcification	21/47 (45) ¹	+
Ophthalmological		
Pigmentary retinopathy	70/128 (55) ¹ 13/24 (54) ³	+
Cataracts	46/128 (36) ¹ 5/23 (22) ³	-
Optic atrophy/hypoplasia	43/128 (34) ¹	-
Nystagmus	27/128 (21) ¹	-
Inability to converge	Not reported	+
Unreactive pupils	Not reported	+
Hearing loss	47/78 (60) ¹ 16/27 (59) ³	+
Dental caries	43/50 (86) ¹ 9/14 (64) ³	-
Skin photosensitivity	67/92 (73) ¹ 24/25 (96) ³ (100) ^{1,3}	+
Growth failure		+
Biochemical investigations		
Increased cerebrospinal fluid protein	19/30 (63) ¹	+
Decreased cerebrospinal fluid 5-hydroxyindole acetic acid	Not reported	+

*Number reported and percentage in brackets with reference.

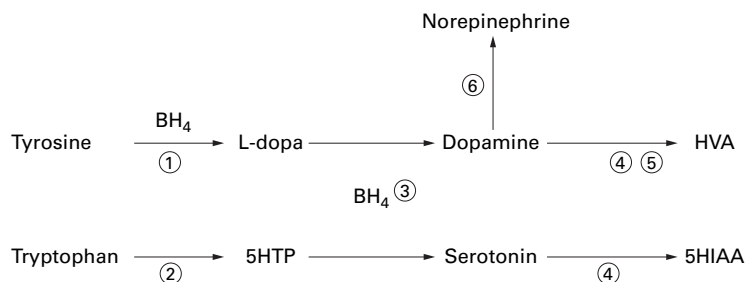


Figure 4 Synthetic and catabolic pathway of serotonin and dopamine. 5-hydroxyindole acetic acid is formed initially from tryptophan in a reaction catalysed by tryptophan hydroxylase ② to form 5-hydroxytryptophan (5HTP), which requires molecular oxygen and tetrahydrobiopterin (BH₄) for its activity. 5-hydroxytryptophan is decarboxylated by pyrimidine dependent aromatic L-amino acid decarboxylase ③ to form the active neurotransmitter serotonin. Serotonin is catabolised by monoamine oxidase ④ to form 5-hydroxyindole acetic acid (5HIAA). Tyrosine is metabolised by tyrosine hydroxylase ① to L-dopa. Aromatic L-amino acid decarboxylase ③ is also required for the decarboxylation of L-dopa to dopamine, which is then catabolised to homovanillic acid by monoamine oxidase and catechol O-methyl-transferase ⑤.

Total body protein measured by neutron capture analysis⁹ was low for age (65%) but above predicted for weight (112%), height (112%), and lean body mass (108%). Total body bone mineral density measured by dual energy x ray absorptiometry¹⁰ was on the 50th centile for age, 1.141 g/cm³. Total body fat tissue measured by dual energy x ray absorptiometry was 31.2%.

Our patient's clinical features are consistent with the diagnosis of Cockayne syndrome (table 1). Diagnostic criteria include growth failure after normal or slightly low birth weight, neurological dysfunction with cerebral white matter involvement plus at least three of the following features: cutaneous photosensitivity, progressive pigmentary retinopathy/cataracts, optic disc atrophy, miotic pupils or decreased lacrimation, sensorineural hearing loss, dental caries, short stature, and a characteristic physical appearance of "cachectic dwarfism".¹ Atypical features in our patient include later age of onset of neurological signs, absence of dental caries, and only mild cognitive impairment. The diagnosis of Cockayne syndrome was supported by finding hypersensitivity to UV light in Epstein-Barr virus transformed lymphoblasts. The pathogenesis of Cockayne syndrome is poorly understood. The cells of patients with Cockayne syndrome are hypersensitive to the lethal effects of UV light because they have a defective subpathway of nucleotide excision repair known as "transcription coupled repair".¹¹ Cockayne syndrome is genetically heterogeneous. Two disease genes have been identified, *CSB* on chromosome 10q11 and the *CSA* gene maps to chromosome 5.^{12, 13} Both proteins play an essential role in preferential repair of transcription blocking lesions from active genes.¹⁴ The *CSB* protein is a member of the SW12/SNF2 family of ATPases whose function is thought to involve remodelling of protein-DNA interactions, such as chromatin structure in different situations. The *CSA* gene encodes a "WD repeat" protein.¹³

A unique finding in our patient was very low cerebrospinal 5-hydroxyindole acetic acid and normal homovanillic acid levels on three separate occasions. The peripheral serotonin levels were normal. The metabolic pathways of 5-hydroxyindole acetic acid and homovanillic acid are shown in fig 4. The concentrations of 5-hydroxyindole acetic acid and homovanillic acid in the cerebrospinal fluid are thought accurately to reflect the turnover of catecholamine neurotransmitters.¹⁵ The low 5-hydroxyindole acetic acid, in association with normal tryptophan and homovanillic acid in the cerebrospinal fluid and normal peripheral serotonin, is suggestive of low brain serotonin turnover with normal dopamine turnover and may suggest a primary central serotonin deficiency, a selective serotonergic tract degeneration, or an isolated central nervous system tryptophan hydroxylase deficiency. This finding in our patient may provide some insight into the

mechanism of the neurological complications and the inattention of Cockayne syndrome given the putative roles of serotonin in control of movement and appetite. We treated our patient with 5-hydroxytryptophan (5 mg/kg/day) in an attempt to increase his cerebrospinal fluid 5-hydroxyindole acetic acid levels, with no change in levels observed. However, from a clinical point of view, he has had no further deterioration in cognitive or neurological function.

The cause of death in the majority of cases of Cockayne syndrome has been secondary to inanition and thus attention to nutrition is essential to patient care and well being.¹ Although our patient was always small for his age, he recently showed accelerated weight loss. In the setting of premature aging we predicted an increased metabolic rate, but, surprisingly, detailed energy expenditure studies indicated a lowered metabolic rate. This is similar in subjects with anorexia nervosa, whose resting energy expenditure is reduced when compared to healthy, aged matched controls.¹⁶ With re-feeding, however, the resting energy expenditure in anorexia nervosa subjects normalises, with concomitant increases in body weight. It would therefore appear possible to manage Cockayne syndrome patients with programmes that correct the energy deficits, documented by energy expenditure studies. Whether such strategies will prevent deterioration in nutritional status remains to be shown.

We would like to thank Dr P McVeagh, Department of Paediatrics, Royal Alexandra Hospital for Children, for referring this patient to the Neurogenetic Service. We would also like to thank Ms Jane Allen, Department of Nutrition and Dietetics, Royal Alexandra Hospital for Children, for performing the energy expenditure studies, Mr Nick Hayward for transforming our patient's B cells, and Dr Adam Steinberg, Department of Radiology, Royal Alexandra Hospital for Children for interpreting the MRI findings.

C J ELLAWAY*†
A DUGGINS‡
V S FUNG‡
J W EARL§
R KAMATH¶
P G PARSONS**
J A ANTONY††
K N NORTH†††

*Western Sydney Genetics Program, Royal Alexandra Hospital for Children, NSW, Australia

†Department of Paediatrics and Child Health, University of Sydney, NSW, Australia

‡Department of Neurology, Westmead Hospital, Australia

§Department of Biochemistry, Royal Alexandra Hospital for Children, NSW, Australia

¶Department of Gastroenterology, Royal Alexandra Hospital for Children, NSW, Australia

**Queensland Institute of Medical Research, Australia

††Department of Neurology, Royal Alexandra Hospital for Children, NSW, Australia

†††Neurogenetics Research Unit, Royal Alexandra Hospital for Children, NSW, Australia

Correspondence to: Dr North, Department of Paediatric and Child Health, Royal Alexandra Hospital for Children, PO Box 3515, Parramatta 2124, NSW, Australia, KathrynN@nch.edu.au

- 1 Nance MA, Berry SA. Cockayne syndrome: review of 140 cases. *Am J Med Genet* 1992;42:68-84.
- 2 Lehmann AR, Thompson AF, Harcourt SA, Stefanini M, Norris PG. Cockayne's syndrome: correlation of clinical features with cellular sensitivity of RNA synthesis to UV irradiation. *J Med Genet* 1993;30:679-82.
- 3 Kennedy RM, Rowe VD, Kepes JJ. Cockayne syndrome: an atypical case. *Neurology* 1980;30:1268-72.
- 4 Balajee AS, May A, Dianov GL, Freidberg EC, Bohr VA. Reduced RNA polymerase II transcription in intact and permeabilized Cockayne syndrome group B cells. *Proc Natl Acad Sci USA* 1997;94:4306-11.
- 5 Semerdjian-Rouquier L, Bossi L, Scatton B. Determination of 5-hydroxytryptophan, serotonin and 5 hydroxyindole acetic acid in rat and human brain fluids by reversed-phase high-performance liquid chromatography with electrochemical detection. *J Chromatogr* 1981;218:663-70.
- 6 Goldsmith RF, Earl JW, Cunningham AM. Determination of delta-aminobutyric and other amino acids in cerebrospinal fluid of pediatric patients by reversed-phase liquid chromatography. *Clin Chem* 1987;33:1736-40.
- 7 Maynard K, Parsons PG. Cross sensitivity to methylating agents, hydroxyurea and methotrexate in human tumour cells of the Mer- phenotype. *Cancer Res* 1986;46:5009-13.
- 8 Scofield WN, Schofield C, James WPT. Basal metabolic rate - review and prediction, together with an annotated bibliography of source material. *Hum Nutr Clin Nutr* 1995;39C(suppl 1):4-41.
- 9 Baur LA, Allen BJ, Rose A, Blagojevic N, Gaskin KJ. A total body nitrogen facility for paediatric use. *Phys Med Biol* 1991;36:1363-75.
- 10 Allen JR, Humphries IR, Waters DL, Roberts DC, Lipson AH, Howman-Giles RG, Gaskin KJ. Decreased bone mineral density in children with phenylketonuria. *Am J Clin Nutr* 1994;59:419-22.
- 11 Maelly DL, Tanganelli B, Colella S, Steingrimsdottir H, van Gool AJ, Troelstra C, Stefanini M, Lehmann AR. Molecular analysis of mutations in the CSB (ERCC6) gene in patients with Cockayne syndrome. *Am J Hum Genet* 1998;62:77-85.
- 12 Troelstra C, Landsvater RM, Wiegant J, van der Ploeg M, Viel G, Buys CH, Hoeijmakers JH. Localisation of the nucleotide excision repair gene ERCC6 to human chromosome 10q11-q21. *Genomics* 1992;12:745-9.
- 13 Henning KA, Li L, Iyer N, McDaniel LD, Reagan MS, Legerski R, Schultz RA, Stefanini M, Lehmann AR, Mayne LV, Friedberg EC. The Cockayne syndrome group A gene encodes a WD repeat protein that interacts with CSB protein and a subunit of RNA polymerase II TFIIF. *Cell* 1995;82:555-64.
- 14 Citterio E, Rademakers S, van der Horst GT, van Gool AJ, Hoeijmakers JH, Vermeulen W. Biochemical and biological characterisation of wild-type and ATPase-deficient Cockayne syndrome B repair protein. *J Biol Chem* 1998;273:11844-51.
- 15 Hyland K. Abnormalities of biogenic amine metabolism. *J Inher Metab Dis* 1993;16:676-90.
- 16 Schebendach JE, Golden NH, Jacobson MS, Hertz S, Shenker IR. The metabolic responses to starvation and refeeding in adolescents with anorexia nervosa. *Ann NY Acad Sci* 1997;817:110-19.

J Med Genet 2000;37:557-559

Unilateral lobar pulmonary agenesis in sibs

EDITOR—Pulmonary agenesis is an extremely rare congenital malformation which has been classified morphologically by the extent to which bronchopulmonary tissue is absent. Spencer¹ divided pulmonary agenesis into (1) bilateral complete agenesis, (2) unilateral agenesis with (a) complete absence of bronchi, (b) rudimentary bronchus present but no pulmonary tissue, or (c) poorly developed main bronchus with poorly organised parenchyma, and (3) lobar agenesis. The incidence of this rare condition is not known. According to the calculations of Mardini and Nyhan² it may range between 0.0034 and 0.0097%. Familial pulmonary agenesis is even more uncommon. We found only two published reports of affected sibs.^{3,4} One pair of sibs had agenesis of the right upper and middle lobes³ and the other pair suffered from bilateral agenesis.⁴

The paucity of such observations prompts us to report another instance of pulmonary agenesis in a brother and a sister of healthy and non-consanguineous parents. The family history was unremarkable and both pregnancies were uneventful. The mother had no infections and denied any abuse of teratogenic substances. Chromosomes were not studied in either case.

The first child, a female, was delivered spontaneously at term with a birth weight of 3500 g. Birth length and head circumference were not recorded. The mother was 27 years old and the father 36 years old. At the age of 11 months she was admitted to hospital because of stridor and dyspnoea. The interpretation of the chest x ray was spontaneous pneumothorax on the left side with dextrocardia and compression atelectasis of the right upper lobe. Over the following years, she suffered from asthmatic bronchitis secondary to recurrent infections. Psychomotor development was within the normal range. Pulmonary re-evaluation at the age of 12 years, including bronchoscopy, showed a suspicion of partial agenesis of the right lung. At the age of 24 years her bronchial asthma deteriorated. Ten years later she was admitted to hospital because of decompensated cor pulmonale. Since then she has had repeated episodes of acute cardiopulmonary decompensation. She died at the age of 42 years following a further episode of decompensated cor pulmonale. Necropsy disclosed dextrocardia, agenesis of the middle lobe, aplasia of the upper

lobe, and hypoplasia of the lower lobe of the right lung with hypoplasia of the right pulmonary artery.

The younger brother was born at term six years after his sister. Birth weight was 2980 g and length 48 cm. From early on, tachypnoea, dyspnoea, and feeding difficulties were noticed. Physical examination showed diminished breath sounds on the right upper side with the cardiac impulse shifted to the right side and a systolic heart murmur. Chest x ray (fig 1) showed no heart on the left side but a hypervoluminous left lung with prominent vasculature. The carina projected at the level of T6 and the right main stem bronchus seemed sharply cut off at its lower end. The right side was reduced in volume and seemed almost completely opacified except for a median lucency from herniated left lung. No skeletal abnormalities were visible. At the age of 7 months, he was treated for right sided pneumonia. Two months later he was admitted to hospital because of severe asthmatic bronchitis. There was a rapid deterioration leading to respiratory arrest. Necropsy disclosed agenesis of the right upper lobe, partial atelectasis of the remaining right lung, severe hypoplasia of the right pulmonary artery, dextrocardia, hypertrophy of the right atrium and ventricle, a patent foramen ovale, and a defect in the upper part of the ventricular septum. Furthermore, there was bilateral meatal ureteral stenosis with hydronephrosis and hydronephrosis, a small accessory spleen, and mild hydrocephalus internus.

In the review on agenesis of the lung by Gilbert and Opitz,⁵ approximately 200 patients with unilateral involvement were found. In 70% of cases the left side was involved and males predominated over females. Associated malformations were present in 50% of the cases. Major anomalies included congenital heart defects, spinal anomalies, anal atresia, tracheo-oesophageal atresia, spleen anomalies, diaphragmatic hernia, renal anomalies, cleft palate, and limb and facial defects.⁶ Cunningham and Mann⁷ found that ipsilateral anomalies of the first and second branchial arch or radial ray defects or both are the most common overt malformations. In contrast to bilateral agenesis of the lung, unilateral absence is compatible with life, but has a high mortality, most likely because of the presence of associated malformations/infections of the remaining lung tissue. Infants with right sided lung agenesis have a higher mortality and die significantly earlier. This is probably related to a more severe mediastinal and cardiac displacement into the right chest.⁸ Survival to adult age is possible

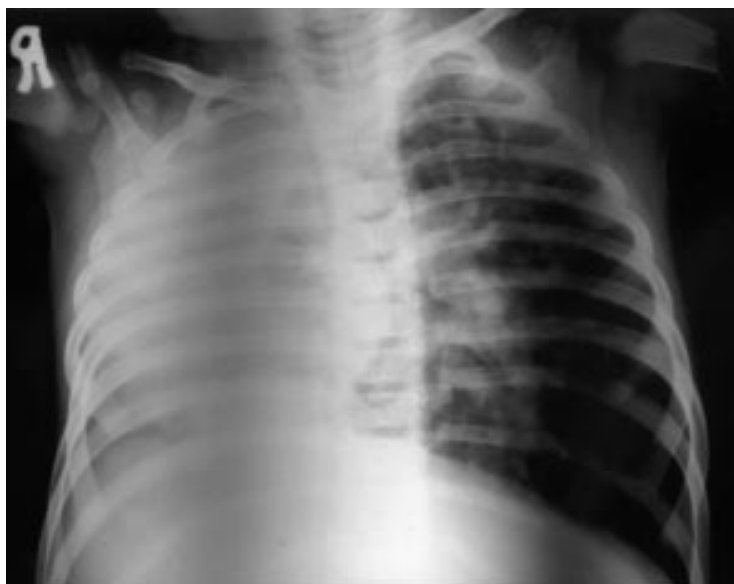

Figure 1 Chest x ray of patient 2 showing an almost completely opacified right chest.

as shown in our patient 1 or in a case with agenesis of the left lung detected at necropsy in a 72 year old woman.⁹

Most cases present in the neonatal period with non-specific respiratory symptoms such as cyanosis, tachypnoea, dyspnoea, stridor, or feeding difficulties. Physical examination may be normal, but can show diminished breath sounds on the affected side with the heart and mediastinum shifted to the ipsilateral side. Chest x rays which show a homogeneous density in one hemithorax suggest the diagnosis, but endoscopic, bronchographic, and echocardiographic studies, as well as computerised tomography are necessary for confirmation.

The aetiology of lung agenesis remains unknown. According to the possible associated anomalies, this rare malformation has been discussed as part of the VACTERL association¹⁰ and Goldenhar syndrome.¹¹ Warkany *et al*¹² induced pulmonary agenesis of one lung, but also other major malformations of the eyes and cardiovascular and urogenital systems by maternal gestational vitamin A deficiency in rats. Chromosomes were not studied in the older reports. However, Say *et al*¹³ described a patient with agenesis of the left lung who had a duplication of the region 2p21→p24 resulting in a partial trisomy 2p and Schober *et al*¹⁴ reported a case with left pulmonary agenesis and associated malformations in partial trisomy 2p (p21→pter) and 21q (pter→q21) owing to an unbalanced segregation of a maternal reciprocal translocation t(2;21). The minimal overlapping region of duplication includes the segment 2p21→p24. Therefore, Say and Carpenter¹⁵ suggested studying patients with pulmonary agenesis for the presence of such a duplication. Unilateral agenesis has also been documented in trisomy 18¹⁶ and in trisomy of a C group chromosome.¹⁷

Pulmonary agenesis in twins was reviewed by Lehmann.¹⁸ In female monozygotic twins, one sister had agenesis of the left and the other agenesis of the right lung.¹⁹ Yount²⁰ documented agenesis of the right lung in concordantly affected monozygotic twins, while others found pulmonary agenesis in only one of monozygotic twins.^{21, 22} Concordant occurrence of congenital malformations in monozygotic twins does not necessarily imply a genetic cause and vice versa.²³

The only clear indication of possible autosomal recessive inheritance of unilateral pulmonary agenesis so far was the family reported by Brimblecombe.³ The healthy parents were first cousins and had two normal children and two

affected girls with agenesis of the right upper and middle lobes. Our report is the second case of unilateral lobar pulmonary agenesis in sibs and supports the hypothesis of an autosomal recessively inherited disease. Alternatively, our observation could be explained by an extrinsic origin (infection during pregnancy, drugs, environmental substances, etc), for which, however, we do not have the slightest proof. Further support for the presence of a rare autosomal recessive gene for unilateral pulmonary agenesis comes from the observation of Mardini and Nyhan,² who documented parental consanguinity in four patients; two patients had right upper and middle lobe agenesis and two presented with left sided pulmonary agenesis. All had associated congenital heart defects and three infants presented with abnormalities of the thumb. Podlech *et al*,⁴ who observed a family with one healthy and two affected children with bilateral agenesis of the lung, concluded that an autosomal recessive mode of inheritance could also be valid for bilateral pulmonary agenesis. Embryogenesis of human lung development is poorly understood, but in mice Fgf10 (fibroblast growth factor 10) is an important regulator of limb and lung formation.²⁴ Homozygous Fgf10 deficient mice die at birth owing to lack of lung development.

In conclusion, our report suggests an autosomal recessive gene or genes which cause pulmonary agenesis with optional heart, kidney, and other defects. In such cases, a 25% recurrence risk should be considered in genetic counselling.

We are grateful to Dr U Willi for interpretation of the chest x ray.

SIV FOKSTUEN
ALBERT SCHINZEL

Institut für Medizinische Genetik, Universität Zürich, Rämistrasse 74,
8001 Zürich, Switzerland

Correspondence to: Professor Schinzel, schinzel@medgen.unizh.ch

- 1 Spencer H. *Pathology of the lung*. 3rd ed. Oxford: Pergamon Press, 1977:71-114.
- 2 Mardini MK, Nyhan WL. Agenesis of the lung, report of four patients with unusual anomalies. *Chest* 1985;**87**:522-7.
- 3 Brimblecombe FSW. Pulmonary agenesis. *Br J Tuberc* 1951;**45**:7-14.
- 4 Podlech J, Richter J, Czygan P, Klein Pj, Müntefering H. Bilateral agenesis/aplasia of the lungs: report of a second case in the offspring of one woman. *Pediatr Pathol Lab Med* 1995;**15**:781-90.
- 5 Gilbert EF, Opitz JM. The pathology of some malformations and hereditary diseases of the respiratory tract. *Birth Defects* 1976;**XII**(6):239-70.
- 6 Oyamada A, Gasul BM, Holinger PH. Agenesis of the lung: report of a case, with a review of all previously reported cases. *Am J Dis Child* 1953;**85**:182.
- 7 Cunningham ML, Mann N. Pulmonary agenesis: a predictor of ipsilateral malformations. *Am J Med Genet* 1997;**70**:391-8.

- 8 Schaffer AJ, Rider RV. A note on the prognosis of pulmonary agenesis and hypoplasia according to the side affected. *J Thoracic Surg* 1957;33:379-82.
- 9 Heerup L. Case of absence of left lung. *Hospitalstidende* 1927;70:1165.
- 10 Knowles S, Thomas RM, Lindenbaum RH, Keeling JW, Winter RM. Pulmonary agenesis as part of the VACTERL sequence. *Arch Dis Child* 1988;63:723-6.
- 11 Downing GJ, Kilbride H. An interesting case presentation: pulmonary malformation associated with oculoauriculovertebral dysplasia. *J Perinatol* 1991;11:190-2.
- 12 Warkany J, Roth CB, Wilson JG. Multiple congenital malformations: a consideration of etiologic factors. *Pediatrics* 1948;1:462.
- 13 Say B, Carpenter NJ, Giacoia G, Jegathesan S. Agenesis of the lung associated with chromosome abnormality (46,XX,2p). *J Med Genet* 1980;17:477-90.
- 14 Schober PH, Müller WD, Behmel A, Fritsch G, Beitzke A. *Klin Padiatr* 1983;195:291-3.
- 15 Say B, Carpenter NJ. Pulmonary agenesis: importance of detailed cytogenetic studies. *Am J Med Genet* 1998;76:446.
- 16 Voorhess ML, Vahard T, Gardner LI. Trisomy 16-18 syndrome. *Lancet* 1962;ii:992.
- 17 Butler LJ, France NE, Russell A, Sinclair L. A chromosomal aberration associated with multiple congenital anomalies. *Lancet* 1962;i:1242.
- 18 Lehmann W. Missbildungen der Bronchien und der Lunge. In: Becker PE, ed. *Humangenetik*. Bd III/2. Stuttgart: Georg Thieme Verlag, 1972:204-9.
- 19 Finkelstein H. *Lehrbuch der Säuglingskrankheiten*. 3rd ed. Berlin: Springer, 1924.
- 20 Yount F. Agenesis of the right lung in each of identical twins. *Arizona Med* 1948;5:48.
- 21 Breton A, Dubois O. *Les malformations congénitales du poumon*. Paris: Doin, 1957.
- 22 Booth JB, Berry CL. Unilateral pulmonary agenesis. *Arch Dis Child* 1967;42:361-74.
- 23 Schinzel A, Smith DW, Miller JR. Monozygotic twinning and structural defects. *J Pediatr* 1979;95:921-30.
- 24 Sekine K, Ohuchi H, Fujiwara M, Yamasaki M, Yoshizawa T, Sato Y, Yagishita N, Matsui D, Koga Y, Itoh N, Kato S. Fgf10 is essential for limb and lung formation. *Nat Genet* 1999;21:138-41.

Correction

In the paper by Carroll *et al* in the February 1999 issue of the journal (*J Med Genet* 1999;36:94-6), the intronic polymorphism in *PTEN* was reported as IVS4+109InsACTAA. The correct sequence should be IVS4+109InsATCCTT. The authors would like to apologise for any confusion caused by this error.