

Short reports

Genitopatellar syndrome: a new condition comprising absent patellae, scrotal hypoplasia, renal anomalies, facial dysmorphism, and mental retardation

Valérie Cormier-Daire, Marie-Liesse Chauvet, Stanislas Lyonnet, Marie-Louise Briard, Arnold Munnich, Martine Le Merrer

Abstract

We report on the association of absent patellae, genital and renal anomalies, dysmorphic features, and mental retardation in seven children (six boys and one girl) belonging to five unrelated families. Flexion deformities of the knees and hips with club feet and absent patellae were consistently observed and scrotal hypoplasia and cryptorchidism were present in all boys (6/6). Dysmorphic features included a coarse face, a large nose with a high nasal bridge, and microcephaly. Other features included renal anomalies (multicystic kidneys or hydronephrosis, 7/7), agenesis of the corpus callosum (4/7), swallowing difficulties, micrognathia (4/7), and pulmonary hypoplasia (3/7). Bilateral hypoplasia of the ischia and brachydactyly were also consistently observed (5/5). In two out of seven cases, prenatal ultrasound detection of microcephaly and renal anomalies led to termination of the pregnancy at 27 weeks. Three children died during the first years of life and the remaining two who survived exhibit severe developmental delay. High resolution

cytogenetic studies performed on lymphocytes or fibroblasts or both were normal in all cases. Recurrence in two families suggests an autosomal recessive mode of inheritance. We propose that this unusual association, similar to that observed in a 4 year old boy by Goldblatt *et al*, represents a new syndrome distinct from previously reported hypoplastic patella syndromes.

(J Med Genet 2000;37:520–524)

Keywords: patella; genital anomalies; renal anomalies; mental retardation

Absence or hypoplasia of the patella is a rare congenital anomaly that is either isolated or occurs as part of a specific syndrome or chromosomal disorders such as trisomy 8. We report on seven cases of absent patella associated with scrotal hypoplasia, renal anomalies, facial dysmorphism, and mental retardation. Reviewing other syndromes with absent patella, we propose that this constellation of features is most similar to that observed by Goldblatt *et al*¹ and probably represents a

Department of
Genetics and INSERM
U-393, Hôpital Necker
Enfants Malades, 149
rue de Sèvres, 75743
Paris Cedex 15, France
V Cormier-Daire
M-L Chauvet
S Lyonnet
M-L Briard
A Munnich
M Le Merrer

Correspondence to:
Dr Le Merrer,
lemerrer@necker.fr

Revised version received
6 January 2000
Accepted for publication
31 January 2000

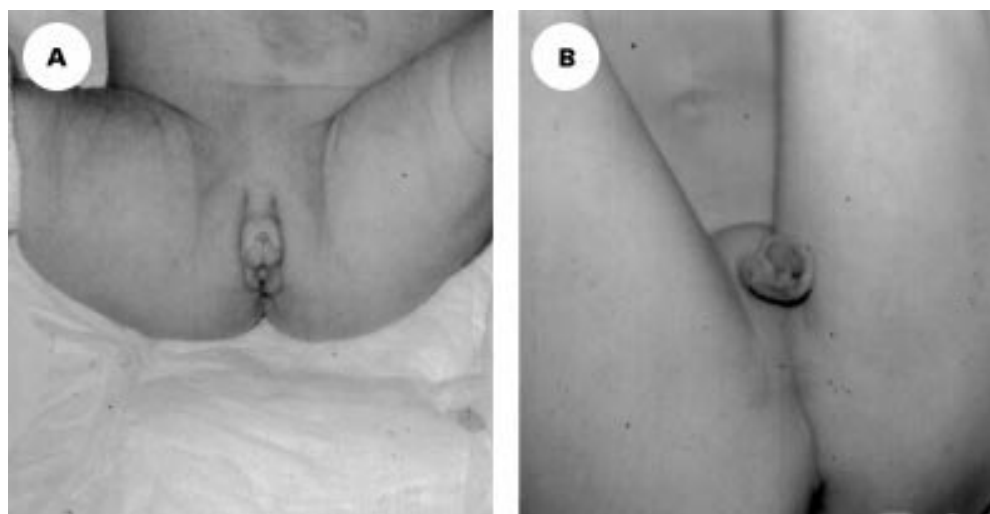


Figure 1 Genital anomalies. (A) Case 1: note hypertrophy of the clitoris and labia minora. (B) Case 3: note scrotal hypoplasia and cryptorchidism.

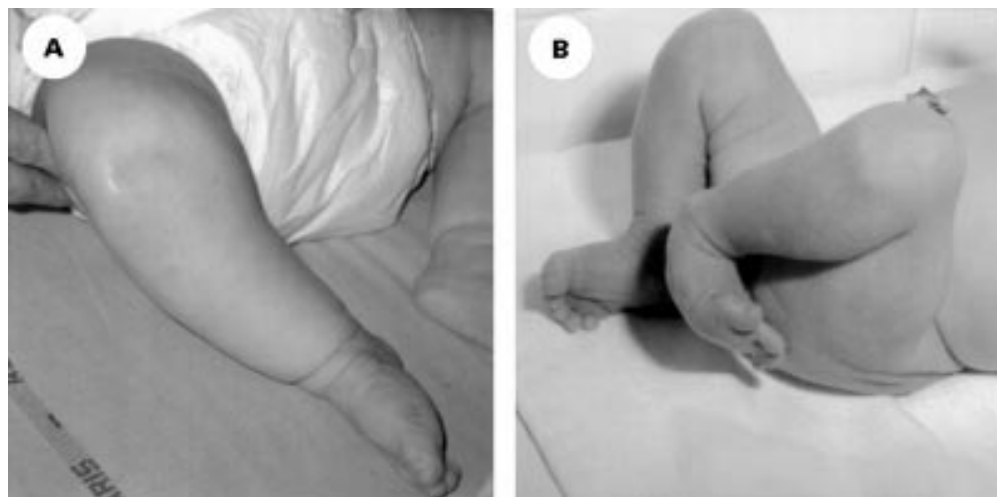


Figure 2 Limb anomalies: (A) case 1, (B) case 2. Note the skin dimple suggestive of absent patella, fixed flexion deformities of the knees and hips, and club feet.

novel entity, which we suggest calling the genitopatellar syndrome.

Case reports

FAMILY 1 (CASE 1)

A girl was born at term to unrelated, healthy parents after a normal pregnancy and delivery. Birth parameters were weight 3000 g, length 49 cm, and OFC 30 cm. Physical examination showed flexion deformities of the hips and knees, club feet, clitoral hypertrophy, and dysmorphic features, including a coarse face and a large and broad nose (figs 1A, 2A, and 3A). Hypotonia, swallowing difficulties related to laryngomalacia, and respiratory difficulties were also present. X ray examination showed hip dislocation with hypoplasia of the ischia

and iliac bones (fig 4). Cerebral imaging showed agenesis of the corpus callosum and renal ultrasound showed hydronephrosis. Chromosome analysis in blood lymphocytes was normal. Severe microcephaly (<-4 SD), swallowing difficulties, and flexion deformities persisted. Absent patella, which was clinically suspected, was confirmed during surgery performed for severe flexion deformity of the knee. Development was also severely delayed with no speech and no walking at 3 years of age. She died at this age of apnoea. Necropsy was not performed.

FAMILY 2 (CASE 2)

A boy was born at 38 weeks of gestation to unrelated, healthy parents with normal length and weight parameters but small OFC (32 cm). Hydramnios was noticed at the end of the pregnancy. At birth, he presented with dislocation of the hips, flexion deformities of the knees with a skin dimple suggestive of absent patella,

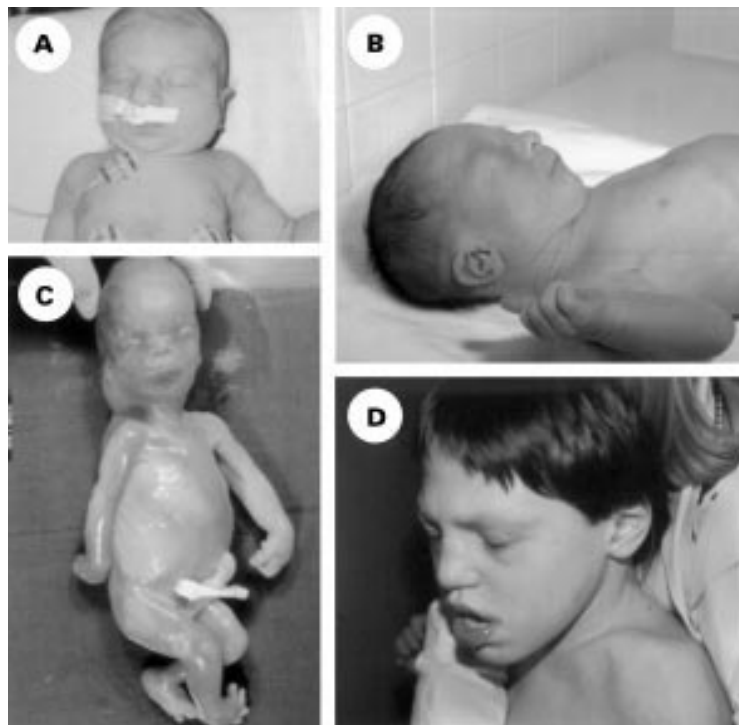


Figure 3 Dysmorphic features: (A) case 1, (B) case 2, (C) case 7, (D) case 3. Note coarse face, large and broad nose, high nasal bridge, and micrognathia. (Photographs reproduced with permission.)

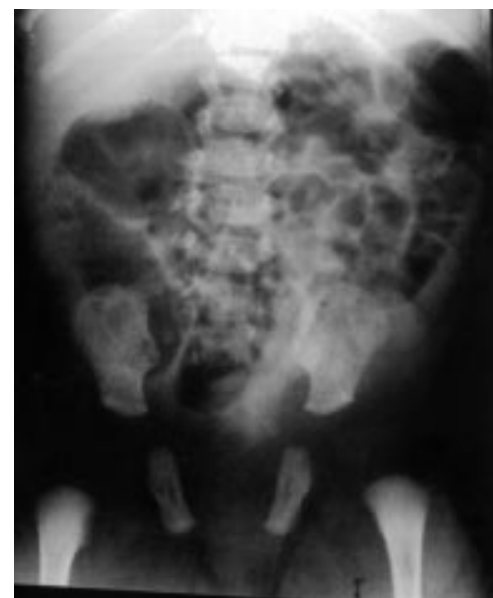

Figure 4 X ray manifestations in case 1 at birth. Note hip dislocation with bilateral hypoplasia of the ischia and inferior pubic rami (C).

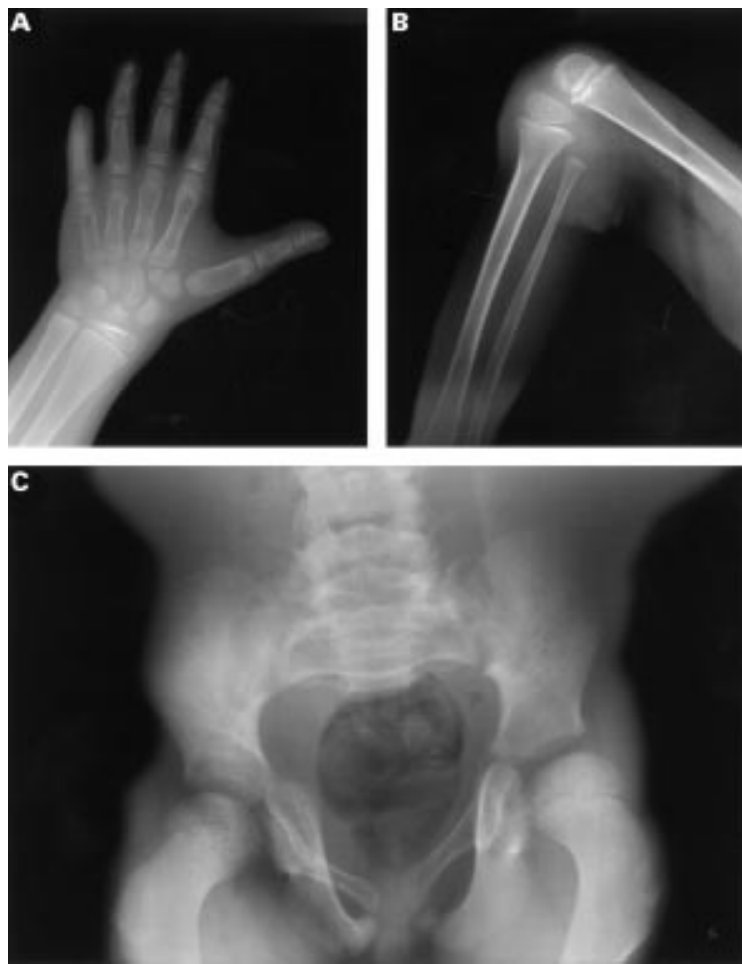


Figure 5 X ray manifestations in case 3 at 7 years of age. Note brachydactyly with short phalanges (A), absent patella (B), and hip dislocation with bilateral hypoplasia of the ischia and inferior pubic rami (C).

and club feet (fig 2B). Other features included scrotal hypoplasia with cryptorchidism, dysmorphic features (coarse face, broad nose, micrognathia; fig 3B), and respiratory distress. Renal ultrasound showed hydronephrosis and *x* rays showed hip dislocation with hypoplasia of the ischia and brachydactyly. He died on day 15 of apnoea. Necropsy showed multicystic kidneys, agenesis of the corpus callosum, and pulmonary hypoplasia. High resolution cytogenetic studies performed on lymphocytes were normal.

FAMILY 3 (CASES 3 AND 4)

A boy was born at term to unrelated parents after a normal pregnancy and delivery with normal birth parameters except for the OFC (31 cm). He presented with flexion deformities of the hips, knees, and feet, dysmorphic features, and genital anomalies (scrotal hypoplasia and cryptorchidism; fig 1B). Renal ultrasound showed hydronephrosis but cerebral imaging, electromyographic studies, and chromosome analysis in lymphocytes were normal. Severe microcephaly (<-3 SD) and dysmorphic features (fig 3D) persisted and he developed severe psychomotor retardation, with no speech or walking at 10 years and abnormal behaviour. Physiotherapy markedly reduced the flexion deformities. *X* rays at 7

years showed absent patella, brachydactyly, and hypoplasia of the ischia and inferior pubic rami (fig 5).

In the next pregnancy, ultrasound survey at 21 weeks showed ureterohydronephrosis, scrotal hypoplasia, and microcephaly. Chromosome analysis in amniotic cells was normal; The pregnancy was terminated at 27 weeks and necropsy showed dysmorphic features, scrotal hypoplasia, flexion deformities of the hips and knees, club feet, agenesis of the corpus callosum, pulmonary hypoplasia, and multicystic kidneys.

FAMILY 4 (CASES 5 AND 6)

A boy was born at term to unrelated, healthy parents with normal birth and weight parameters but small OFC (32 cm). Hydramnios was noticed at the end of the pregnancy. He presented with hip dislocation, flexion deformities of the knees, and club feet. Dysmorphic features included a coarse face, broad nose, and micrognathia, a skin dimple suggestive of absent patella, and scrotal hypoplasia with cryptorchidism. Hypotonia and swallowing difficulties were also present. Renal ultrasound showed hydronephrosis. Chromosome analysis in lymphocytes was normal. Microcephaly (<-3 SD), contrasting with normal birth and weight parameters, and respiratory insufficiency persisted and he died suddenly at 6 months of age. Necropsy was not performed.

In the next pregnancy, ultrasound survey was considered to be normal. A boy was born at term with normal parameters (birth weight 3000 g, length 52 cm). Flexion deformities of the hips, knees, and feet were noticed at birth together with dysmorphic features and genital anomalies. Renal ultrasound showed ureterohydronephrosis and cerebral imaging, electromyographic studies, and chromosome analysis (in lymphocytes and fibroblasts) were normal. The flexion deformities markedly improved with physiotherapy but he exhibits severe developmental delay with no speech or walking at 12 years and severe microcephaly (-3 SD). *X* rays showed hip dislocation with hypoplasia of the ischia, absent patella, and brachydactyly.

FAMILY 5 (CASE 7)

The first pregnancy of healthy, unrelated parents was terminated at 28 weeks of gestation because of the discovery of kidney anomalies and microcephaly at 24 weeks. Amniotic cell karyotype was normal (46,XY). Physical examination showed dysmorphic features (fig 3C), scrotal hypoplasia, and flexion deformities of the hips, knees, and feet. Necropsy showed agenesis of the corpus callosum, pulmonary hypoplasia, and multicystic kidneys.

Discussion

The seven children reported here (six boys and one girl) share common clinical findings, namely genital anomalies, facial dysmorphism, renal anomalies, absent patella, and severe mental retardation in the two survivors (table 1). Genital anomalies consisted of scrotal hypoplasia and cryptorchidism in the boys and clitoral hypertrophy in the girls. Dysmorphic

Table 1 Clinical presentation in seven patients with the genitopatellar syndrome

	Cases							Total
	1	2	3	4	5	6	7	
Family history	-	-	+	Case 3 brother Kidney anomalies Microcephaly at 21 wk	+	Case 5 brother	-	2/7
Prenatal ultrasound	-	-	+	Kidney anomalies	-	-	-	3/7
Karyotype	46,XX	46,XY	46,XY	46,XY	46,XY	46,XY	46,XY	2/7
Absent patella	+	+	+	+	+	+	+	6M/1F
Flexion deformities	+	+	+	+	+	+	+	7/7
Hips	+	+	+	+	+	+	+	7/7
Knees	+	+	+	+	+	+	+	7/7
Club feet	+	+	+	+	+	+	+	7/7
Genital anomalies	+	-	-	-	-	-	-	7/7
Clitoral hypertrophy	-	+	+	+	+	+	+	7/7
Scrotal hypoplasia	-	+	+	+	+	+	+	7/7
Cryptorchidism	-	+	+	+	+	+	+	7/7
Renal anomalies	Hydronephrosis	Hydronephrosis	Hydronephrosis	Hydronephrosis	Hydronephrosis	Ureterohydronephrosis	Multicystic kidneys Hydronephrosis	7/7
Dysmorphic features	+	+	+	+	+	+	+	7/7
Coarse face	+	+	+	+	+	+	+	
Broad nose	+	+	+	+	+	+	+	
Micrognathia	-	+	-	+	+	+	+	
Hypotonia	+	+	+	+	+	+	+	5/5
Microcephaly	+	+	+	+	+	+	+	7/7
Agenesis of corpus callosum	+	+	+	+	?	-	+	4/7
Pulmonary hypoplasia	?	+	-	+	?	-	+	3/7
Respiratory distress	+	+	-	+	+	-	+	3/5
Outcome	Death 3 y Apnoea	Death (day 15) Apnoea	10 y Not walking No speech	Pregnancy terminated at 27 weeks' gestation	"Sudden" death (6 mth)	12 y Not walking No speech	Pregnancy terminated at 28 weeks' gestation	Death 5/7

features included a coarse face, large and broad nose with a high nasal bridge, micrognathia, and microcephaly. Renal anomalies were also consistently observed including multicystic kidneys or ureterohydronephrosis and were detected prenatally in three patients. Absence of the patella was clinically suspected in all cases and radiographically confirmed in the two older boys who were over 6 years. For the other cases, it was impossible to confirm, as the normal ranges for ossification of the patella are 2.5–6 years in boys and 17 months–4 years in girls and ultrasound scans were not available. The other skeletal manifestations were hip anomalies with hypoplasia of the ischia and pubic rami and short hands. Other anomalies included agenesis of the corpus callosum (4/7) and pulmonary hypoplasia (3/7). In two out of seven cases, the pregnancy was terminated at 27 weeks of pregnancy because of the association of renal anomalies and microcephaly. In three out of seven cases, the condition was fatal during the first years of life owing to sudden death or respiratory distress. In the two survivors, severe developmental delay and severe microcephaly persisted.

This series of patients is composed of six boys and one girl belonging to five unrelated families (three French, two Portuguese). Why the majority of affected subjects were males is open to question and could be ascribed to the easier recognition of genital anomalies in males. The trait is probably an autosomal recessive one, as boys and girls were affected and sib recurrence was observed in two families. Consanguinity was never mentioned in any family.

A similar association has previously been reported by Goldblatt *et al*¹ in a 4 year old boy who presented with hypoplastic patellae, mental retardation, scrotal hypoplasia, skeletal deformities, renal anomalies (fused renal ectopia), flattened nasal bridge, but also short stature, which was not observed in any of our patients. These features are also seen in the mosaic trisomy 8 syndrome, but the distinctive palmar and plantar skin changes characteristic of the trisomy 8 phenotype were absent² and the karyotypes were consistently normal in our patients. Absent patella also occurs as a part of various bone dysplasias but these conditions do not exhibit extraskelatal manifestations.^{3–4} Other syndromes of patellar hypoplasia with genital and renal anomalies have been reported, including one described by Braegger *et al*.⁵ This condition, however, includes an immune deficiency, which was not observed in any of our patients. Rudimentary patellae and genital anomalies are also observed in penoscrotal transposition and diphallia with patella aplasia,⁶ and in the faciogenitopopliteal syndrome.⁷ Similarly, absent patellae are observed in association with renal anomalies in the nail-patella syndrome,⁸ the RA-PADILINO syndrome,⁷ the syndrome of short stature, small ears, craniosynostosis, and skeletal anomalies described by Hurst *et al*,¹⁰ and in the Coffin-Siris syndrome.¹¹ It is worth noting, however, that, except for Coffin-Siris syndrome, mental retardation is not a

significant feature of these syndromes, but in Coffin-Siris syndrome there are numerous other changes that are not found in our patients.

We conclude therefore that this association of absent patellae, scrotal hypoplasia, facial dysmorphism, renal anomalies, and mental retardation represents a novel autosomal recessive syndrome. Additional similar observations may help to confirm and further delineate the clinical profile of this severe condition.

We thank Ravi Savarirayan for his helpful comments.

- 1 Goldblatt J, Wallis C, Zieff S. A syndrome of hypoplastic patellae, mental retardation, skeletal and genitourinary anomalies with normal chromosomes. *Dysmorphol Clin Genet* 1988;2:91-3.
- 2 Nakagome Y, Warkany J, Rubinstein JH. Mental retardation, absence of patellae, and other malformations with chromosomal mosaicism. A follow-up report. *J Pediatr* 1968;72:695-7.
- 3 Azouz EM, Kozlowski E. Small patella syndrome: a bone dysplasia to recognize and differentiate from the nail-patella syndrome. *Pediatr Radiol* 1997;27:432-5.
- 4 Habboub HK, Thneibat WA. Ischio-pubic-patellar hypoplasia: is it a new syndrome. *Pediatr Radiol* 1997;27:430-1.
- 5 Braegger C, Bottani A, Hallé F, Giedion A, Leumann E, Seger R, Willi U, Schinzel A. Unknown syndrome: ischiadic hypoplasia, renal dysfunction, immunodeficiency and a pattern of minor congenital anomalies. *J Med Genet* 1991;28:56-9.
- 6 Dodat H, Rosenberg D, James-Pangaud I. Association familiale d'une transposition pénoscrotale et diphallia (pénis double) à une aplasie rotulienne. *Arch Fr Pediatr* 1995;2:241-4.
- 7 Escobar V, Weaver D. The facio-genito-popliteal syndrome. *Birth Defects* 1978;XIV:185-92.
- 8 Looij B Jr, Te Slaa RL. Genetic counselling in hereditary osteo-onychodysplasia (HOOD, nail patella syndrome). *J Med Genet* 1988;25:682-6.
- 9 Kääriäinen H, Ryöppy S, Norio R. RAPADILINO syndrome with radial and patellar aplasia/hypoplasia as main manifestations. *Am J Med Genet* 1989;33:346-51.
- 10 Hurst JA, Winter RM, Baraitser D. Distinctive syndrome of short stature, craniosynostosis, skeletal anomalies and malformed ears. *Am J Med Genet* 1988;29:107-15.
- 11 Coffin GS, Siris E. Mental retardation with absent fifth fingernail and terminal phalanx. *Am J Dis Child* 1970;119:433-9.