

Absent pituitary gland and hypoplasia of the cerebellar vermis associated with partial ophthalmoplegia and postaxial polydactyly: a variant of orofacioidigital syndrome VI or a new syndrome?

L I Al-Gazali, L Sztriha, J Punnose, W Shather, M Nork

Abstract

We report two sibs with features overlapping those of orofacioidigital syndrome type VI (Varadi syndrome). Both presented at birth with oculomotor abnormalities, dysmorphic facial features, and dysgenesis of the cerebellar vermis. There were minimal oral manifestations (high arched palate) in both of them and one had postaxial polydactyly of both hands and one foot. In addition, there was evidence of aplasia of the pituitary gland on MRI scan in both of them with evidence of hypopituitarism. Both responded well to hormone replacement therapy with improvement in their linear growth and mental ability. These cases may represent a new autosomal recessive midline defect syndrome with features overlapping OFDS VI. Alternatively the features in these children could represent variability within OFDS VI.

(*J Med Genet* 1999;36:161-166)

Keywords: vermis dysgenesis; absent pituitary; orofacioidigital syndrome VI

The orofacioidigital syndromes (OFDS) are a group of heterogeneous genetic disorders having in common facial anomalies, oral abnormalities, and digital malformations. Nine types have been identified.¹ However, in many instances the exact type of OFDS cannot be ascertained. Furthermore, overlap with other midline defect syndromes has led to problems in diagnosing these disorders.¹

OFD VI is an autosomal recessive syndrome characterised by the presence of cerebellar anomalies, mainly vermis aplasia/hypoplasia in addition to the oral, facial, and digital anomalies.²

We report two sibs with features overlapping those of OFD VI who, in addition, had aplasia of the pituitary gland with evidence of hypopituitarism. Both responded well to hormone replacement therapy with improvement in linear growth and mental ability. We suggest that the cases reported here could either represent variability within OFDS VI or a new midline defect syndrome overlapping OFDS VI.

Case reports

The parents are unrelated Egyptians. The mother is 35 years of age and the father 40 years. Both are normal. The second child of the couple was born by LSCS in Egypt and was said to have had dysmorphic features which included antimongoloid slant of the palpebral fissures, unilateral choanal atresia with absent nasal septum, low set ears, bilateral undescended testes, and a small phallus. The baby died at 36 hours of age of undetermined cause. No further information is available.

CASE 1

Case 1, a female, the first child of the couple, was the product of a pregnancy complicated by severe hyperemesis which required treatment, the nature of which is not known. Delivery was by LSCS at 42 weeks' gestation because of ineffective uterine contractions. The baby had transient cyanosis and required suction and oxygen. No neonatal measurements are available. The

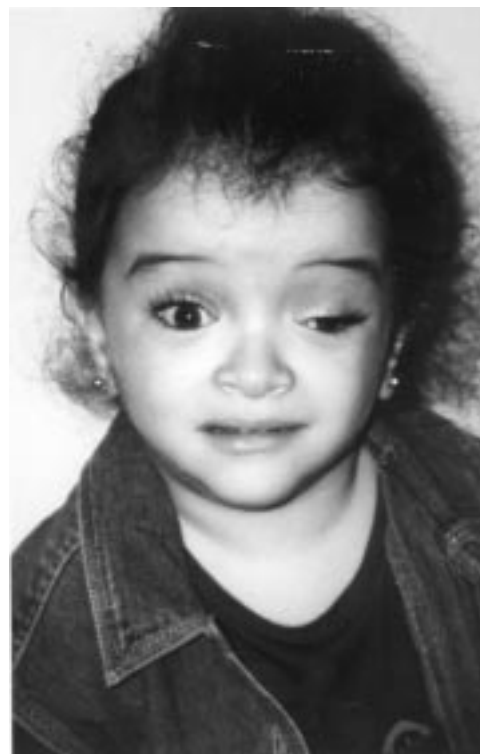

Figure 1 Facial appearance of case 1. Note ptosis of the left eye, epicanthus inversus, and depressed nasal bridge.

Department of
Paediatrics, Faculty of
Medicine and Health
Sciences, PO Box
17666, UAE University,
Al-Ain, United Arab
Emirates
L I Al-Gazali
L Sztriha

Department of
Medicine, Al-Ain
Hospital, Al-Ain,
United Arab Emirates
J Punnose

Department of
Neurosurgery,
Fujairah Hospital,
Fujairah, United Arab
Emirates
W Shather

Department of
Radiology, Tawam
Hospital, Al-Ain,
United Arab Emirates
M Nork

Correspondence to:
Dr Al-Gazali.

Received 26 March 1998
Revised version accepted for
publication 30 June 1998

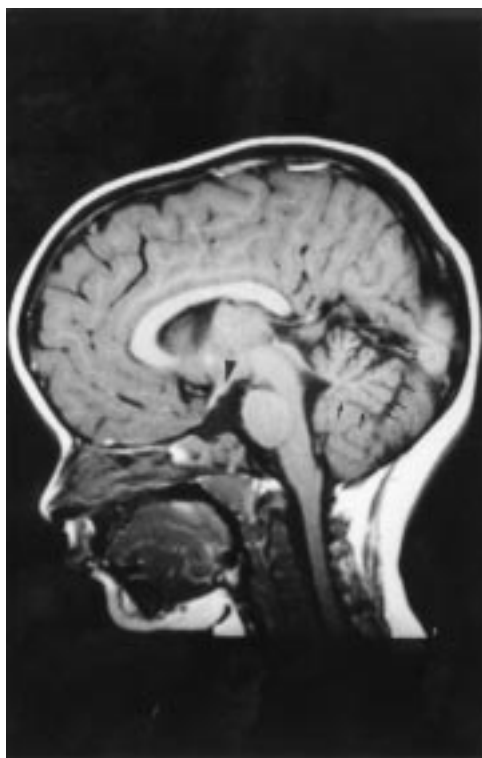

Figure 2 Case 1. Sagittal T1 weighted (400/14, TR/TE) MR image showing hypoplasia of the vermis (arrows); the posterior lobe is mainly affected. The sella is hypoplastic and empty. Ectopic posterior pituitary can be seen connected to the rudimentary infundibulum (arrowhead). The pituitary stalk is not visible.

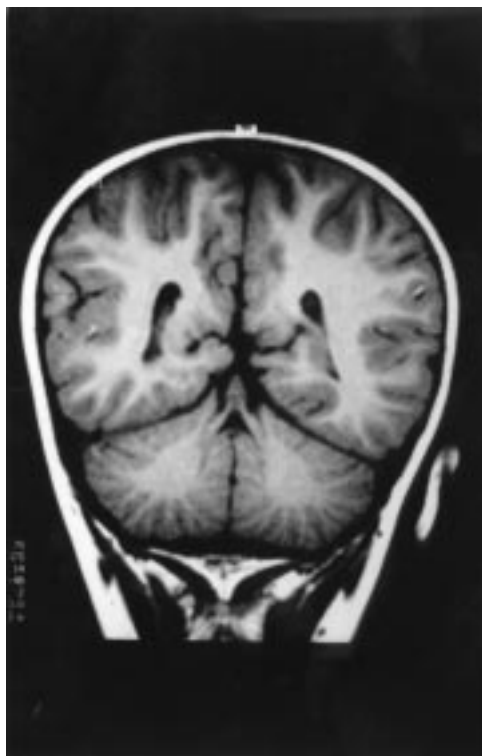


Figure 3 Case 1. Coronal T1 weighted (673/14, TR/TE) MR image. The cerebellar hemispheres are separated by a cleft because the posterior lobe of the vermis is absent. The anterior lobe is hypoplastic and the superior cerebellar peduncles are clearly visible.

neonatal period was uneventful apart from mild physiological jaundice. In the first few days of life she was noted to have ptosis on the left side with lateral deviation of the left eye. This was diagnosed as third nerve palsy. CT scan of the brain at 2 months of age was reported to be normal. Her early developmental milestones were delayed. She also had delayed teething with the first tooth appearing at 2 years. She was assessed by us at the age of 3 years 5 months. Her weight was 12.3 kg (10th centile), height 82 cm (<3rd centile), and head circumference 50.5 cm (>25th centile). She had the following dysmorphic features: a prominent and high forehead, deep set eyes, upward slanting palpebral fissures, and epicanthus inversus (fig 1).

Ptosis was observed on the left side with outward deviation of the left eye. She was not able to rotate the eye upwards, downwards, or inwards. The left pupil was small and unresponsive to light. The movements of the right eyeball were free in all directions and there was no ptosis on this side. The right pupil was in midposition and unresponsive to light. It was not possible to assess the accommodation and ciliospinal reflex in a proper way because of lack of any cooperation. Muscle tone was normal and the deep tendon reflexes were brisk. Movements were clumsy. At 4 years of age she was functioning at a 2 year level.

Chromosome analysis, skeletal survey, and renal ultrasound were normal. Amino acid chromatography, organic acid screening, long chain fatty acid and phytanic acid, serum lactate, ammonia, electrolytes, and creatinine, and serum and urine osmolality were normal.

MR imaging studies were performed with a 1.5-T system (Magnetom, Siemens Medical Systems). Sagittal and T1 weighted (400/14, TR/TE), coronal T1 weighted (673/14, TR/TE), and transaxial T2 weighted (2850/22, 60, 120, TR/TE) spin echo images were obtained. The cerebral cortex and lateral and third ventricles were normal. The genu and body of the corpus callosum were normal, while the rostrum was hypoplastic and the splenium was absent. Myelination was delayed mainly in the centrum semiovale and periventricular areas. The arcuate fibres, internal capsules, and optic radiation showed normal myelination.

The sella turcica was hypoplastic and empty and the posterior pituitary bright spot was absent from its normal location. An ectopic posterior pituitary was connected to the rudimentary infundibular region. The pituitary stalk was not visible (fig 2). The optic chiasm, olfactory sulci, and bulbs were normal. The colliculi superiores and inferiores, substantia nigra, and red nuclei were recognisable in the mesencephalon. The cerebellar vermis, mainly the posterior lobe, was hypoplastic. The central lobule, culmen, and declive were small but recognisable, but the other lobules of the posterior lobe were more severely deformed or absent (fig 2). The posterior fossa was mainly occupied by the cerebellar hemispheres. On coronal slices, the hemispheres were separated by a cleft because of the missing posterior lobe of the vermis (fig 3). On axial slices, the fourth ventricle roof was deformed. The superior

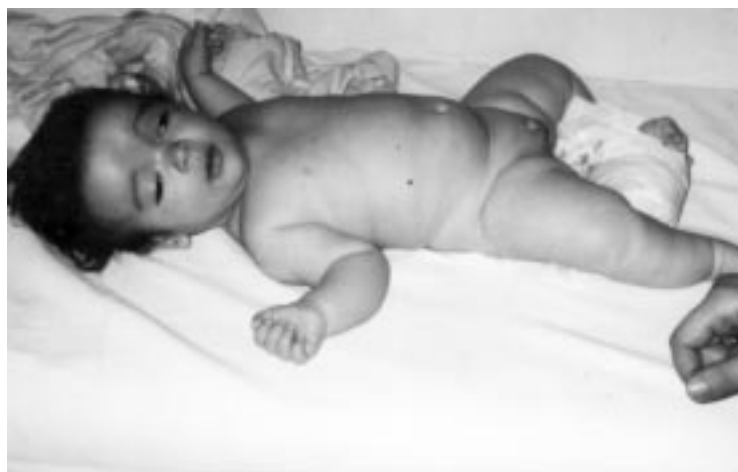

Figure 4 Appearance of case 2: note bilateral ptosis, depressed nasal bridge, broad nasal tip, micropenis, and bilateral undescended testes.

cerebellar peduncles were elongated and they appeared to course nearly perpendicular to the brain stem. The interpeduncular fossa was enlarged and deep at the pontomesencephalic junction and the CSF spaces appeared larger than normal around the mesencephalon.

Endocrine evaluation at 4 years showed serum cortisol level at 8 am 2.19 $\mu\text{g}/\text{dl}$ (NR 5-18), at 11 pm 1.52 $\mu\text{g}/\text{dl}$ (NR 2-13), FT_4 0.55 ng/ml (NR 0.71-1.85), TSH 5.18 mIU/ml (0.47-5.07), and serum insulin-like growth factor-1 (IGF-1) <2 ng/ml (NR 44-117). Serum growth hormone at 11 pm (one hour

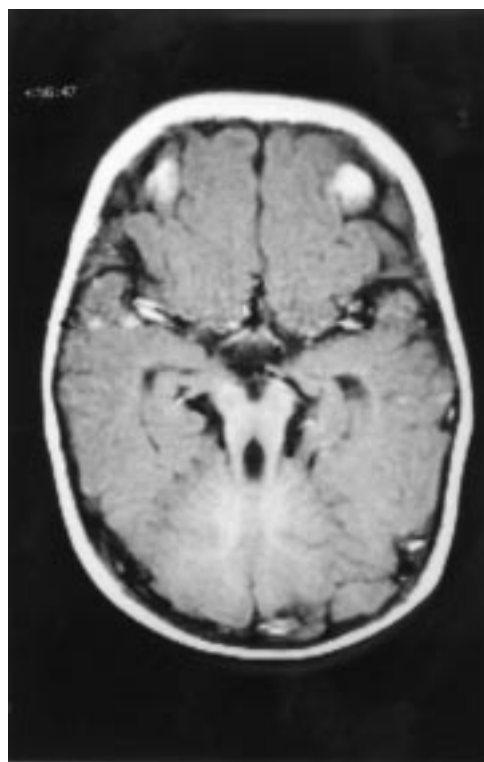


Figure 5 Case 2. Transaxial T1 weighted (400/14, TR/TE) MR image shows the superior cerebellar peduncles which are visible owing to hypoplasia of the vermis. Note the deep interpeduncular fossa. The cerebral and superior cerebellar peduncles resemble a molar tooth. Isointensity of the cortical grey and subcortical white matter can be observed, which is a normal finding on T1 weighted images at the age of 5 months when the MRI was done.

after onset of sleep) was 0.3 ng/ml. The maximum serum growth hormone response following oral clonidine (50 μg) and propranolol (10 mg) primed exercise was <0.1 ng/ml and 0.1 ng/ml respectively (normal response >10 ng/ml). Considering the limitations in interpretation of basal serum LH, FSH, oestradiol levels, and LHRH tests at this age, the evaluation of gonadotrophic activity was deferred until the time of puberty.

The above results are compatible with panhypopituitarism. She was started on hormone replacement therapy with oral hydrocortisone, L-thyroxine, and subcutaneous recombinant growth hormone. This was followed by improvement of her general well being and mental ability and increase in her linear growth.

CASE 2

Case 2, the brother of case 1, was the product of a twin pregnancy complicated by hyperemesis for which antiemetic medication was required. Delivery was by LSCS at 37 weeks' gestation. The first twin weighed 3000 g and looked normal at birth but died suddenly at 1 day of age. The second twin (case 2) weighed 2600 g and had multiple congenital abnormalities. These included bilateral ptosis and postaxial polydactyly of both hands and the left foot. The phallus appeared very small and there were bilateral undescended testes. He had asymptomatic hypoglycaemia. His early developmental milestones were delayed. He was assessed by us at 5 months of age. His weight was 6.02 kg (10th centile), length 58.5 cm (<3rd centile), and head circumference 43.5 cm (50th centile). He had a prominent forehead with deep set eyes and downward slanting palpebral fissures. He had bilateral ptosis with lateral deviation of the eyeballs and no medial or vertical eye movements. Both pupils were small and unresponsive to light. The nasal bridge was depressed and the nasal tip was wide. There were a high arched palate and postaxial polydactyly of the left foot (fig 4). The extra digits on both hands had been removed. There was micropenis and bilateral undescended testes (fig 4). Muscle power and tone were slightly reduced and the deep tendon reflexes were brisk. He had delayed motor development but his social responses were normal. Chromosome analysis and renal ultrasound were normal. Amino acid chromatography, organic acid screening, long chain fatty acid and phytanic acid, serum lactate and ammonia, and serum electrolytes were normal. Skeletal survey was normal apart from postaxial polydactyly of the left foot.

The brain MR imaging studies were performed with a 1.5-T system (Magnetom, Siemens Medical Systems). Sagittal and T1 weighted (400/14, TR/TE), coronal T1 weighted (673/14, TR/TE), and transaxial T2 weighted (2850/22, 60, 120, TR/TE) spin echo images were obtained. The midline malformations were similar to those seen in case 1. Hypoplasia of the corpus callosum and cerebellar vermis, elongated superior cerebellar peduncles with deep interpeduncular fossa at

the pontomesencephalic junction (fig 5), prominent CSF spaces around the mesencephalon, and hypoplasia of the empty sella turcica were the main abnormalities. A bright spot, suggestive of an ectopic posterior pituitary, was not found and the pituitary stalk was absent.

Owing to lack of cooperation, a complete pituitary functional evaluation could not be done. The serum basal hormone estimation at 1 year showed FT₄ 0.79 ng/ml (NR 0.71-1.85), TSH 2.06 mIU/ml (0.47-5.07), cortisol at 8 am 6.82 mg/dl (5-18), and insulin-like growth factor-1 (IGF-1) <2.1 ng/ml (6.1-131). Considering the short stature, micropenis, the radiological evidence of pituitary hypoplasia, and low normal basal hormones, replacement therapy with hydrocortisone, L-thyroxine, and subcutaneous recombinant growth hormone was started. This was followed by improvement of his general well being and mental ability and increase in linear growth.

Discussion

The children in this report have the following abnormalities: a prominent and high forehead, deep set eyes, ocular motor abnormalities, depressed nasal bridge with a broad nasal tip, and a high arched palate. Postaxial polydactyly of both hands and one foot was present in one of them. In addition, both were short for age, had dysgenesis of the cerebellar vermis, and absent pituitary gland on MRI. The boy had micropenis and bilateral undescended testes. One other child of the couple had choanal atresia, a small phallus, and undescended testes and died suddenly, probably of hypoglycaemia. The twin of the second case who appeared normal at birth died suddenly at 1 day of age, probably of hypoglycaemia.

The oculomotor abnormalities in our patients were suggestive of third nerve paralysis, which was unilateral in case 1 and bilateral in case 2. The pupils were unresponsive to light with anisocoria in case 1 and bilateral equally small pupils in case 2. These pupillary abnormalities showed similarities with the Argill Robertson pupil, which has been observed in various pathological processes of the mesencephalon in addition to syphilis.³ The deep interpeduncular fossa at the pontomesencephalic junction with some widening of the CSF spaces around the mesencephalon were suggestive of volume reduction of the midbrain in our patients. Although other abnormalities in the structure of the mesencephalon were not shown by MRI, it is reasonable to hypothesise that dysplasia of the mesencephalon with involvement of the third nerve nuclei and other periaqueductal structures might be responsible for the oculomotor and pupillary abnormalities. The light reflex fibres from the pretectal nuclei, which supply both Edinger-Westphal nuclei, run close to the sympathetic pupillodilator fibres in the periaqueductal region at the level of the superior quadrigeminal bodies.³ Dysplasia of this region might interrupt the pathway which goes from the pretectal area to

the Edinger-Westphal nucleus and the adjacent pathway of the sympathetic pupillodilator fibres that descend from the hypothalamus to the upper thoracic spinal cord, and then through the cervical sympathetic chain to the iris.³ Dysfunction of the former pathway may have resulted in unresponsiveness to light and damage to the latter could be responsible for the small pupils in our patients.

Severe hypoplasia of the sella turcica, empty sella, absence of the pituitary stalk, and posterior pituitary ectopia are common findings in children with congenital idiopathic growth hormone deficiency and multiple pituitary hormone deficiency.^{4,5} The pituitary abnormalities have been attributed to a failure of the normal inductive events in the mediobasal forebrain.⁴ Large midline cerebral malformations, such as holoprosencephaly, corpus callosum dysgenesis, and septo-optic dysplasia, can be associated with hypothalamo-hypophysal deficiency.⁴ However, in our cases the mediobasal developmental defect in the forebrain was associated with midline malformations in the more caudal structures, such as the midbrain and hindbrain, in addition to the limb deformities and facial anomalies.

In view of the facial anomalies in our cases, together with the presence of hypoplasia of the vermis and postaxial polydactyly in one child, we considered the diagnosis of OFD VI syndrome. This syndrome was originally described by Varadi *et al*⁶ in seven children in an inbred gypsy community in Hungary. Muenke *et al*⁶ further delineated this syndrome in three typical cases and reviewed the previously reported cases. They identified cerebellar dysgenesis and central polydactyly of the hands as important diagnostic manifestations of this syndrome. Both of our cases lacked central polydactyly. In addition, the oral manifestations in our cases were minimal. However, there are published reports of cases with atypical or variable manifestations of OFD VI. In some of these reports a new syndrome has been proposed, and in others overlap with other OFD syndromes or syndromes with midline defects lead to difficulties and confusion in diagnosing these disorders. It is still unclear if these syndromes represent variability within OFD VI or heterogeneity in the group of OFD syndromes. Chitayat *et al*⁷ reported a brother and sister with postaxial polydactyly of the hands and feet associated with cerebellar hypoplasia. The boy also had micropenis. Both had ptosis with strabismus and rotatory and seesaw nystagmus. Oral manifestations included high arched palate and bifid tongue. The authors rejected the diagnosis of OFD VI on the basis that their patients had mesomelic shortening of the limbs and lacked preaxial polydactyly of the feet and hypodontia. Stephan *et al*⁸ reported a child with features of OFD VI. However, oral manifestations were not typical. These included broad and shallow vault, prominent midline gingival frenula, and supernumerary maxillary incisors. There was in addition a left orbital cyst and bilateral optic nerve hypoplasia. Piantanida *et al*⁹ reported two sibs with features overlapping OFD VI. These included

hypertelorism, strabismus, epicanthic folds, ptosis, agenesis of the vermis, postaxial polydactyly, and duplication of the hallux in one them. Both had minimal oral manifestations (one had a high arched palate and the second had, in addition, a broad alveolar ridge).

There are also published reports of cases with typical manifestations of OFD VI but with a normal cerebellum. Cleper *et al*¹⁰ reported two first cousin boys with cleft palate, wide alveolar ridge, and buccal frenula. One had central polydactyly and the other camptodactyly with interdigital webbing. There was micropenis in both of them. Both lacked cerebellar abnormalities but one had agenesis of the callosal splenium. The authors suggested that neither cerebellar anomalies nor Y shaped metacarpals or polydactyly are essential for the diagnosis of OFD VI. Similarly, Camera *et al*¹¹ reported a fetus with a broad nasal tip, mild midline cleft of the upper lip, tongue hamartoma, central notch of the mandibular alveolar ridge, central polydactyly with a forked third metacarpal, and cardiac defect. There were no cerebellar anomalies. Shashi *et al*¹² reported two sibs with postaxial polydactyly of the hands and feet with bifid great toe and syndactyly, median cleft lip and palate with cleft tongue, and micropenis. One had bilateral cataract and oculomotor nerve palsy. Both had a normal cerebellum but had, in addition, diffuse cerebral atrophy and absent pituitary gland with ectopic location of the neurohypophysis. The authors suggested that their cases might represent a new type of OFDS or variability within the described OFDS, particularly II and VI. They also pointed out the similarities between their patients and the Pallister-Hall syndrome (PH), but rejected that diagnosis in view of the absence of hypothalamic hamartoma. Absence of the pituitary gland associated with a hypothalamic hamartoma in a typical case of OFD VI has also been reported.⁶ Furthermore, there is a report of a hypothalamic hamartoma with a normal pituitary in a patient with features of OFD VI.⁸ Congenital hypothalamic hamartoma associated with hypoplasia of the pituitary is a consistent finding in the Pallister-Hall syndrome. Overlap between the OFD VI and PH syndrome has already been pointed out.^{13 14} It has been suggested that the similarities between these syndromes may represent defects in the development of the "midline field" common to both syndromes.¹² The diagnosis of PH syndrome was ruled out in our cases since they lacked all the major manifestations of this syndrome.

In addition to the absence of the pituitary gland on MRI in both of our cases, the serum hormone profile confirmed hypopituitarism in case 1 and showed borderline deficiency of pituitary hormones in case 2 (the confirmatory dynamic studies were not done). However, the good therapeutic response to hormone replacement therapy indicates hypopituitarism in both children. Although short stature was observed in most of the previously reported children with features of OFD VI, proper endocrine studies and pituitary imaging were

not carried out in them. Therefore, it would be important that children with features suggestive of OFD VI are investigated for this possibility in order that appropriate treatment is given. This is important since early replacement therapy might improve the performance of such children, as was reported in our cases.

Despite the similarities between the clinical findings in our cases and OFD VI, a conclusive diagnosis of this syndrome cannot be made. It is possible that our cases represent a new midline defect syndrome which overlaps with OFDS VI. Until a molecular classification for the OFD syndromes becomes available, it might be better to keep such atypical cases separate. In this respect it is interesting to note that in the mouse the homeobox containing *Engrailed* gene (*En-1*) is specifically expressed across the midbrain-hindbrain junction, the ventral ectoderm of the limb buds, and in regions of the spinal cord.¹⁵ Mice homozygous for a mutation in this gene die within a day of birth and have multiple abnormalities. These include abnormally shaped forelimbs (postaxial digit and digit fusion) and absent cerebellum, colliculi, and third and fourth cranial nerves in the midbrain.¹⁵ The homologous human *EN-1* gene is expressed mainly in the cerebellar vermis and deep cerebellar nuclei of the midgestation human fetus.¹⁶ The DNA sequence is highly conserved between the mouse *En-1* and human *EN-1* genes and thus the genes could be functionally similar in the two species.¹⁷ It would therefore be fascinating to study this gene in our cases.

The authors would like to thank the family for their cooperation and Ashok Prasad for photographic work.

- 1 Toriello HV. Oral-facial-digital syndrome. *Clin Dysmorphol* 1992;2:95-105.
- 2 Varadi V, Szabo L, Papp Z. Syndrome of polydactyly, cleft lip/palate or lingual lump, and psychomotor retardation in endogamic gypsies. *J Med Genet* 1980;17:119-122.
- 3 Haerer, AF. *DeJong's neurologic examination*. 5th ed. Philadelphia: J B Lippincott, 1992:135-6.
- 4 Triulzi F, Scotti G, di Natale B, *et al*. Evidence of a congenital midline brain anomaly in pituitary dwarfs: a magnetic resonance imaging study in 101 patients. *Pediatrics* 1994;93:409-16.
- 5 Cacciari E, Zucchini S, Ambrosetto P, *et al*. Empty sella in children and adolescents with possible hypothalamic-pituitary disorders. *J Clin Endocrinol Metab* 1994;78:767-71.
- 6 Müenke M, McDonald DM, Cronister A, Stewart JM, Gorlin RJ, Zackai EH. Oral-facial-digital syndrome type VI (Varadi syndrome): further clinical delineation. *Am J Med Genet* 1990;35:360-9.
- 7 Chitayat D, Stalker HJ, Azouz M. Autosomal recessive oral-facial-digital syndrome with resemblance to OFD types II, III, IV and VI: a new OFD syndrome. *Am J Med Genet* 1992;44:567-72.
- 8 Stephan MJ, Brooks KL, Moore DC, Coll EJ, Goho C. Hypothalamic hamartoma in oral-facial-digital syndrome type VI (Varadi syndrome). *Am J Med Genet* 1994;51:131-6.
- 9 Piantanida M, Tiberti A, Plebani A, Martelli P, Danesino C. Cerebro-reno-digital syndrome in two sibs. *Am J Med Genet* 1993;47:420-2.
- 10 Cleper R, Kauschansky A, Varsano I, Frydman M. Varadi syndrome (OFDVI) or Opitz trigonocephaly syndrome: overlapping manifestation in two cousins. *Am J Med Genet* 1993;47:451-5.
- 11 Camera G, Marasini M, Pozzolo S, Camera A. Oral-facial-digital syndrome: report on a transitional type between the Mohr and Varadi syndrome in a fetus. *Am J Med Genet* 1994;53:196-8.
- 12 Shashi V, Clark P, Rogol AD, Wilson WG. Absent pituitary gland in two brothers with an oral-facial-digital syndrome resembling OFDII and VI: a new type of OFDS? *Am J Med Genet* 1995;57:22-6.
- 13 Müenke M, Ruchelli ED, Rorke LB, *et al*. On lumping and splitting: a fetus with clinical findings of the oral-facial-digital

- syndrome type VI. The hydrolethrus syndrome and the Pallister-Hall syndrome. *Am J Med Genet* 1991;41:548-56.
- 14 Hingorani SR, Pagon RA, Shepherd TH, Kapur RP. Twin fetuses with phenotypic features that overlap with three midline malformation complexes. *Am J Med Genet* 1991;41:230-5.
- 15 Wurst W, Auerbach AB, Joyner AL. Multiple developmental defects in *Engrailed-1* mutant mice: an early mid-hind brain deletion and patterning defects in forelimbs and sternum. *Development* 1994;120:2065-75.
- 16 Zec N, Rowitch DH, BitGood MJ, Kinney HC. Expression of the homeobox-containing genes *EN-1* and *EN-2* in human fetal midgestational medulla and cerebellum. *J Neuropathol Exp Neurol* 1997;56:236-42.
- 17 Logan C, Hanks MC, Noble-Topham S, Nallainathan D, Provart NJ, Joyner AL. Cloning and sequence comparison of the mouse, human and chicken *engrailed* genes reveal potential functional domains and regulatory regions. *Dev Genet* 1992;13:345-58.