

Proteinuria in a patient with the diaphragmatic hernia-hypertelorism-myopia-deafness syndrome: further evidence that the facio-oculo-acoustico-renal syndrome represents the same entity

Koenraad Devriendt, Lieve Standaert, Chris Van Hole, Hugo Devlieger, Jean-Pierre Fryns

Abstract

We present a male infant with hypertelorism, severe myopia and sensorineural deafness, diaphragmatic hernia, and proteinuria. This patient combines features of two distinct genetic conditions, the syndrome of diaphragmatic hernia, exomphalos, absent corpus callosum, hypertelorism, myopia, and sensorineural deafness (MIM 222448), and the facio-oculo-acoustico-renal syndrome (MIM 227290), which is characterised by similar anomalies, with the additional finding of proteinuria, but without diaphragmatic hernia. The present observations further suggest that these syndromes are the variable expression of a single autosomal recessive disorder.

(*J Med Genet* 1998;35:70-71)

Keywords: myopia; deafness; diaphragmatic hernia; autosomal recessive

Genetic syndromes usually have variable expression, both regarding the severity of certain features and the presence or absence of specific malformations. In the case of rare syndromes, without a diagnostic test, the full spectrum of the disorder is often not known. Given the remarkable overlap in clinical features, it had been previously suggested that the syndrome of diaphragmatic hernia, exomphalos, absent corpus callosum, hypertelorism, myopia, and sensorineural deafness (MIM 222448)^{1,2} and the facio-oculo-acoustico-renal syndrome (MIM 227290)^{1,3} may represent the variable expression of a single entity.^{2,4,5} In the present report, we describe a child with features previously thought to be distinctive of these two syndromes, confirming that they are in fact a single entity.

Case report

The child, a male, is the first child of healthy, unrelated parents. The pregnancy was complicated by polyhydramnios. At 34 weeks' gestation, a left posterior diaphragmatic hernia was diagnosed, but no additional abnormalities were noted. Karyotype performed on amniotic cells was normal. The child was born at 37 weeks' gestation by caesarian section. Birth weight was 3000 g (50th-75th centile), length 50.5 cm (75th-97th centile), and head circumference 35.5 (>90th centile). The diaphragmatic hernia was confirmed and surgically

repaired on the first day of life. Clinical examination showed a large anterior fontanelle, facial dysmorphism including hypertelorism with depressed nasal bridge, proptosis, downward slanting palpebral fissures, and a small mouth. The eyelashes were long. The genitalia were small with inguinal testes. There was marked axial hypotonia. Cardiac ultrasound was normal. CT scan and MRI of the brain were normal. Karyotype determined on white blood cells and skin fibroblasts was normal after high resolution G and T banding.

At the age of 6 weeks, extremely high myopia was diagnosed, -30 D and -25 D in the right and left eye, respectively. Fundoscopy was normal and no additional eye abnormalities were noted. Electroretinogram and visually evoked potentials were normal. Correction of the myopia resulted in visual stimulation of the infant.

Proteinuria was detected on a routine urine investigation on the second day of life (albustix +++). This was confirmed on all subsequent urine samples. During the second month of life, proteinuria ranging from 90 to 155 mg/day was documented. Renal ultrasound and intravenous pyelogram showed normal

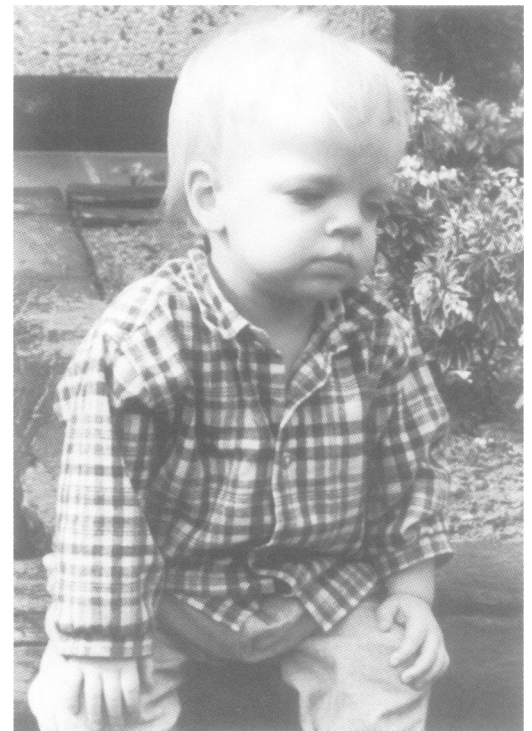


Figure 1 Clinical features of the patient aged 18 months. (Reproduced with permission).

Centre for Human Genetics, University Hospital Leuven, Herestraat 49, B-3000 Leuven, Belgium
K Devriendt
J-P Fryns

Department of Paediatrics, Neonatology Unit, University Hospital Leuven, B-3000 Leuven, Belgium
C Van Hole
H Devlieger

MPI Spermalie, B-8000 Brugge, Belgium
L Standaert

Correspondence to:
Dr Devriendt.

Received 20 April 1997
Revised version accepted for publication 18 July 1997

kidneys. Protein electrophoresis on urine showed a non-selective glomerular proteinuria. There was no associated glucosuria or amino aciduria. A variable degree of proteinuria was found in each urine sample examined during two years follow up.

At the age of 1 year, a severe bilateral sensorineural hearing loss of approximately -90 dB was diagnosed.

At the age of 2 years, there was growth retardation, with weight 9.7 kg (3rd centile=10.5 kg) and length 83 cm (3rd centile) (fig 1). He was macrocephalic with a head circumference of 52 cm (97th centile=51.7 cm). Development was delayed with a mental age of approximately 9 months (Bayley developmental scale). He was hypotonic but could sit with support. The hearing loss was unchanged.

Discussion

We report a male child with a multiple congenital anomaly-mental retardation syndrome characterised by diaphragmatic hernia, profound sensorineural hearing loss, severe myopia, facial dysmorphism with a large anterior fontanelle and hypertelorism, and developmental delay. This combination of malformations has been described as a new autosomal recessive syndrome by Donnai and Barrow² in two pairs of sibs and a fifth unrelated child. Another patient with consanguineous parents has been reported by Gripp *et al.*,⁴ supporting autosomal recessive inheritance. This entity is referred to as the hypertelorism-myopia-sensorineural deafness syndrome (MIM 222448).¹ In contrast to the previously reported cases, the present child had no agenesis of the corpus callosum and no exomphalos. However, the patient reported here had an isolated, non-selective glomerular proteinuria with morphologically normal kidneys. Proteinuria has not been documented in the previously reported patients. However, Holmes and Schepens³ have reported a brother and sister with the combination of severe sensorineural hearing loss, severe myopia, facial dysmorphism including hypertelorism and large anterior fontanelle, and proteinuria. This condition is known as the facio-oculo-acoustico-renal syndrome (FAOR, MIM 227290).¹ Three additional patients with this syndrome have been reported.⁶⁻⁸ In these patients, no diaphragmatic hernia was present and for this reason it remained uncertain whether the condition described by Donnai and Barrow² represented the same entity.

We report the first patient with features thought to be distinctive of both conditions, that is, both diaphragmatic hernia and proteinuria. This provides strong evidence that both conditions are in fact the variable expression of a single entity. In addition, it is probable that the three brothers described by Ohlsson,⁹ with high myopia, sensorineural deafness, and proteinuria (MIM 221200)¹ also represent the same entity.

The common findings present in all patients are exceptionally severe myopia, severe sensorineural hearing loss, and distinct facial dysmorphism with a large fontanelle and hypertelorism. The name facio-oculo-acoustico syndrome may therefore be appropriate to describe this condition. Variable features, described in more than one patient, include diaphragmatic hernia, ocular coloboma, exomphalos, agenesis of the corpus callosum, proteinuria, heart defect, mental retardation, and macrocephaly.

A high concordance of clinical features has been observed in the reported sibships with regard to the presence of, for instance, diaphragmatic hernia or proteinuria. This has certainly added to the previous distinction of two different entities. This could be explained by specific genotype-phenotype correlations, but more cases need to be studied to exclude ascertainment bias. In view of these findings, a careful clinical reassessment of all patients combining high myopia with sensorineural hearing loss is warranted.

- 1 McKusick VA. *Mendelian inheritance in man. Catalogs of autosomal dominant, autosomal recessive, and X-linked phenotypes.* 10th ed. Baltimore: Johns Hopkins University Press, 1992.
- 2 Donnai D, Barrow M. Diaphragmatic hernia, exomphalos, absent corpus callosum, hypertelorism, myopia and sensorineural deafness—a newly recognized autosomal recessive condition? *Am J Med Genet* 1993;47:679-82.
- 3 Holmes LB, Schepens CL. Syndrome of ocular and facial anomalies, telecanthus and deafness. *J Pediatr* 1972;81:552-5.
- 4 Gripp KW, Donnai D, Clericuzio CL, McDonald-McGinn DM, Guttenberg M, Zackai EH. Diaphragmatic hernia-exomphalos-hypertelorism syndrome: a new case and further evidence of autosomal recessive inheritance. *Am J Med Genet* 1997;68:441-4.
- 5 Opitz JM. Editor's comment. *Am J Med Genet* 1997;69:44.
- 6 Fraser GR. *The causes of profound deafness in childhood. A study of 3535 individuals with severe auditory handicaps present at birth or of childhood onset.* Baltimore: Johns Hopkins University Press, 1976:74-5.
- 7 Regenbogen LS, Coscas GJ. *Oculo-auditory syndromes.* New York: Masson; Chicago: distributed by Year Book Medical Publishers, 1985:104-5.
- 8 Schowalter DB, Pagon RA, Kalina RE, McDonald R. Facio-oculo-acoustico-renal syndrome: case report and review. *Am J Med Genet* 1997;69:45-9.
- 9 Ohlsson L. Congenital renal disease, deafness and myopia in one family. *Acta Med Scand* 1968;63:77-84.