

## Further delineation of the partial proximal trisomy 10q syndrome

Cora M Aalfs, Jan M N Hoovers, Mariëlle A Nieste-Otter, Marcel M A M Mannens, Raoul C M Hennekam, Nico J Leschot

### Abstract

**We report on a girl with a partial duplication of the proximal part of the long arm of chromosome 10, confirmed by chromosome painting. The phenotypic findings are compared to those found in six other published cases with the same karyotype. Recognition of a specific partial proximal trisomy 10q syndrome seems to be possible, consisting of mild to moderate developmental delay, postnatal growth retardation, microcephaly, prominent forehead, small and deep set eyes, epicanthus, upturned nose, bow shaped mouth, micrognathia, thick and flat helices of the ears, and long, slender limbs. Severe ocular malformations are possibly part of the syndrome. No major phenotypic differences were seen between patients with a duplication of segment 10q11→10q22 and patients with a duplication of 10q21→10q22.**

(*J Med Genet* 1995;32:968-971)

Up to now, about 30 cases of distal trisomy for the long arm of chromosome 10 have been reported.<sup>1,2</sup> Direct de novo duplications of the proximal part of 10q, however, have been described in only six patients.<sup>3-8</sup> In three of these patients a duplication of the 10q11→10q22 segment was found and in three others duplication of the 10q21→10q22 segment. No confirmation by in situ hybridisation has been reported in any of these cases.

Here, we report on a girl with a duplication of segment 10q11.2→10q22.3, confirmed by chromosome 10 painting. In order to try to delineate a clinically recognisable partial proximal trisomy 10q syndrome, a comparison of the seven known cases is made.

### Case report

The proband, a girl, was born at 42 weeks of gestation to a 37 year old father and a 35 year old mother. The unrelated parents and a 3 year old sister were healthy. At the age of 32 the mother had a spontaneous abortion at 14 weeks of gestation.

The pregnancy was uneventful but because it was post term delivery was induced by amniotomy. Birth weight was 3720 g and length at birth was 51 cm. The neonatal period was complicated by mild respiratory disease, jaundice, and feeding difficulties.

At the age of 8 months the girl had pneumonia and was admitted to hospital. She was

hypertonic with a retroflexion of the head, clenched fists, and claw feet. At that time mild psychomotor developmental delay and slight dysmorphism were noticed. At the age of 15 months the girl was referred to our department. Length (72 cm), weight (8050 g), and head circumference (45 cm) were all about the 10th centile.

Physical examination at the age of 3½ years showed height on the 3rd centile and weight and head circumference still on the 10th centile. Facial abnormalities consisted of small, deep set eyes, downward slanted palpebral fissures, epicanthus, flat nasal bridge, upturned nose, bow shaped mouth, micrognathia (fig 1), thick and flat helices, and ear pits (fig 2). A strabismus convergens alternans had been surgically corrected. Mild hypertonia of the legs and lumbar hyperlordosis were still present.

Psychomotor development was delayed. She rolled over at the age of 4 months, sat at 12 months, walked with support at 2½ years, and spoke two words at 3 years.

Physical examination indicated no internal abnormalities and routine blood investigations were normal. Audiometric investigations

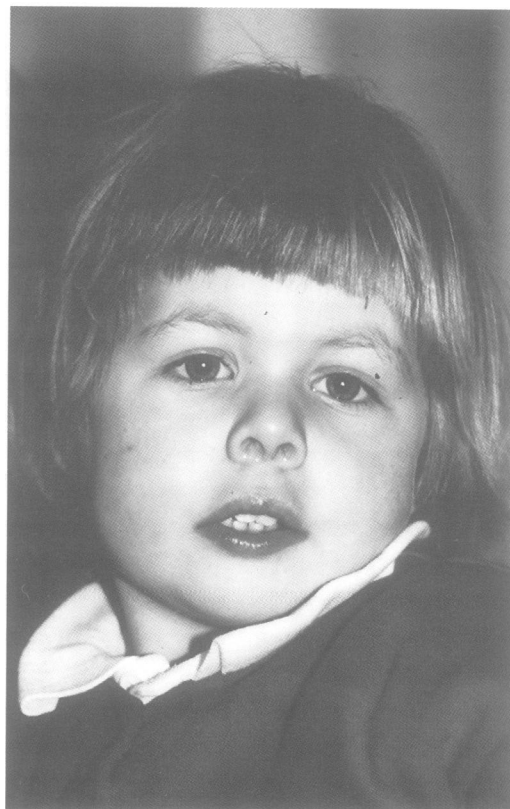

Figure 1 Present case at the age of 3½ years.

**Institute for Human Genetics, Academic Medical Centre, Meibergdreef 15, 1105 AZ Amsterdam, The Netherlands**

C M Aalfs  
J M N Hoovers  
M A Nieste-Otter  
M M A M Mannens  
R C M Hennekam  
N J Leschot

**Department of Paediatrics, Academic Medical Centre, Amsterdam, The Netherlands**  
R C M Hennekam

Correspondence to:  
Dr Aalfs.

Received 21 April 1995.  
Revised version accepted for publication 21 July 1995.

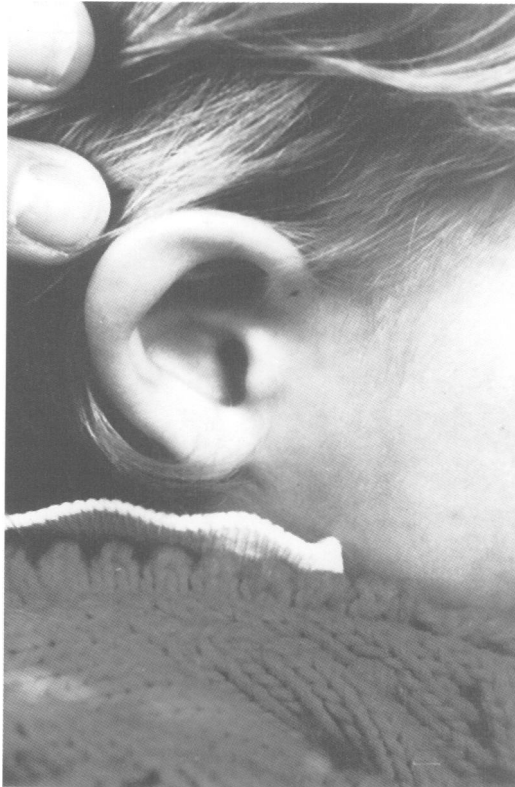

Figure 2 The ear of the present case. Note the thick and flat ear helix and the ear pit.

showed mild hearing loss, which improved after insertion of grommets. Vision was normal. Chest radiography showed first rib asymmetry, with the first rib on the left side situated anteriorly. Bone age showed a delay of 15 months.

#### CYTOGENETIC INVESTIGATION

Chromosome analysis of G banded pro-metaphase chromosomes from peripheral

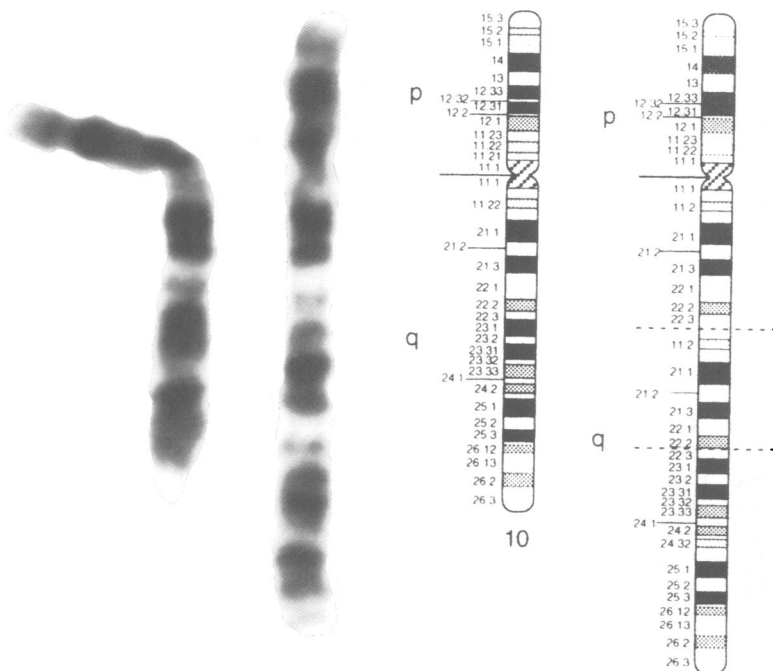


Figure 3 G banded karyotype and ideogram of the present case showing partial proximal trisomy 10q.

blood lymphocytes showed a direct duplication of the 10q11.2→10q22.3 segment (fig 3). Chromosome analysis of both parents was normal.

#### FLUORESCENCE IN SITU HYBRIDISATION (FISH) AND DNA STUDIES

FISH with a painting probe for chromosome 10 showed that the abnormal chromosome 10 was composed entirely of chromosome 10 material, confirming the cytogenetic interpretation of partial trisomy 10q (fig 4).

In order to establish the parental origin of the duplicated chromosome segment and to establish the boundaries of the duplicated region at the DNA level, we analysed DNA of the patient and her parents with eight polymorphic CA repeats (D10S88 (MFD7), D10S91 (MFD29), D10S107 (MFD78), D10S108 (MFD100), D10S109 (MFD150), D10S110 (MFD157), D10S168 (MFD175), and D10S169 (MFD187)). However, none of these markers was informative.

#### BIOCHEMICAL INVESTIGATIONS

Genes for the enzymes adenosine kinase and glutamate dehydrogenase are known to be localised to the proximal part of the long arm of chromosome 10.<sup>9-14</sup> Adenosine kinase activity was measured radiochemically essentially according to Leech and Newsholme,<sup>15</sup> following the conversion of adenosine to AMP using polyethyleneimine-cellulose thin layers. Glutamate dehydrogenase was measured spectrophotometrically as described previously.<sup>16</sup> Activities for the enzymes adenosine kinase ( $10.6 \pm 0.1$  nm/10<sup>6</sup> lymphocytes/h; normal  $7.9 \pm 3.6$  nm/10<sup>6</sup> lymphocytes/h) measured in lymphocytes and glutamate dehydrogenase

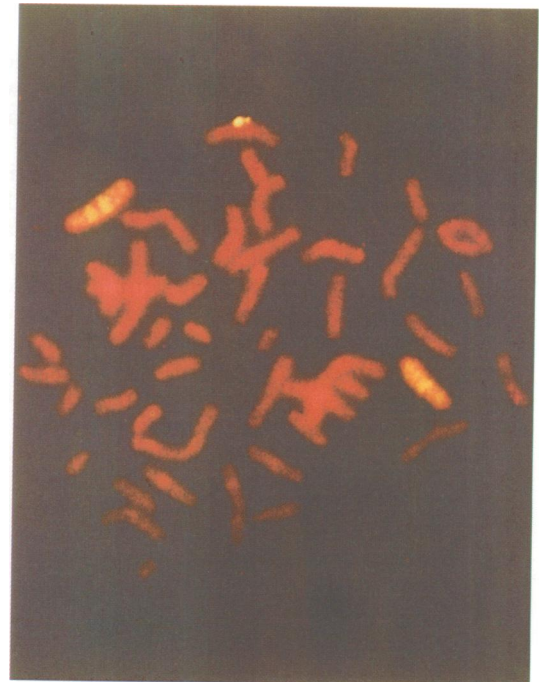

Figure 4 Results of fluorescence in situ hybridisation with a chromosome 10 paint.

Summary of clinical features in the six known cases with a partial proximal trisomy 10q syndrome

	Vogel <i>et al</i> <sup>2</sup>	Fryns <i>et al</i> <sup>7</sup>	De Michelena and Campos <sup>8</sup>	Present case	Surana <i>et al</i> <sup>4</sup>	Koivisto <i>et al</i> <sup>5</sup>	Reinthaller <sup>6</sup>
Trisomic segment	10q11→22	10q11.2→22	10q11→22	10q11.2→22.3	10q21→22	10q21→22	10q21→22
<i>General</i>							
Birth weight (g)	2200	2650	2400	3750	2800	3400	u
Growth retardation	+	+	+	+	+	+	+
Developmental delay	+	+	+	+	+	+	+
Respiratory distress	+	u	u	+	+	+	u
Hypertonia	u	u	+	+	u	-	u
<i>Craniofacial</i>							
Microcephaly	+	+	+	+	+	+	+
Prominent forehead	-	+	-	+	+	+	+
Deep set, small eyes	+	+	+	+	u	+	+
Epicanthus	-	-	-	+	+	+	+
Strabismus	-	+	+	+	u	u	-
Iris coloboma	u	+	-	-	u	+	-
Blepharophimosis	-	-	-	-	+	+	-
Retinal dysplasia	u	+	u	-	u	+	-
Upturned nose	-	+	+	+	+	-	+
Bow shaped mouth	+	+	+	+	u	+	+
Micrognathia	+	+	+	+	u	+	+
Highly arched palate	+	+	+	-	u	u	u
Flat, thick ear helix	+	+	+	+	u	u	u
<i>Skeletal</i>							
Slender limbs	+	+	-	-	+	+	u
Finger syndactyly	u	+	u	-	+	u	u
Hypermobility joints	u	+	u	-	u	+	+
Rib abnormalities*	+	-	u	u	u	+	u

Clinical features were present (+), absent (-), or unreported (u).

\* Rib abnormalities consisted of thin ribs in one patient, bifurcation of a rib in another patient, and asymmetry of the first rib in the present case.

(92 nm/min/mg protein; normal  $74 \pm 21$  nm/min/mg protein) measured in leucocytes of the proband were normal.

### Discussion

In order to investigate whether a partial trisomy 10q syndrome existed or not, we compared the findings in the present patient with the six published patients with a similar karyotype. As in all the other patients, our patient showed postnatal growth retardation, microcephaly, and mild to moderate developmental delay. Frequent dysmorphic features were prominent forehead, small, deep set eyes, epicanthus, an upturned nose, a bow shaped mouth, micrognathia, flat, thick ear helices, and long slender limbs.

Microphthalmia, colobomas, and retinal dysplasia were found in two cases (table). One of them had a duplication of the segment 10q11.1→10q22 and the other of segment 10q21→10q22. Trisomy of segment 10q21→10q22 may also be accompanied by severe ocular malformations.

Other findings in one or two of the patients (not shown in the table) were downward slanted palpebral fissures, ear pits, narrow maxilla, dental defects, preaxial polydactyly, single flexion crease, clinodactyly, camptodactyly, pes equinovarus, thoracolumbar scoliosis, supernumerary nipples, pectus excavatum, inguinal hernia, hypospadias, patent ductus arteriosus, recurrent nerve paralysis, and dermatoglyphic abnormalities. On the chest x ray of a 39 year old patient described by Reinthaller<sup>6</sup> in 1985, a slightly enlarged left configured heart with the beginning of arteriosclerosis in the ascending aorta was seen. Whether these findings are part of the syndrome or mere coincidence is not yet known.

On clinical grounds only, no clear distinction could be made between patients with a du-

plication of the 10q11→q22 segment and those with duplication of the 10q21→q22 segment. Blepharophimosis was the only major symptom that was present in two patients of the second group and in none of the first group. Furthermore, a flat, thick ear helix has been reported only in patients in the first group. Looking at the published karyotypes of the other patients, the cytogenetic interpretation seems adequate and a misinterpretation does not seem to be the cause of the lack of differences between patients with duplication of the 10q11→q22 segment or the 10q21→q22 segment, respectively. Since different duplications may have a breakpoint in common, disruption or deletion of genes at a common breakpoint may be possible. However, the number of reported patients is too small for firm conclusions.

DNA studies in the proband and her patients, to define the breakpoints at a molecular level and to establish the parental origin of the duplicated segment, were not informative. In the other patients, the parental origin of the duplicated chromosome was not mentioned. It is not possible, therefore, to draw any conclusions as to whether the parental origin of a duplicated proximal 10q segment influences the phenotype.

By chromosome segregation in somatic cell hybrids and exclusion mapping in fibroblasts, the gene for the enzyme adenosine kinase has been located to the region 10q11-10q24.<sup>9-11</sup> For glutamate dehydrogenase, the gene was located at different positions in the region 10q21-10q23 by several in situ hybridisation studies.<sup>12-14</sup> In the case of trisomy for this segment, increased activity of the enzymes may be expected. However, enzyme studies did not show any dosage differences, preventing further refinement of the breakpoints. Possibly, genes for the enzymes adenosine kinase and glutamate dehydrogenase are situated outside the

duplicated segment 10q11.2→22.3.<sup>13,14</sup> However, definite conclusions about breakpoints or gene localisation based on these biochemical investigations cannot be made because no gene dosage effect has been shown to date for either of the enzymes and, therefore, positive controls are lacking.

In conclusion, recognition of a partial proximal trisomy 10q syndrome on clinical grounds seems to be possible.

We would like to thank Dr A H van Gennip for his advice on the biochemical investigations and the family for their kind cooperation.

- 1 Yunis JJ, Sanchez O. A new syndrome resulting from partial trisomy for the distal third of the long arm of chromosome 10. *J Pediatr* 1974;**84**:567-70.
- 2 Briscioli V, Floridia G, Rossi E, Selicorni A, Lalatta F, Zuffardi O. Trisomy 10qter confirmed by in situ hybridisation. *J Med Genet* 1993;**30**:601-3.
- 3 Vogel W, Back E, Imm W. Serial duplication of 10(q11→q22) in a patient with minor congenital malformations. *Clin Genet* 1978;**13**:159-63.
- 4 Surana RB, Park MY. Trisomy 10q due to de novo duplication of q21 and q22 bands. *Am J Hum Genet* 1980;**32**:90A.
- 5 Koivisto M, Herva R, Linna SL. Serial duplication of 10(q21→q22) in a mentally retarded boy with congenital malformations. *Hum Genet* 1981;**57**:224-5.
- 6 Reinhaller A. Tandem duplication of 10(q21→q22) in a mentally deficient man. *Clin Genet* 1985;**28**:394-6.
- 7 Fryns JP, Kleczkowska A, Igodt-Ameye L, Van den Berghe H. Proximal duplication of the long arm of chromosome 10 (10q11.2→10q22): a distinct clinical entity. *Clin Genet* 1987;**22**:61-5.
- 8 De Michelena MI, Campos PJ. A new case of proximal 10q partial trisomy. *J Med Genet* 1991;**28**:205-6.
- 9 Klobutcher LA, Nichols EA, Kucherlapati RS, Ruddle FH. Assignment of the gene for human adenosine kinase to chromosome 10 using a somatic cell hybrid clone panel. *Cytogenet Cell Genet* 1976;**17**:171-4.
- 10 Francke U, Thompson L. Regional mapping, by exclusion, of adenosine kinase (ADK) on human chromosome 10 using gene dosage. *Cytogenet Cell Genet* 1979;**25**:156.
- 11 Snyder FF, Lin CC, Rudd NL, Shearer JE, Heikkila EM, Hoo JJ. A de novo case of trisomy 10p: gene dosage studies of hexokinase, inorganic pyrophosphatase and adenosine kinase. *Hum Genet* 1984;**67**:187-9.
- 12 Anagnou NP, Seuanez H, Modi W, O'Brien SJ, Papatheakis J, Moschonas N. Chromosomal mapping of the human glutamate dehydrogenase (GLUD) genes to chromosomes 10q21.1-21.2 and Xq26-28. *Am J Hum Genet (Suppl)* 1989;**45**:A170.
- 13 Jung KY, Warter S, Rumpel Y. Assignment of the GDH loci to human chromosomes 10q23 and Xq24 by in situ hybridization. *Ann Genet (Paris)* 1989;**32**:109-10.
- 14 Deloukas P, Dauwerse JG, Moschonas NK, van Ommen GJB, van Loon APM. Three human glutamate dehydrogenase genes (GLUD1, GLUDP2, and GLUDP3) are located on chromosome 10q, but are not closely physically linked. *Genomics* 1993;**17**:676-81.
- 15 Leech AR, Newsholme EA. Radiochemical assays for adenosine kinase and AMP deaminase using polyethyleneimine thin layers. *Anal Biochem* 1978;**90**:576.
- 16 Wanders RJA, van Roermund CWT, de Vries CT, et al. Peroxisomal  $\beta$ -oxidation of palmitoyl-CoA in human liver homogenates and its deficiency in the cerebro-hepato-renal (Zellweger) syndrome. *Clin Chim Acta* 1986;**159**:1-10.