
 DYSMORPHOLOGY REPORT

Postnatal short stature, microcephaly, severe syndactyly of hands and feet, dysmorphic face, and mental retardation: a new syndrome?

K Zerres, M Rietschel, E Rietschel, F Majewski, P Meinecke

Abstract

We report on a 2 year old boy with an apparently previously undescribed multiple congenital anomaly/mental retardation syndrome characterised by postnatal short stature, postnatal microcephaly, dysmorphic face, syndactyly 2/5 of the hands and 1/4 of the feet, and brachymesophalangy of fingers 2 and 5.

History

This was the first pregnancy of a non-consanguineous 27 year old mother and her 27 year old husband. The pregnancy was uneventful and delivery was by vacuum extraction because of protracted labour at 41 weeks' gestation. Apgar scores were 7, 9, and 10 at one, five, and 10 minutes, respectively.

Clinical examination

Birth weight was 3870 g (+1 SD), length 53 cm (mean), and head circumference 36 cm (mean). At birth the following features were noted: total cutaneous syndactyly of fingers 2/5 bilaterally, bilateral hip dysplasia, and club

feet with cutaneous syndactyly of toes 1/4. A systolic murmur owing to a small atrial septal defect was heard but there were no further echocardiographic abnormalities.

At the age of 2 years 4 months, he was a severely retarded boy with short stature and microcephaly. Length was 75 cm (-4.5 SD) and head circumference 45.5 cm (-3 SD). He had a dysmorphic face (fig 1) with sparse hair, convergent strabismus, bilateral epicanthic folds, anteverted nostrils, slightly prominent, poorly structured philtrum, and moderate microgenia. He had a small penis with bilateral cryptorchidism. His hands (fig 2) showed almost complete cutaneous syndactyly 2/3 on the right and also syndactyly 2/3 and 4/5 on the left. The thumbs were somewhat broad. The feet (fig 3) showed almost complete cutaneous syndactyly 1/3 and slight syndactyly 3/4 bilaterally.

Investigations

Radiographs of the hands and feet as a newborn showed, apart from syndactyly of fingers 2/5, brachymesophalangy of fingers 2 and 5 and club feet with cutaneous syndactyly of toes 1/4. The middle phalanges of toes 2 to 4 were unossified. At 2 months radiographs of the left hand (fig 4) showed syndactyly 2/5, marked

Institut für
Humangenetik der
Universität Bonn,
Wilhelmstrasse 31,
D-5300 Bonn 1,
Germany.
K Zerres
M Rietschel

Kinderklinik der
Universität Köln,
Germany.
E Rietschel

Institut für
Humangenetik der
Universität
Düsseldorf, Germany.
F Majewski

Abteilung
Medizinische Genetik,
Altonaer
Kinderkrankenhaus,
Hamburg, Germany.
P Meinecke

Correspondence to Dr Zerres.

Received 8 July 1991.

Accepted 31 July 1991.

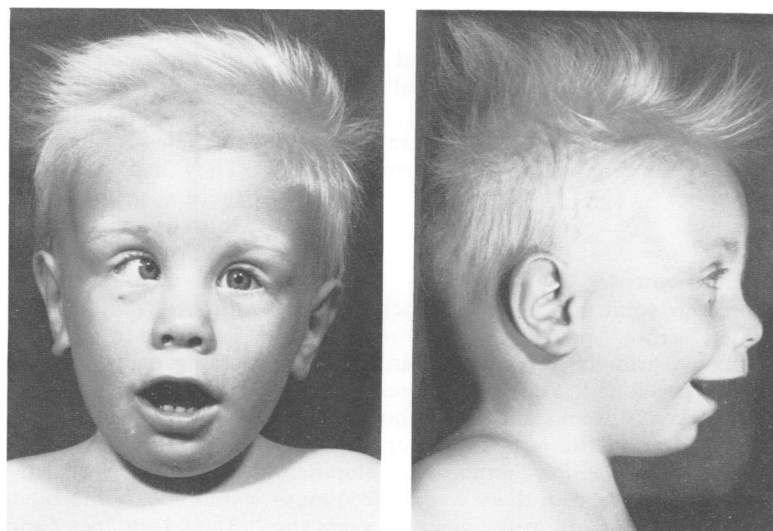


Figure 1 The patient aged 2 years. Note dysmorphic face (resembling Smith-Lemli-Opitz syndrome).

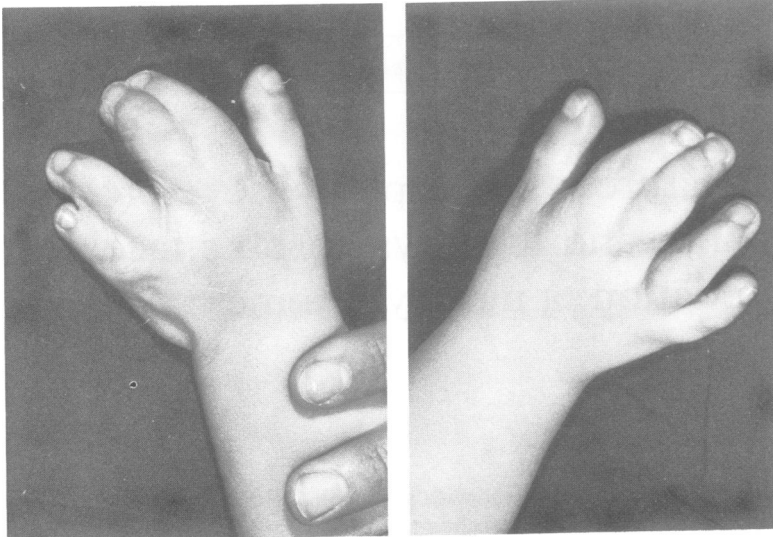


Figure 2 Note syndactyly of fingers after surgical treatment.

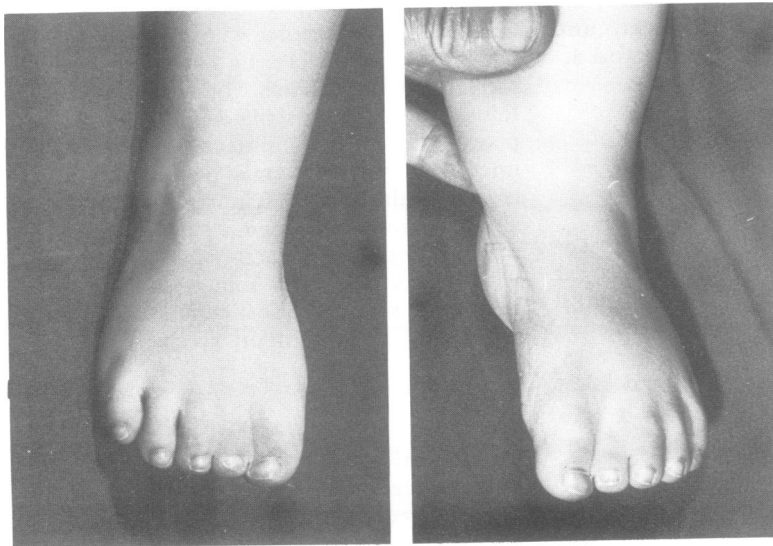

Figure 3 Note syndactyly of toes 1/4.

brachymesophalangy of fingers 2 and 5, and a broad distal phalanx of the thumb.

There was a small neurocranium with no craniostenosis. CT scan of the head at 5 weeks showed minimally enlarged lateral ventricles but otherwise no abnormalities.

Cytogenetic studies on peripheral lymphocytes (Q banding) showed a normal 46,XY karyotype.

Clinical course

There was vomiting in early infancy of unexplained cause (pyloric stenosis excluded). Postnatal growth retardation and microcephaly developed. The first seizures occurred at the age of 4 weeks and EEG showed focal dysrhythmia on the left and abnormal slowness on the right. Psychomotor development was severely retarded, there was marked muscular hypotonia, and at the age of 2 years the boy was not able to sit unsupported. He had impaired hearing.

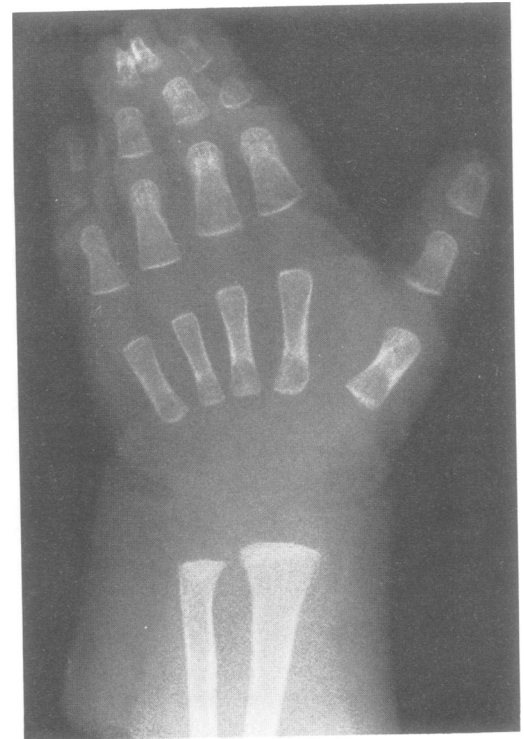


Figure 4 The left hand at 2 months. Note syndactyly 2/5 and brachymesophalangy 2 and 5 as well as broad distal first phalanx (courtesy of Professor J A Bliesener, Städtische Kinderklinik, Köln Riehl).

Discussion

The present combination of postnatal short stature, dysmorphic face, microcephaly, severe syndactyly of the hands and feet together with brachymesophalangy of fingers 2 and 5, and severe psychomotor retardation has, to our knowledge, not been reported before.

There are only a few other conditions which show some resemblance to our patient's disorder. Some of the proband's features (especially the facial aspect) are seen in Smith-Lemli-Opitz (SLO) syndrome, but the particularly severe expression of syndactyly and the brachymesophalangy have not previously been described in SLO syndrome. Normal measurements at birth also argue against SLO, so this diagnosis can probably be excluded.

Patients with Scott syndrome¹ are said to show similar facial features to those with Saethre-Chotzen syndrome but differ in having growth deficiency and moderate to severe mental retardation, but no craniostenosis. They had brachydactyly of the hands and there was cutaneous syndactyly of toes 2 and 3. Inheritance is probably X linked.

Variable syndactyly is also a feature in Carpenter syndrome and the closely related Summit syndrome. However, the phenotype is different in our patient and there is lack of craniostenosis.

Filippi² described three sibs of different sex with unusual facies (bulging forehead, broad and prominent nasal bridge, and diminished alar flare), retarded physical and mental development, and bilateral syndactyly of fingers 3 and 4 and toes 2 and 3. The two boys also had cryptorchidism. Inheritance is probably autosomal recessive.

An isolated mentally retarded patient with short stature, microcephaly, congenital heart defect, and a dysmorphic face with strabismus, bilateral epicanthus, and prominent philtrum was described by Wiedemann *et al.*³ However, syndactyly of the hands and feet was less severe with cutaneous syndactyly 2/4 of the hands and syndactyly 1/2 of the toes.

In conclusion, despite some similarity between a few published cases and our patient, there are striking differences which argue in

favour of a distinct disorder. Thus our patient probably represents a hitherto undescribed 'new' MCA/MR syndrome.

- 1 Scott CR, Bryant JR, Graham CR. A new craniodigital syndrome with mental retardation. *J Pediatr* 1971; 78:658-64.
- 2 Filippi G. Unusual facial appearance, microcephaly, growth and mental retardation, and syndactyly. A new syndrome? *Am J Med Genet* 1985;22:821-4.
- 3 Wiedemann HR, Kunze J, Dibbern H. *Atlas der Klinischen Syndrome*. 3rd ed. Stuttgart: Schattauer, 1989:172-3.