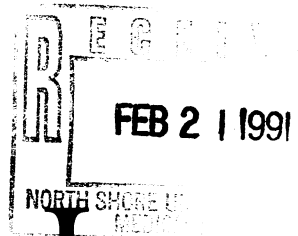




51027000216539

*Journal of*

# MEDICAL GENETICS

- Review article** 73 Inherited amyloidosis *M D Benson*
- Original articles**
- 79 Genetic aspects of antibiotic induced deafness: mitochondrial inheritance *D-N Hu, W-Q Qiu, B-T Wu, L-Z Fang, F Zhou, Y-P Gu, Q-H Zhang, J-H Yan, Y-Q Ding, H Wong*
- 84 Identification of new DNA markers close to the myotonic dystrophy locus *J D Brook, H G Harley, K V Walsh, S A Rundle, M J Siciliano, P S Harper, D J Shaw*
- 89 Prenatal diagnosis of myotonic dystrophy using closely linked flanking markers *C Lavedan, H Hofmann, P Shelbourne, C Duros, D Savoy, K Johnson, C Junien*
- 92 The origin of a morphologically unidentifiable human supernumerary minichromosome traced through sorting, molecular cloning, and in situ hybridisation *E Raimondi, L Ferretti, B D Young, V Sgaramella, L De Carli*
- 97 An analysis of amplified insulin gene products in diabetics of Indian origin *G A Hitman, P K Kambo, M Viswanathan, V Mohan*
- 101 Tay-Sachs disease heterozygote detection: use of a centrifugal analyser for automation of hexosaminidase assays with two different artificial substrates *E C Landels, I H Ellis, M Bobrow, A H Fensom*
- 110 Clustering of malformations in the families of South American oral cleft neonates *B G Menegotto, F M Salzano*
- 114 Familial cutaneous photosensitivity and colitis with lethal outcome *Ph Labrune, P Huguet, D Alagille, M Odievre*
- 117 Pitfalls in counselling: the craniosynostoses *R Marini, K Temple, L Chitty, S Genet, M Baraitser*
- Syndrome of the month** 122 Tetrasomy 12p (Pallister-Killian syndrome) *A Schinzel*
- Case reports**
- 126 A malformed child with a recombinant chromosome 7, rec(7) dup p, derived from a maternal pericentric inversion inv(7)(p15q36) *A Delicado, E Escribano, I Lopez Pajares, A Diaz de Bustamante, S Carrasco*
- 128 Two cases of interstitial deletion 1p *M M R Lai, M F Robards, A C Berry, C N Fear, C Hart*
- 131 The Ohdo blepharophimosis syndrome: a third case *L Biesecker*
- 135 Cleft lip and palate, sensorineural deafness, and sacral lipoma in two brothers: a possible example of the disorganisation mutant *R B Lowry, S-L Yong*
- 138 Human homologue for the mouse mutant disorganisation: does it exist? *K K Naguib, M S Hamoud, E S Khalil, M Y El-Khalifa*
- Dysmorphology report** 140 Unknown syndrome: mental retardation with dysmorphic features, early balding, patella luxations, acromicria, and hypogonadism *F A Scholte, J H Begeer, A J van Essen*
- Letters to the Editor**
- 143 Cornelia de Lange syndrome with ring chromosome 3 *G N Wilson*
- 143 Linear skin defects and congenital microphthalmia: a new syndrome at Xp22.2 *J Allanson, S Richter*