

Autosomal recessive epidermolytic palmoplantar keratoderma

Qasem A Alsaleh, Ahmad S Teebi

Abstract

Palmoplantar keratoderma (PPK) is a heterogeneous group of disorders. Epidermolytic PPK is a well delineated autosomal dominant entity, but no recessive form is known. Here we report two sons of phenotypically normal, consanguineous, Arab parents with features suggestive of PPK. They presented with patchy eczematous skin lesions followed by PPK and raised serum levels of IgE. Skin biopsy from the keratotic lesions showed the features of epidermolytic hyperkeratosis. Autosomal recessive inheritance is suggested and the differential diagnosis is discussed.

Various forms of hereditary PPK have been described that differ in the mode of inheritance and clinical manifestations. They are usually classified according to the inheritance pattern, yet a number of rare cases are not easily classified.¹ Epidermolytic hyperkeratosis based on histopathological findings has been reported as an autosomal dominant disorder.²⁻⁴ Autosomal recessive inheritance, on the other hand, has not been described.⁵ We report here two sons of phenotypically normal, consanguineous parents with features of epidermolytic palmoplantar keratoderma.

Case reports

CASE 1

Case 1 presented to us at the age of 2 years because of palmoplantar keratoderma. He was born normally at term after an uneventful pregnancy. His parents are

first cousins of Bedouin ancestry. They have one normal child in addition to another affected younger one. There were no other family members with a similar disorder, nor any with atopy. The condition started two months after delivery with a scaly perioral erythema, followed by the appearance of patchy, circumscribed, eczematous lesions on the trunk and limbs associated with itching. By the age of 2 years, he developed a diffuse PPK that became more hyperkeratotic with time and showed deep fissures. Similar but focal hyperkeratotic lesions were also seen on both legs and the dorsal aspect of both feet (fig 1). Teeth, hair, nails, hearing, and vision were all normal.

Biopsy of the keratotic skin lesions showed a hyperkeratotic horny layer, an increased granular cell layer with clumps of keratohyalin granules, and acanthotic vacuolised epidermal cells (fig 2).

Routine haematological and biochemical investigations were normal. Urinary thin layer chromatography (TLC) showed generalised non-specific aminoaciduria. Plasma amino acid analysis was normal. Analysis of quantitative immunoglobulins showed normal levels of IgA, IgM, and IgG, while IgE was markedly raised.

CASE 2

Case 2, a brother of case 1, presented to us at the age of 2 months and showed similar clinical features (fig 3). These are summarised in table 1.

Discussion

Our patients showed clinical manifestations of diffuse PPK which on biopsy showed it to be epidermolytic hyperkeratosis, reported to be a dominantly inherited

Dermatology Unit, Farwania Hospital, Kuwait.
Q A Alsaleh

Kuwait Medical Genetics Centre, Maternity Hospital, Kuwait.
A S Teebi

Correspondence to Dr Teebi, PO Box 36660, Raas 24757, Kuwait.

Received for publication 12 November 1989.

Revised version accepted for publication 6 March 1990.

Table 1 Manifestations in the two sibs.

	Case 1	Case 2
Sex	Male	Male
Growth and development	Normal	Normal
Palmoplantar keratoderma	+++	++
Scaly perioral erythema	+	+
Eczematous lesions	+	-
Generalised aminoaciduria (TLC)	+	-

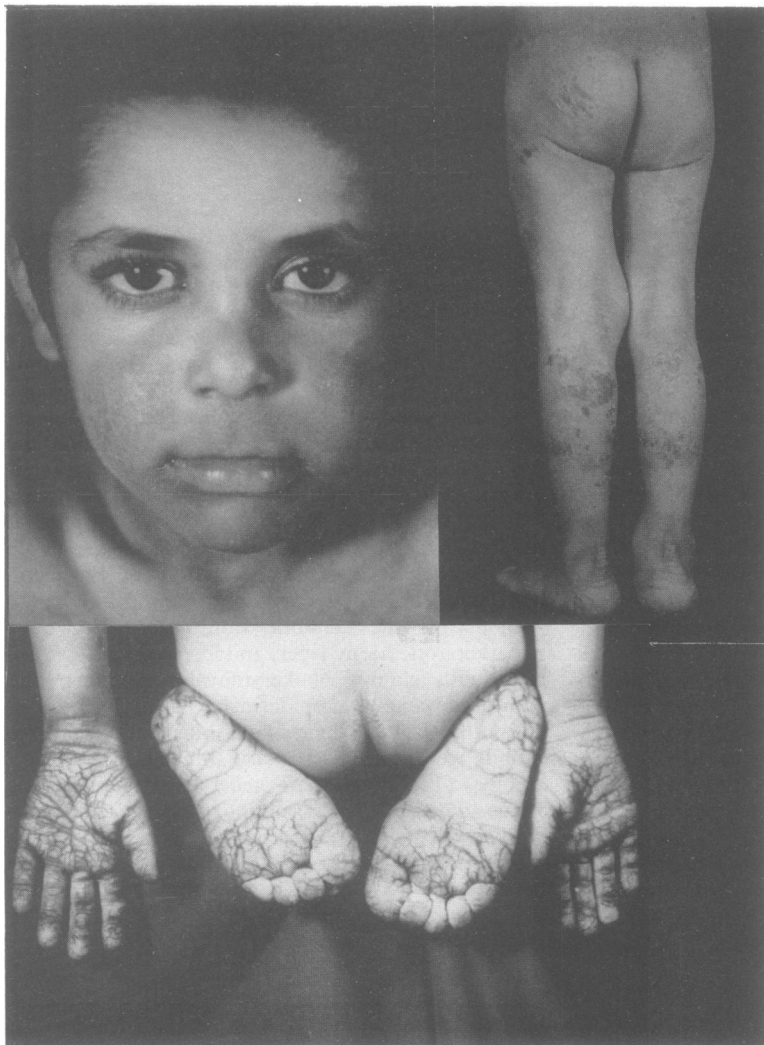


Figure 1 Case 1 at 6 years showing scaly perioral erythema, palmoplantar keratoderma, and patchy eczematous lesions.

Table 2 Differentiating features of autosomal recessive disorders with PPK.

	Mal de Meleda syndrome	Richner-Hanhart syndrome	Papillon-Lefevre syndrome	Our cases
PPK	+	+ (localised)	+	+
Epidermolytic hyperkeratosis (microscopy)	-	-	-	+
Eczema	-	-	-	+
Teeth anomalies	-	-	+	-
Mental retardation	?	+	-	-
Raised IgE	-	-	-	+
Raised amino acids	-	Plasma (tyrosine)	-	Urine, NS (one patient)

NS = non-specific.

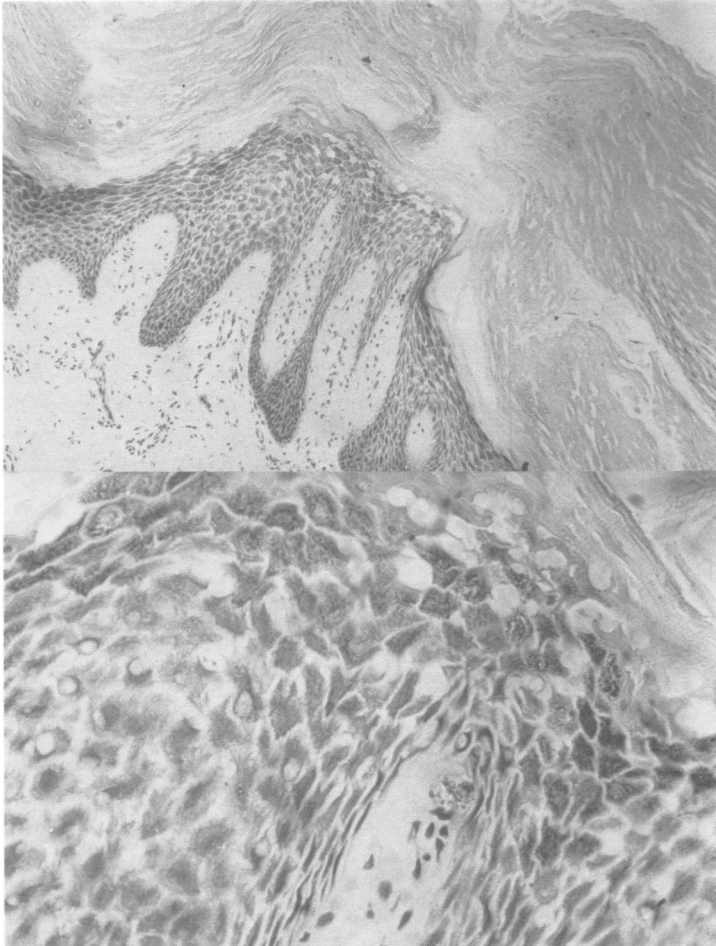


Figure 2 (Top) Photomicrograph of case 1 showing marked hyperkeratosis of horny layer, increased granular cell layer in some parts, and acanthotic vacuolated epidermal cells. (Bottom) The same photomicrograph at higher power showing vacuolised cells in upper Malpighian layers and clumpy keratohyalin granules.

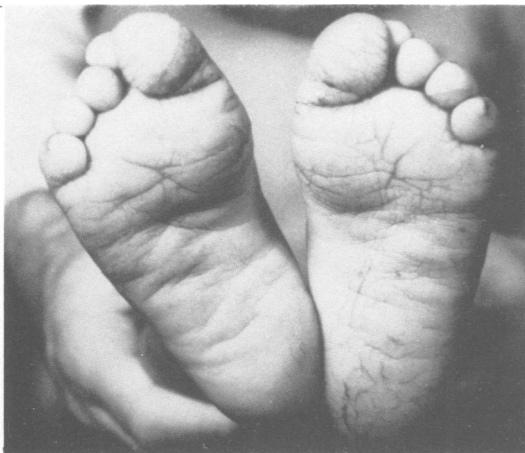

Figure 3 Plantar keratoderma in case 2 at 2 years.

disorder.²⁻⁴ Since the parents of our patients are normal and consanguineous, autosomal recessive inheritance is suggested. Therefore, several disorders were considered in the differential diagnosis, including the Mal de Meleda syndrome,⁶ Richner-Hanhart syndrome,⁷ and Papillon-Lefevre syndrome⁸ (table 2). Since both our patients are males, X linked inheritance cannot be ruled out.

We think that the patients described here represent a distinct form of PPK, which differs from autosomal dominant epidermolytic PPK not only in the mode of inheritance, but also in the associated manifestations. In our patients, in the absence of a family history of atopy, such manifestations included the patchy eczematous lesions and the raised serum IgE levels.

1 Ebling FJ, Marks R, Rook A. Disorders of keratinization. In: Rook A, Wilkinson DS, Ebling FJ, Champion RH, ed. *Textbook of dermatology*. 4th ed. Oxford: Blackwell Scientific Publications, 1986:1393-468.

- 2 Klaus S, Weunstein GD, Frost P. Localized epidermolytic hyperkeratosis. A form of keratoderma of the palms and soles. *Arch Dermatol* 1970;**101**:272-5.
- 3 Fritch P, Honigsmann H, Jaschke E. Epidermolytic hereditary palmoplantar keratoderma. *Br J Dermatol* 1978;**99**:561-8.
- 4 Blasik LG, Dimond RL, Baughman RD. Hereditary epidermolytic palmoplantar keratoderma. *Arch Dermatol* 1981;**117**:229-31.
- 5 McKusick VA. *Mendelian inheritance in man. Catalogs of autosomal dominant, autosomal recessive, and X-linked phenotypes*. 8th ed. Baltimore: Johns Hopkins University Press, 1988.
- 6 Niles HD, Klumpp MM. Mal de Meleda: review of the literature and report of four cases. *Arch Dermatol Syph* 1939;**39**:409-21.
- 7 Goldsmith LA, Kang E, Bienfang DC, et al. Tyrosinaemia with plantar and palmar keratosis and keratitis. *J Pediatr* 1973;**83**:798-805.
- 8 Bach JN, Levan NE. Papillon-Lefevre syndrome. *Arch Dermatol* 1968;**97**:154-8.