

Partial trisomy 12q: report of a case and review

SUMMARY A malformed male infant with pure partial trisomy 12q (q24·1→qter), resulting from an unbalanced segregation of a paternal balanced translocation $t(2;12)(q37;q24·1)$, is described. The cytogenetic and clinical abnormalities of the proband are compared with those of four previously reported cases of partial trisomy 12q, two of which also appear to have pure trisomy of segment 12q24·1→12qter.

There are, apparently, only four previously reported cases with any significant partial trisomy 12q,¹⁻⁴ two of which appear to have no other chromosome imbalance.^{2,4} Here we describe the clinical and

cytogenetic abnormalities in a new case of pure partial trisomy 12q, compare the findings with those in the four previous reports, and discuss the cause of the low incidence of this anomaly.

Case report

The proband was born after an uncomplicated pregnancy and delivery at 36 weeks' gestation. His parents, who already had a normal daughter, were unrelated and healthy. The mother was aged 22 years and the father 25 years. There was no family history of spontaneous abortions or stillbirths. At birth the proband weighed 2650 g and his Apgar score was 9. During the first week he received surgical correction of anal stenosis but otherwise his neonatal period was normal.

On presentation at the Clinica Pediatrica,

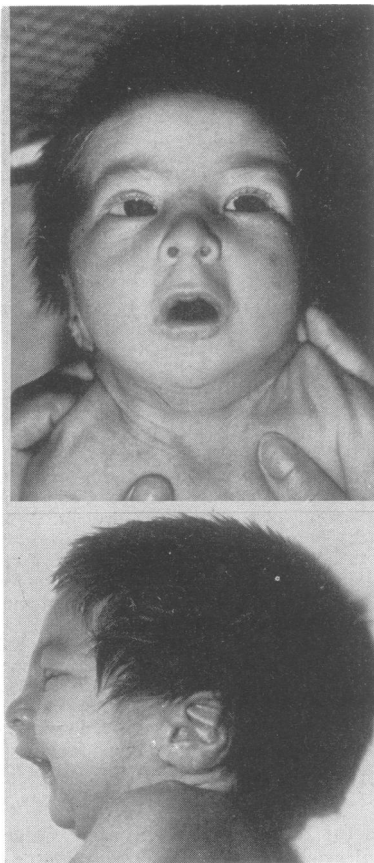


FIG 1 Front and side view of proband at 5 weeks.

Received for publication 21 January 1981

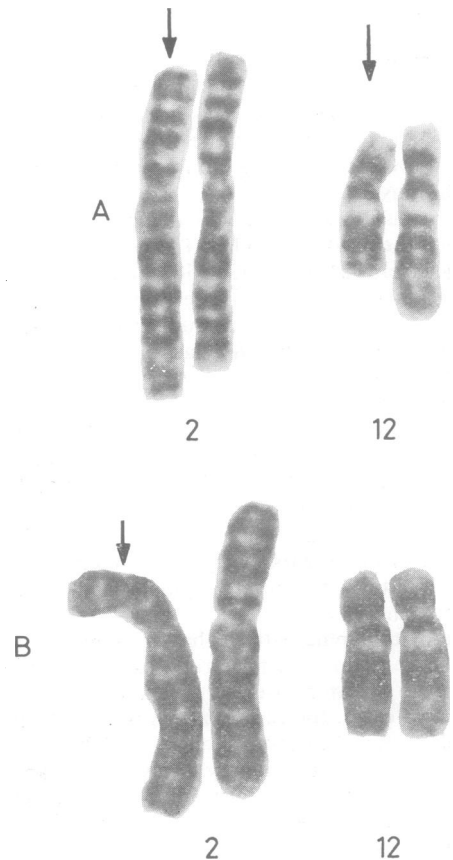


FIG 2 Partial karyotypes of father (A) showing balanced translocation involving chromosomes 2 and 12 (arrows) and proband (B) showing derived chromosome 2 (arrow).

Case reports

University of Catania at 5 weeks, his weight was 2850 g, length 46.5 cm, and head circumference 34.5 cm. He had an odd facies (fig 1, table), a short neck with redundant skin folds, clenched hands with overlapping fingers and clinodactyly of fingers 3 and 5, bilateral hammer toes, a sacral dimple, a small penis, and undescended testes. A cardiac systolic murmur was audible along the left sternal border and x-ray investigation revealed enlargement of the left third cardiac arch. Dermatoglyphic studies showed bilateral transverse single palmar creases and hypoplasia of the digital dermal ridges with a finger

tip pattern of 5A, 4Lu, and 1W. Both eyes showed myopic refraction.

On re-examination at 4 months, the previously noted abnormalities were still evident and the child showed severe physical and psychomotor retardation.

CYTOGENETIC STUDIES

Chromosome preparations were obtained from peripheral blood using standard techniques⁵ and GTG banded⁶ with a method modified from that of Seabright.⁷ The karyotype of the father was shown to be 46,XY,t(2;12)(q37;q24·1) (sub-division of

TABLE *Cytogenetic and clinical details in cases of partial trisomy 12q*

| | Cases with an associated significant monosomy | | Cases with a pure partial trisomy | | |
|-----------------------------|---|--|--|---|--|
| | Hirschhorn et al ¹ | Prieur et al ³ | Hobolth et al ² | Hemming and Brown ⁴ | Present case |
| <i>Cytogenetic findings</i> | | | | | |
| Karyotype | 46,XX,der(4), t(4;12)(q26;q12)pat | 46,XY,der(9), t(9;12)(q21;q24·2) mat | 46,XY,der(21), t(12;21)(q24·1;p11) mat | 46,XX,der(18), t(12;18)(q24·1;q23) pat | 46,XY,der(2), t(2;12)(q37;q24·1) pat |
| Segregation | Adjacent 1 or alternate | Adjacent 1 or alternate | Adjacent 1 or alternate | Adjacent 1 or alternate | Adjacent 1 or alternate |
| Trisomy | 12q12→12qter | 12q24·2→12qter | 12q24·1→12qter | 12q24·1→12qter | 12q24·1→12qter |
| Monosomy | 4q26→4qter | 9p21→9pter | 21p11→21pter | — | — |
| <i>Clinical findings</i> | | | | | |
| Gestation (wk) | | | 44 | 36 | 36 |
| Birthweight (g) | | | 3500 | 2680 | 2650 |
| Head | | Trigonocephaly* | Brachycephaly, flat top | Brachycephaly, flat occiput | Dolichocephaly, ossified anterior fontanelle |
| Eyes | | Upward slanting palpebral fissures* | Upward slanting palpebral fissures | | Upward slanting palpebral fissures |
| Ears | | | Poorly lobulated, low set | Poorly lobulated | Malformed helix and antihelix, poorly lobulated, low set |
| Nose | | Short nose,* flat nasal root,* long philtrum* | Broad bridge, down turned tip, long philtrum* | Small nose, flat bridge | Narrow and flat bridge, long philtrum |
| Mouth | Harelip, cleft palate | Micrognathia* | Micrognathia* | | Micrognathia, high arched palate |
| Neck | | | Redundant skin folds | Short neck, redundant skin folds | Short neck, redundant skin folds |
| Hands and feet | | Bilateral hexadactyly | Bilateral simian crease, hammer toes | Right hand simian crease, increased distance between toes 1 and 2 of left foot | Bilateral simian crease, clinodactyly of fingers 3 and 5, clenched hands, hammer toes |
| Genitalia | | Cryptorchidism, hypospadias | Cryptorchidism | Atretic follicles in both ovaries | Cryptorchidism, small penis |
| Anus and sacral region | | | | Anteriorly displaced anus, sacral dimple | Anal stenosis, sacral dimple |
| Heart | Cardiopathy | Coarctation of aorta, patent foramen ovalis, ventricular hypertrophy | Cardiopathy | | Cardiopathy |
| Musculature | | Subumbilical hernia with agenesis of muscles | | Hypotonia | Hypotonia |
| Others | | Disc-shaped kidneys, diaphragm-like incisions of liver | Excessive hair on lower back, angulation of sternum with prominent xiphoid process, liver enlargement, psychomotor retardation | Single umbilical artery, increased nipple width, short proximal limbs, dislocated hips, large intestine malrotation, pelvic kidney, shallow epiglottic valleculae, brain malformation | Thick hair with low-set hairline, sparse eyebrows, myopia, weak cry, psychomotor retardation |
| Survival | | 6 months | Alive at 2 years | 6 days (died of pneumonia) | Alive at 10 months |

*Observed in photographs only.

12q24 as in Sanchez *et al*⁸) and that of the proband 46,XY,der(2),t(2;12)(q37;q24·1)pat (fig 2). The proband was thus trisomic for segment 12q24·1→12qter with no detectable monosomy of 2q.

The karyotype of the mother was normal but the family did not consent to cytogenetic investigation of other relevant family members, who were, however, phenotypically normal.

Discussion

Full trisomy 12 has not been reported in liveborn subjects or in cytogenetic surveys of perinatal mortalities^{9 10} and has only very occasionally been detected in studies of spontaneous abortuses, in embryos showing an early arrest of development.^{11 12} Similarly, trisomy 12 mosaicism has very rarely been found.¹³

Cases with any significant trisomy of long arm material of chromosome 12 are also extremely rare with only four previous reports, all involving liveborn infants.¹⁻⁴ In contrast, there have been many liveborn cases with trisomy of short arm material of chromosome 12, a few including the juxtacentromeric region of 12q, for which a clinical syndrome has been delineated.¹⁴ Conversely, in balanced translocations of chromosome 12 there is far greater involvement of the long arm than the short arm.¹⁵ This discrepancy may be an indication of the lethality of additional long arm material, which would account for the almost complete non-viability of the full trisomic condition. However, since the abnormalities in three of the cases of partial trisomy 12q (present case^{2 3}) were compatible with an extended postnatal survival, the relatively low frequency of partial trisomy 12q in the liveborn population may be the result of factors other than lethality, such as a high level of alternate segregation with a low level of interstitial chiasmata.¹⁶

The case described here and the previous reports of partial trisomy 12q are similar in resulting from an alternate or adjacent 1 segregation (with and without an uneven number of interstitial chiasmata respectively¹⁶) of a parental balanced translocation (table). The exchange point on chromosome 12 in the cases described by Hobolth *et al*,² Hemming and Brown,⁴ and the present report appears to be at q24·1, resulting in trisomy of an almost identical segment of 12q. Furthermore, no monosomy of the derived chromosome could be detected in the present case and that of Hemming and Brown,⁴ because in both instances either the parental translocation was non-reciprocal or the exchange point was telomeric in the recipient chromosome. In addition, the report of Hobolth *et al*² can also be considered to be a pure trisomy of segment 12q24·1→12qter since the absence of 21p, resulting from the reciprocity of the

parental translocation, is unlikely to have contributed to the abnormal phenotype.¹⁷ However, in the cases of Hirschhorn *et al*¹ and Prieur *et al*³ the parental translocations were both reciprocal and almost symmetrical, resulting in trisomy of nearly the whole of 12q with monosomy of the distal half of 4q, and trisomy of segment 12q24·2→12qter with monosomy of the distal half of 9p, respectively.

In the latter two cases it seems improbable that a definite distinction can be made between the phenotypic expression of the partial monosomy and the partial trisomy 12q. It is possible that in the case of Hirschhorn *et al*,¹ for which few clinical details are available, both the partial monosomy 4q and the partial trisomy 12q contributed to the abnormalities reported. However, Prieur *et al*³ considered that the clinical features in the case they described were, in the main, consistent with the syndrome associated with partial monosomy 9p.

It appears likely, therefore, that a phenotypic comparison that only includes the cases with a pure partial trisomy 12q (present case^{2 4}) will be more informative. The clinical features which appear to be common to the present case and to either or both of the other two are upward slanting palpebral fissures,² poorly lobulated ears^{2 4} which are low set,² flat nasal bridge,⁴ long philtrum,² micrognathia,² short neck with redundant skin folds,^{2 4} simian creases,^{2 4} hammer toes,² cryptorchidism,² sacral dimples,^{2 4} hypotonia,⁴ cardiopathy,² and psychomotor retardation² (table).

Although there are as yet too few cases to delineate a phenotype for partial trisomy 12q, it is probable that the consistent features in the three cases with pure trisomy of apparently the same segment (q24·1→qter) of chromosome 12 will form the basis of a clinical syndrome which will be defined further with the accumulation of more data.

The authors wish to thank Mr P J Gregory, Dr D P Duckett, and Dr R A F Macleod for their critical evaluation of the manuscript, and Professor F Mollica for helpful advice.

S H ROBERTS,* T MATTINA,*† K. M. LAURENCE,* G. SORGE,† AND L. PAVONE†

*Cytogenetics Unit, Child Health Laboratories, Department of Child Health, University Hospital of Wales, Heath Park, Cardiff, Wales, and

†Clinica Pediatrica, Viale A. Doria, Università di Catania, Italy

References

- Hirschhorn K, Lucas M, Wallace I. Precise identification of various chromosomal abnormalities. *Ann Hum Genet* 1973;36:375-9.

Case reports

² Hobolth N, Jacobsen P, Mikkelsen M. Partial trisomy 12 in a mentally retarded boy and translocation (12;21) in his mother. *J Med Genet* 1974;11:299-303.

³ Prieur M, Couturier J, Herrault A, Lepintre J, Lejeune J. Cited in Réthoré M. Syndromes involving chromosomes 4, 9 and 12. In: Yunis JJ, ed. *New chromosomal syndromes*. New York: Academic Press, 1977:119-83.

⁴ Hemming L, Brown R. Partial trisomy 12q associated with a familial translocation. *Clin Genet* 1979;16:25-8.

⁵ Moorhead PS, Nowell PC, Mellman WJ, Battips DM, Hungerford DA. Chromosome preparations of leukocytes cultured from human peripheral blood. *Exp Cell Res* 1960;20:613-6.

⁶ ISCN (1978). An international system for human cytogenetic nomenclature. *Birth Defects* 1978;14:No 8.

⁷ Seabright M. A rapid banding technique for human chromosomes. *Lancet* 1971;ii:971-2.

⁸ Sanchez O, Yunis JJ, Escobar JI. Partial trisomy 11 in a child resulting from a complex maternal rearrangement of chromosomes 11, 12, and 13. *Humangenetik* 1974;22:59-65.

⁹ Machin GA, Crolla JA. Chromosome constitution of 500 infants dying during the perinatal period. *Humangenetik* 1974;23:183-98.

¹⁰ Kuleshov NP. Chromosome anomalies of infants dying during the perinatal period and premature newborn. *Hum Genet* 1976;31:151-60.

¹¹ Boué J, Daketsé MJ, Deluchat C, Ravisé N, Yvert F, Boué A. Identification par les bandes Q et G des anomalies chromosomiques dans les avortements spontanés. *Ann Genet (Paris)* 1976;19:233-9.

¹² Kajii T, Ferrier A, Niikawa N, Takahara H, Ohama K, Sugandhi A. Anatomic and chromosomal anomalies in 639 spontaneous abortions. *Hum Genet* 1980;55:87-98.

¹³ Richer CL, Bleau G, Chapdelaine A. Trisomy 12 mosaicism in an infertile man. *Can J Genet Cytol* 1977;19:565-7.

¹⁴ Kondo I, Hamaguchi H, Haneda T. Trisomy 12p syndrome: de novo occurrence of mosaic trisomy 12p in a mentally retarded boy. *Hum Genet* 1979;46:135-40.

¹⁵ Biederman B, Bowen P. Balanced translocations involving chromosome 12: report of a case and possible evidence for position effect. *Ann Genet (Paris)* 1976;19:257-60.

¹⁶ Hamerton JL. General cytogenetics. In: *Human cytogenetics*. Vol 2. New York: Academic Press, 1971:248-54.

¹⁷ Neilsen J, Friedrich V, Hreidarsson AB. Frequency of deletion of short arm satellites in acrocentric chromosomes. *J Med Genet* 1974;11:177-80.

¹⁹ Harrod MJE, Byrne JB, Dev VG, Francke U. Duplication 12q mosaicism in two unrelated patients with a similar syndrome. *Am J Med Genet* 1980;7:123-9.

²⁰ Zabel B, Baumann W. Partial trisomy 12q. *J Med Genet* 1981;18:144-6.

Unilateral radial aplasia and trisomy 22 mosaicism

SUMMARY A child with unilateral radial aplasia, asymmetry, other malformations, and severe physical and mental retardation is reported. In blood and bone marrow cultures a low mosaicism for trisomy 22 was found. In a few cells a chromosome 22 was missing. The importance of early cytogenetic analysis on large numbers of cells is emphasised, especially in cases of asymmetry where mosaicism is suspected.

Radial dysplasia is a relatively common limb malformation which has been associated with major anomalies in various systems, mostly genitourinary, skeletal, gastrointestinal, and cardiac. It may occur within a definite syndrome, for example, thrombocytopenia and absent radius (TAR), Holt-Oram syndrome, Fanconi's anaemia, and VATERL association, and it has also been reported in chromosomal disorders like trisomy 13 and 18.¹

We describe a child with total unilateral radial aplasia associated with a clustering of defects on the same side, in whom trisomy 22 mosaicism was demonstrated.

Case report

A 2900 g female child was born after a normal pregnancy and delivery to non-consanguineous parents of Arabic origin. The 25-year-old mother, the 36-year-old father, and the four other children were healthy. There was no history of any congenital anomaly in the family.

A clustering of malformations was evident on the left side including a small palpebral fissure with slight ptosis, hypotrophy of the cheek, a low set ear with abnormal configuration of the helix, and mild stenosis of the external auditory canal. Total left radial aplasia with absent thumb was present (fig 1). The left forearm, hand, and the four medial fingers were smaller than those on the right side and there was colateral clinodactyly of the little finger with only one transverse crease on the left.

Repeated blood counts, including platelet and

Received for publication 14 January 1981

Requests for reprints to Mr SH Roberts, Cytogenetics Unit, Child Health Laboratories, Department of Child Health, University Hospital of Wales, Heath Park, Cardiff CF4 4XN.

Note added in proof

Since submission of this paper five cases of pure, or almost pure, partial trisomy of 12q24 have been reported.¹⁸⁻²⁰ The many features common to these and to the three cases of pure partial trisomy described above support the suggestion in the concluding paragraph that pure trisomy of this region of chromosome 12 results in an identifiable clinical syndrome.

References

¹⁸ de Muelenaere A, Fryns JP, van den Berghe H. Partial distal 12q trisomy. *Ann Genet (Paris)* 1980;23:251-3.