

Autosomal recessive hydrotic ectodermal dysplasia

SUMMARY First cousins, a male and a female, with a new type of hydrotic ectodermal dysplasia are described. They were each the result of first cousin marriage from the Egyptian Karaite community. They both had partial adontia, conical peg-shaped teeth, fine hair that did not grow long, normal sweating, eversion of lips, and pronounced facial similarity. The male had cleft lip on the right side while the female had a branchial cyst on the left side of the neck. The parents of both the cases were completely normal. The patients had distinct clinical similarity to the condition described by Witkop (1965) as 'Autosomal dominant dysplasia of nails and hypodontia' but the nails were less affected and the mode of inheritance was completely different.

Hypohidrotic ectodermal dysplasia has been reported most often as X-linked recessive but also as autosomal dominant and recessive in different families (Halperin and Curtis, 1942; Perabo *et al.*, 1956; Rossman, 1968; Parant *et al.*, 1969). Hydrotic ectodermal dysplasia has been described as autosomal dominant (Williams and Fraser, 1967) and there are several types of dominant ectodermal dysplasia. An apparently autosomal recessive disease characterized by deafness and nail dystrophy has been described by Feinmesser and Zelig (1961).

The present report deals with an apparently new type of autosomal recessive hydrotic ectodermal dysplasia that has a pronounced clinical similarity to the condition described by Witkop (1965) as, 'autosomal dominant dysplasia of nails and hypodontia', but the nails are less affected and the mode of inheritance is completely different.

Family report

The family belonged to the Egyptian Karaite community in Israel. The community has been previously described (Fried *et al.*, 1968). The family came to our attention because of bilateral incurved thumbs in the newborn sister of the propositus (Fig. 1, IV.7). This anomaly was reported also in a sister of the father (Fig. 1, III.7) and is most probably unrelated to the ectodermal dysplasia. Family history revealed that the propositus (Fig. 1, IV.6) had an unusual type of ectodermal dysplasia. The propositus was the product of a first cousin's marriage and the only other individual with ectodermal dysplasia in the family was a double first and double second cousin of the propositus (Fig. 1, IV.11) who herself was the product of a first cousin marriage. Both sets of parents of the two cases were completely normal and had no hypodontia, nail dygenesis, or fine hair, nor was there any history of such anomaly in previous generations.

Case 1

The propositus (Fig. 1, IV.6) was born after a normal pregnancy on 14 February 1972. The father and mother were 26 and 24 years of age, respectively, at the time of his birth. Right-sided cleft lip was noticed immediately after birth. The birthweight was 3350 g, and the placenta weighed 650 g. The Apgar score was 10 and other malformations were not noticed. The child underwent plastic surgery at the age of 3 months to repair the cleft lip. He had normal development and was

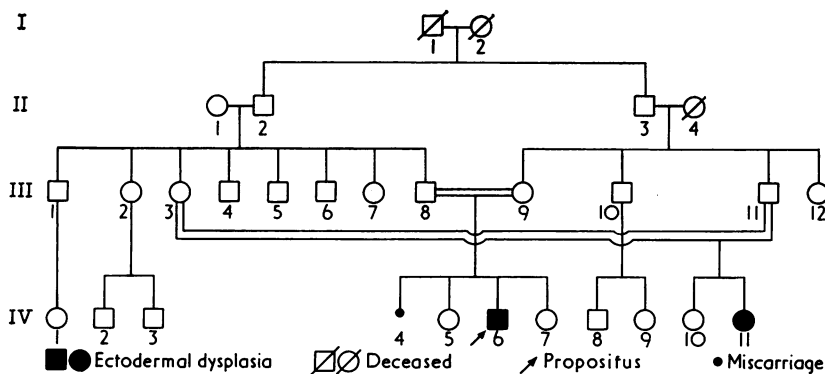


FIG. 1. Family pedigree.

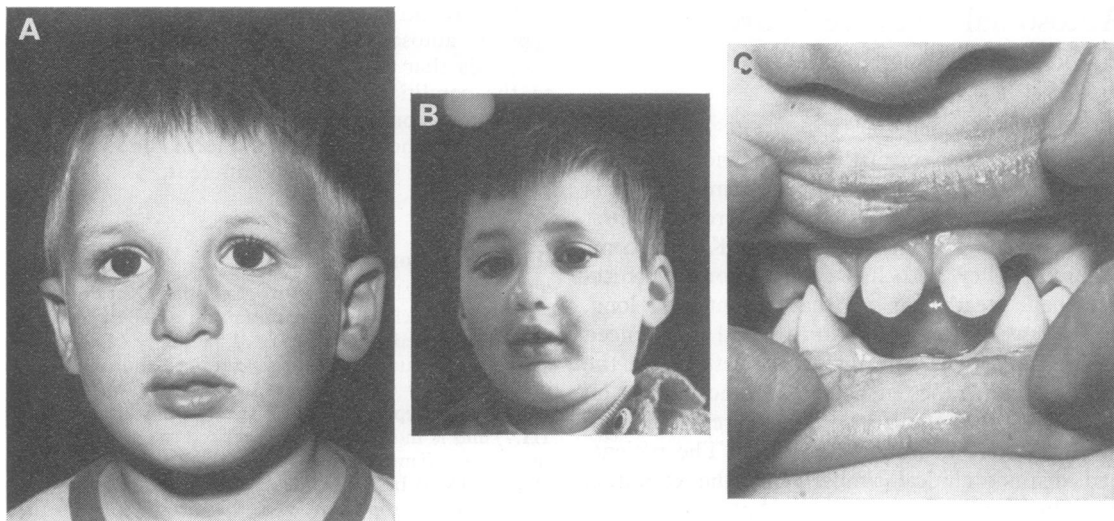


FIG. 2. The propositus and his affected relative. (A) Face of the propositus. Note scar of repaired right cleft lip. (B) Face of affected relative. Note the marked similarity to the propositus. (C) Teeth of the propositus.

considered healthy except for occasional breath-holding attacks. He had a tendency to profuse sweating and at the age of 3 he had only 13 teeth. The parents noted that the hair did not grow long and did not require cutting. On examination at the age of 3 years, the skin was normal and sweating was normal. The periorbital area was of normal colour. There were no wrinkles around the mouth and eyes (Fig. 2). The finger nails were also normal but seemed to be somewhat thin. The toe nails were small, thin, and somewhat concave but they have needed cutting since infancy. The scalp hair was fine and short of dark blond colour. The eyebrows were scanty and of the same colour as the scalp hair. The eyelashes seemed normal and were dark brown in colour. The lips and chin were prominent. On the right side of the upper lip a postoperative scar of the cleft lip operation was noticeable. There was a groove between the lower lip and the chin. The dark brown eyes were moist, with normal lachrymal secretion. There was no photophobia. The oral, nasal, and pharyngeal mucosa were normal. The voice was normal and so was the hearing. The thumbs were not incurved. Sweat pores were noted in normal abundance on dermatoglyphic examination. Electroencephalogram was normal. Intelligence was above average (IQ 129). Microscopical examination of the hair was normal but the hair was of much less than average diameter. On dental examination both lateral incisors as well as the left canine were missing in the upper jaw. In the lower jaw all four incisors were missing (Fig. 2). The teeth were conical.

Case 2

The double first and double second cousin of the propositus (Fig. 1, IV.11) was born after a normal pregnancy in 1971. General physical examination at the age of 4

years was very similar to that of Case 1 and, therefore, the description is not repeated. She had a distinct facial similarity to the propositus (Fig. 2), as they both had eversion of lips and almost identical hair. She had no cleft lip, but she had a branchial cyst on the left side of the neck. On dental examination both lateral incisors were missing in the upper jaw while in the lower jaw only the left lateral incisor was absent. The teeth were conical.

Discussion

This autosomal recessive hidrotic ectodermal dysplasia manifested itself mainly as a dental malformation. The cleft lip of the propositus and the branchial cyst of his affected relative may be either an occasional manifestation of the syndrome or an unrelated chance association. The facial similarity between the two patients may be the result of the syndrome and/or familial. The partial adontia of the first dentition was the most striking and disturbing manifestation. It was thought that a full *x*-ray investigation of the mouth was not justified at this early age so we still do not know to what degree the permanent dentition will be affected. The fine hair that did not grow long and the small thin and slightly concave toe nails did not cause concern and could be missed easily on superficial examination. The apparent absence of previous reports of this syndrome could be explained not only by its rarity but cases could be easily misdiagnosed as only a dental anomaly. The autosomal recessive nature of the disease is attested to by the absence of any

trace of the disease in both sets of parents and in the previous generation, the consanguinity of both sets of parents, and the close relation between them.

K. FRIED

From the Department of Genetics, Asaf Harofe Hospital, Tel-Aviv University Medical School, Zerifin, Israel

References

- Feinmesser, M., and Zelig, S. (1961). Congenital deafness with onychodystrophy. *Archives of Otolaryngology*, **74**, 507–508.
- Fried, K., Landau, J., Cohen, T., and Goldschmidt, E. (1968). Some genetic polymorphic characters of the Karaites community. *Harefuah*, **75**, 507–509.
- Halperin, S. L., and Curtis, G. M. (1942). Anhidrotic ectodermal dysplasia associated with mental deficiency. *American Journal of Mental Deficiency*, **46**, 459–463.
- Parant, M., Cayron, R., and Ragot et Boublil, C. M. (1969). Un cas d'anodontie appartenant à une dysplasie ectodermique avec anhydrose et hypotrichose. *Revue de Stomatologie et de Chirurgie Maxillo-Faciale*, **70**, 46–70.
- Perabo, F., Velasco, J. A., and Prader, A. (1956). Ektodermale dysplasie vom anhidrotischen typus. 5 neue beobachtungen. *Helvetica Paediatrica Acta*, **11**, 604–639.
- Rossman, R. E. (1968). The ectodermal dysplasia. *Cutis*, **4**, 1246–1248.
- Williams, M., and Fraser, F. C. (1967). Hidrotic ectodermal dysplasia—Clouston's family revisited. *Canadian Medical Association Journal*, **96**, 36–38.
- Witkop, C. J., Jr. (1965). Autosomal dominant dysplasia of nails and hypodontia. In *Oral Pathology*, pp. 812–813. Ed. by R. W. Tiecke. McGraw-Hill, New York.

Recessive form of Freeman-Sheldon's syndrome or 'whistling face'¹

SUMMARY Freeman-Sheldon's syndrome is a rare genetic disease inherited as an autosomal dominant trait in some families but showing sporadic appearance in the majority of the reported cases. In the present paper we report a family having two affected children born from normal consanguineous parents suggesting that Freeman-Sheldon's syndrome may be heterogeneous from the genetic point of view.

Freeman-Sheldon's syndrome is a rare condition first described in 1938, and mainly characterized by the features of whistling face. Up to 1970 there were 9 cases reported in the world literature, in which familial occurrence of the syndrome was observed in 3 instances, all these families being in concord-

ance for an autosomal dominant type of inheritance (Fraser *et al.*, 1970). In the present paper we report 2 affected sibs born from consanguineous normal parents.

Case reports

Case 1 IV. 1, an 11-year-old boy, the first child of a young mother was born at term by normal delivery after an uneventful pregnancy. Bilateral clubfoot was noticed at birth which required orthopaedic care from the age of 15 days. A few months after birth abnormalities in the mouth and chin were noticed. The boy had normal growth and normal mental development.

Clinical examination showed a bright white boy, weight 30.4 kg, height 132 cm, and an US/LS index of 0.80. The face was round, and masklike, with full cheeks. There was flattening of the supra orbital ridges, moderate blepharophimosis, bilateral ptosis of eyelids, and antimongoloid palpebral fissures (Fig. 1). The nose was 'parrotlike': it was heavily curved, with the nostrils elongated upwards suggesting colobomata. The philtrum was increased in length. The mouth opening was small, and the lips were constantly contracted as if the patient were whistling. The palate was high. The skin over the chin was normal in aspect but it was covering an irregular surface resembling dimples. The hands were normal. The feet had talipes valgus. The genitalia were normal except for a first degree hypospadias.

Laboratory examination showed normal electrocardiogram, electroencephalogram, and audiometry. Electromyography showed paroxysmal spasms of the buccinators muscles. The x-ray films showed a small frontal bone compared with the skull size, hypoplasia of vertebral bodies C-3, C-4, and C-5, spina bifida occulta in C-6, and scoliosis of the lumbar spine. Fingerprint analyses were normal.

Case 2. (IV. 2) a 7-year-old girl, sister of Case 1, was also born at term by normal delivery after an uneventful pregnancy. The mouth anomalies were noticed at birth. Talipes valgus was noticed at the age of 2 years. There was normal physical and mental development after birth.

Clinical examination showed an intelligent white girl, weight 23.0 kg, height 120 cm, span 117 cm, and an US/LS index of 0.93. The face was round, moderately masklike, with full cheeks. The supraorbital ridges were flat and the palpebral fissures were antimongoloid. The nose was curved (Fig. 1). The philtrum was long and the mouth-opening was small. The upper lip was protruding, the lower lip contracted in the whistling manner. The palate was

¹This work was supported by CNPq, 5613/75 (SIP/04–920) and OEA.