Editor's choice
Scan to access more
free content

ORIGINAL ARTICLE

Comprehensive molecular diagnosis of 179 Leber congenital amaurosis and juvenile retinitis pigmentosa patients by targeted next generation sequencing

Xia Wang,[1,2] Hui Wang,[1,2] Vincent Sun,[3] Han-Fang Tuan,[1] Vafa Keser,[3] Keqing Wang,[2] Huanan Ren,[3] Irma Lopez,[3] Jacques E Zaneveld,[1,2] Sorath Siddiqui,[3] Stephanie Bowles,[1] Ayesha Khan,[3] Jason Salvo,[1,4] Samuel G Jacobson,[5] Alessandro Iannaccone,[6] Feng Wang,[1,2] David Birch,[7] John R Heckenlively,[8] Gerald A Fishman,[9] Elias I Traboulsi,[10] Yumei Li,[1,2] Dianna Wheaton,[7] Robert K Koenekoop,[3] Rui Chen[1,2,4,11]

For numbered affiliations see end of article.

Correspondence to
Dr Rui Chen, Human Genome Sequencing Center, One Baylor Plaza, Houston, Texas, US, 77054, ruichen@bcm.edu
Dr Robert K Koenekoop, McGill Ocular Genetics Laboratory, Montreal Children's Hospital, McGill University Health Centre, 2300 Tupper, Montreal, Quebec
H3H 1P3 Canada, robkoenekoop@hotmail.com

XW and HW contributed equally to this study.

Received 28 January 2013
Revised 20 May 2013
Accepted 13 June 2013
Published Online First
11 July 2013

To cite: Wang X, Wang H, Sun V, *et al*. *J Med Genet* 2013;**50**:674–688.

ABSTRACT

Background Leber congenital amaurosis (LCA) and juvenile retinitis pigmentosa (RP) are inherited retinal diseases that cause early onset severe visual impairment. An accurate molecular diagnosis can refine the clinical diagnosis and allow gene specific treatments.

Methods We developed a capture panel that enriches the exonic DNA of 163 known retinal disease genes. Using this panel, we performed targeted next generation sequencing (NGS) for a large cohort of 179 unrelated and prescreened patients with the clinical diagnosis of LCA or juvenile RP. Systematic NGS data analysis, Sanger sequencing validation, and segregation analysis were utilised to identify the pathogenic mutations. Patients were revisited to examine the potential phenotypic ambiguity at the time of initial diagnosis.

Results Pathogenic mutations for 72 patients (40%) were identified, including 45 novel mutations. Of these 72 patients, 58 carried mutations in known LCA or juvenile RP genes and exhibited corresponding phenotypes, while 14 carried mutations in retinal disease genes that were not consistent with their initial clinical diagnosis. We revisited patients in the latter case and found that homozygous mutations in *PRPH2* can cause LCA/juvenile RP. Guided by the molecular diagnosis, we reclassified the clinical diagnosis in two patients.

Conclusions We have identified a novel gene and a large number of novel mutations that are associated with LCA/juvenile RP. Our results highlight the importance of molecular diagnosis as an integral part of clinical diagnosis.

INTRODUCTION

Leber congenital amaurosis (LCA) refers to a group of inherited retinal dystrophies that share the common feature of severe visual impairment within the first year of life. Clinically, LCA is defined by congenital blindness, congenital nystagmus, and lack of detectable signals on an electroretinogram (ERG).[1 2] LCA affects 1 in every 50 000 individuals, but it accounts for 5% of all retinal dystrophies and 20% of blindness in school age children.[3 4] To date, mutations in 19 genes are reported to cause LCA.[5–12] Despite the breadth of current knowledge, genetic defects in about 30% of LCA cases remain unknown.[11]

The clinical phenotypes and genetic causes of LCA and juvenile retinitis pigmentosa (RP) largely overlap. Both diseases belong to a spectrum of retinal diseases termed early onset retinal dystrophies (EORD). In fact, LCA was initially considered to be a congenital form of RP.[2] Compared with LCA, juvenile RP tends to have milder phenotypes and a later onset. Juvenile RP patients appear to have better visual function at birth than those with LCA, and later develop night blindness, narrowed visual fields, and eventually severe vision impairment. Mutations in several known LCA genes, such as *CRB1* and *RDH12*, are reported to cause juvenile RP.[13] Interestingly, mutations in other retinal disease genes, such as *IQCB1* and *KCNJ13*, are also known to be associated with LCA or 'LCA-like' phenotypes.[10 11] These observations may be explained by a combination of allelic differences, genetic background, and environmental modifications. Also, it has been demonstrated that the clinical phenotypes of many retinal diseases overlap with that of LCA.[11] It is likely that in some cases visual impairment is the most obvious phenotype in the initial evaluation, and that other syndromic features appear at a later time. Therefore, given the limited evaluation possible in infants and in early childhood, some patients initially diagnosed with LCA may actually have a different retinal disorder, such as Alström syndrome or Joubert syndrome.[11] Despite these observations, systematic screening for mutations in all known retinal disease genes on a large LCA patient cohort has not yet been reported.

Because of the genetic heterogeneity of LCA and other retinal diseases, an accurate molecular diagnosis can improve the clinical diagnosis, facilitate a more accurate description of prognosis, and allow gene specific treatment. One of the most common methods for molecular diagnosis of LCA is the

Arrayed Primer Extension (APEX) chip (Asper Ophthalmics). It is a microarray based genotyping method that tests a subset of known mutations in known LCA genes, leading to molecular diagnosis in approximately 17–32% of LCA patients.[14–16] With additional mutations added to the LCA APEX array, the estimated solving rate has been improved to about 50%.[11] On the other hand, next generation sequencing (NGS) has been recently used for the molecular diagnosis of retinal diseases.[17 18] Compared with the APEX chip, the NGS based approach is able to discover novel variants and genes. Recently, Coppieters and others described a workflow to screen the exons of known LCA genes, using amplicon PCR followed by NGS.[19] However, this workflow was tested on a relatively small LCA patient cohort and did not cover other retinal disease genes.

The goal of this study was to develop a comprehensive molecular diagnostic method for LCA and potentially for other retinal diseases. For this purpose, we developed a targeted NGS method that allows us to systematically screen the exons of most known retinal disease genes at low cost (163 genes at the time of design, online supplementary files 1 and 2). We first evaluated this method on a standard control sample, and then applied it to the molecular diagnosis of a large cohort of unrelated and prescreened patients with the clinical diagnosis of either LCA or juvenile RP (n=179). Pathogenic mutations for 72 patients were identified by systematic NGS data analysis, Sanger sequencing validation, and segregation analysis. These 72 patients were classified into different confidence groups based on the clinical significance of their mutations. Among the 72 patients, 58 carried mutations in known LCA or juvenile RP genes and exhibited corresponding phenotypes, while 14 carried mutations in retinal disease genes that were not consistent with their initial clinical diagnosis. Guided by the molecular diagnosis, we revisited 12 out of the 14 patients. We found that homozygous mutations in *PRPH2* can cause LCA/juvenile RP. We also reclassified or refined the initial clinical diagnosis for 10 patients.

METHODS

Study subjects

We initially collected a cohort of 389 patients from around the world and with a variety of backgrounds. Using a combination of LCA APEX array, Sanger sequencing, homozygosity mapping, and phenotype directed genotyping methods (eg, preserved para-arteriolar retinal pigment epithelium in an LCA patient is associated with mutations in *CRB1*), we had previously identified the genetic causes for 210 patients (most of whom are LCA patients).[13 20] The remaining 179 patients were included in this study. The available prescreening information for the 179 patients is listed in online supplementary table S5.

The 179 patients were seen at McGill University (RKK), University of Pennsylvania (SGJ), The Lighthouse of Chicago (GAF), University of Tennessee Health Science Center (AI), and University of Michigan (JRH), by ophthalmologists with expertise in retinal dystrophies. Informed consents and research protocols were approved by the respective institutional review boards or research ethics board and adhered to the tenets of the Declaration of Helsinki. Complete histories, pedigree analysis, and ophthalmic examinations were performed. Eye exams consisted of cycloplegic refractions, fixation testing, Snellen visual acuities (when possible), pupillary responses, slit lamp exams, dilated fundus exam by indirect ophthalmoscopy, retinal photography, and Goldmann visual field testing (when possible). In most cases, ERGs were done according to ISCEV (International Society for Clinical Electrophysiology of Vision) standards. LCA is defined by the phenotypes mentioned in the introduction and the absence of overt systemic features. Juvenile RP represents a milder disease with later onset of signs and symptoms. In juvenile RP patients, vision can appear normal at birth, and the first symptom is progressive night blindness, with progressive visual loss at around age 2 years, with or without nystagmus.

DNA was extracted from whole blood using the FlexiGene kit or the QIAamp DNA blood kit according to the manufacturer's protocol. The quantity and quality of DNA were verified by using NanoDrop.

Target DNA capture and NGS experiments

According to the manufacturer's protocol, Illumina paired-end libraries were generated. Briefly, ∼1 μg of genomic DNA was sheared into fragments of approximately 300–500 bp. The DNA fragments were end-repaired and an extra 'adenine' base was added to the 3′ end. Illumina Y-shape index adapters were ligated to the ends of the DNA fragments and eight cycles of PCR amplification were applied to each sample after ligation. The DNA libraries were quantified by the PicoGreen assay (Invitrogen). For each capture reaction, 24 to 48 libraries (3 μg of DNA in total) were pooled together. A design file (see online supplementary files 1 and 2) was submitted to Nimblegen for the design of the capture probe. NimbleGen SeqCap EZ Hybridisation and Wash Kits were used for the washing and recovery of captured DNA. Captured libraries were quantified and sequenced on the Illumina HiSeq 2000 as 100 bp paired-end reads, following the manufacturer's protocols. Illumina sequencing was performed at the BCM-FGI core.

Evaluation of our method's sensitivity to detect SNPs on the Hapmap sample

Single nucleotide polymorphisms (SNPs) genotyping data of HapMap sample NA11831 were downloaded from 1000 Genome omni database (ftp://ftp-trace.ncbi.nih.gov/1000genomes/ftp/technical/working/20110527_bi_omni_1525_v2_genotypes/). This sample had been genotyped using the Illumina OMNI2.5 SNP genotyping array. A total of 1190 genotyped single nucleotide polymorphisms (SNPs) in this sample are within our design region, including 919 homozygous reference SNPs, 107 homozygous alternative SNPs, and 164 heterozygous alternative SNPs. A total of 1184 SNPs were detected by our targeted NGS method. Among the detected SNPs, 1183 out of 1184 had the same genotype between the SNP array and NGS. The single disconcordant SNP rs3763073 was heterozygous C/T on the SNP array but homozygous C/C in targeted NGS. To resolve the conflict, we performed direct Sanger sequencing and confirmed that rs3763073 was indeed homozygous for the reference C, indicating that NGS detected the SNP correctly (data not shown).

Data analysis

Sequencing reads were aligned to the human genome reference version hg19 using Burrows-Wheeler Aligner (BWA).[21] Base quality recalibration and local realignment were performed using the Genome Analysis Toolkit (GATK).[22] AtlasSNP was used for SNP calling and AtlasIndel2 was used for indel calling.[23] The 1000 genome database, dbSNP, ESP5400, NIEHS95 exomes, and our internal database were used to filter out common SNPs and indels, with allele frequency cutoffs at 0.5% for recessive variants and at 0.1% for dominant variants (Exome Variant Server, NHLBI GO Exome Sequencing Project (ESP), Seattle, Washington (http://evs.gs.washington.edu/EVS/), NIEHS Environmental Genome Project, Seattle, Washington (http://evs.gs.washington.edu/niehsExome/).[24 25] Variant annotation was performed using

ANNOVAR.[26] The Refseq gene sequences below were used for the mutation coordinates: *AIPL1*:NM_014336, *ALMS1*:NM_015120, *BBS1*:NM_024649, *BBS7*:NM_018190, *CEP290*:NM_025114, *CERKL*:NM_001160277, *CLN3*:NM_001042432, *CRB1*:NM_201253, *GUCY2D*:NM_000180, *INPP5E*:NM_019892, *IQCB1*:NM_001023570, *LCA5*:NM_181714, *LRAT*:NM_004744, *NR2E3*: NM_016346, *OTX2*:NM_172337, *PDE6A*:NM_000440, *PRPF31*:NM_015629, *RDH12*:NM_152443, *RPE65*:NM_000329, *RPGR*: NM_000328, *RPGRIP1*:NM_020366, *SAG*:NM_000541, *SNRNP200*:NM_014014, *SPATA7*:NM_018418, *TULP1*:NM_003322. The pathogenicity of novel missense mutations was predicted by dbNSFP, whose prediction score is derived from five algorithms (SIFT, Polyphen2, LRT, MutationTaster, and PhyloP).[27–32]

PCR and direct Sanger sequencing

To validate the mutations detected by NGS, primers were designed (Primer3, http://biotools.umassmed.edu/bioapps/primer3_www.cgi) to PCR-amplify the 400–500 bp region flanking the mutation. To ensure the high quality of Sanger sequencing, the amplicon was designed to have a boundary at least 50 bp away from the mutation. The amplicon was then Sanger sequenced on Applied BioSystems (ABI) 3730×l capillary sequencer. The Sanger sequencing results were analysed with Sequencher software. The intronic mutation c.2991+1655A>G in *CEP290* was not initially included in the original design of our exonic capture panel. Sanger sequencing of this mutation was performed and the results were combined with the NGS data.

RESULTS

A cohort of 179 patients clinically diagnosed with LCA or juvenile RP

After prescreening for known mutations in LCA and juvenile RP genes using a combination of conventional genotyping methods, the genetic defects in 173 LCA and six juvenile RP patients remained unexplained (see online supplementary table S1 and Methods). We hypothesised that a portion of these cases were caused by mutations in known LCA and juvenile RP genes that were not included in the conventional screening methods, or caused by mutations in other retinal disease genes that had not been previously associated with LCA or juvenile RP. To Sanger-sequence all known retinal disease genes for such a large sample set would be prohibitively expensive and time consuming. Therefore, we utilised a targeted NGS based method for the comprehensive molecular diagnosis of these patients.

Targeted NGS of a standard control sample from HapMap project

A capture panel was designed to enrich the target DNA, which consisted of 649 804 bp covering 2560 exons in 163 known retinal disease genes that had been reported and recorded in the RetNet at the time of design (see online supplementary files 1 and 2, https://sph.uth.tmc.edu/retnet/). The enriched DNA was then sent for NGS.

We first evaluated the coverage of our targeted NGS method on NA11831, a standard control sample from the original HapMap Centre d'Etude du Polymorphisme Humain (CEPH) cohort.[33] DNA from NA11831 was captured and sequenced at high coverage. A total of 8 240 805 mappable reads were obtained, 39% of which mapped to the target region and resulted in a 234× mean per base coverage. As shown in figure 1A and B, the vast majority of the targeted regions were well covered. Indeed, 97% of the bases in target region had coverage >10× and 92% of the bases had coverage >50× (figure 1A). Also, 98% of the 2560 exons had mean coverage >5× (figure 1B). The low coverage exons were either within duplicate regions or those with a high GC content (see online supplementary tables S2 and S3).

To systematically evaluate the accuracy of our method, we compared the genotyping data obtained from NGS to that from the SNP array. As part of the 1000 Genome project, sample NA11831 had been genotyped using the Illumina OMNI2.5 genotyping array. A total of 1190 genotyped SNPs in this sample were within our design region and were used as standards to test the accuracy of our method. As a result, 99.5% of SNPs (1184/1190) were detected by NGS (minimum coverage=3). The six undetected SNPs were within low coverage exons (data not shown). The genotypes of all 1184 NGS SNP calls were validated by either SNP array or Sanger sequencing (see Methods). Therefore, high quality SNP genotyping results were obtained by targeted NGS with a sensitivity of 99.5% (1184/1190) and a genotype concordance of 100% (1184/1184).

To further explore the effect of coverage on the sensitivity of SNP detection, sequencing reads generated from NA11831 were randomly sampled in silico to achieve different levels of coverage from 3× to 234×. As shown in figure 1C, sensitivity increased sharply from 38% to 96% as the coverage increased from 2× to 12×, then gradually reached a sensitivity of 99% at around 23×. Based on this result, we chose to sequence patient samples at around 50× coverage to achieve nearly saturated sensitivity with a relatively low cost (cost is linear to the depth of coverage). At 50× coverage, up to 100 samples could be sequenced in one lane of Illumina HiSeq 2000. To develop a more cost effective method, we tested the robustness of sample multiplexing. We molecularly barcoded 12 replicates of NA11831 DNA and performed targeted NGS for these 12 replicates in one capture reaction. As shown in figure 1D, uniform and high coverage of these replicates was achieved.

Targeted NGS of 179 patients

Using the capture panel described above, we applied targeted NGS to DNA obtained from a large cohort of 179 unrelated patients with the diagnosis of LCA or juvenile RP. The sequencing reads were processed by our bioinformatics pipeline that performed reads alignment, recalibration, realignment, variants calling, filtering, annotation, and quality control (see Methods). An average of 62× coverage was achieved for the 179 patient samples. Within the design region, 84% of bases had coverage >10× and 70% of bases had coverage >20×, indicating that sufficient coverage was achieved for high sensitivity of variants detection (table 1, figure 2A). For each individual, about 407 SNPs and small insertions/deletions (indels) were identified. Since LCA and juvenile RP are rare Mendelian diseases, common variants with a frequency >0.5% (for recessive variants) or >0.1% (for dominant variants) in any of the following databases were filtered out: the 1000 genome database, dbSNP135, the ESP5400 database, the NIEHS 95 exomes database, and our internal database (see Methods). As a result, an average of eight rare variants in retinal disease genes that lead to protein coding change were identified per sample (table 1). Furthermore, mutations known to cause retinal diseases in the Human Gene Mutation Database (HGMD) or the primary literature were identified.[34] Finally, dbNSFP, a program that compiles prediction score from five well established prediction algorithms (PhyloP, SIFT, Polyphen2, LRT, and MutationTaster), was used to predict the pathogenicity of novel missense changes.[27–32] In this study, we only reported novel missense variants that are predicted to be pathogenic by at least three of the

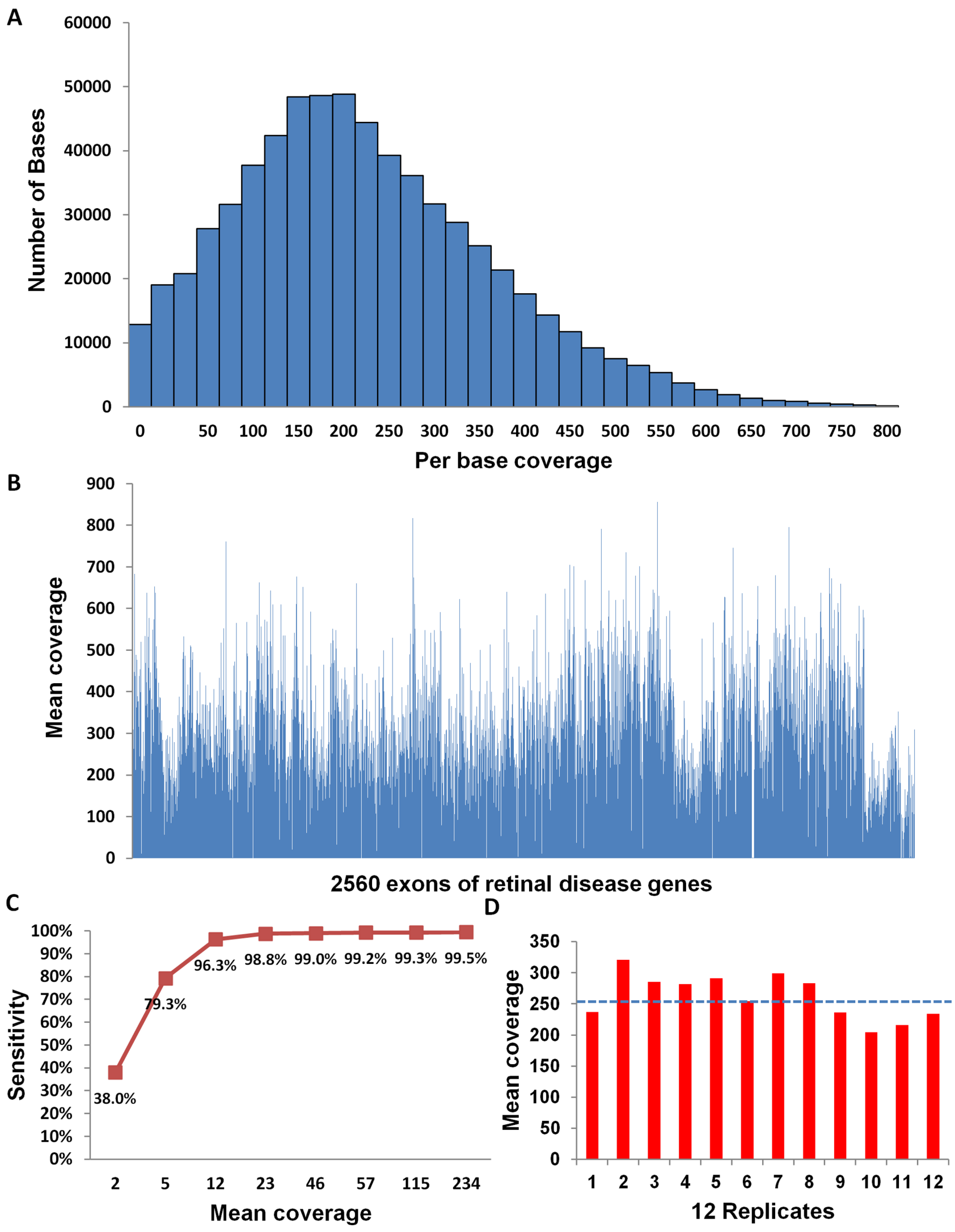

Figure 1 Systematic evaluation of targeted next generation sequencing method on a Hapmap sample NA11831. (A) The number of bases within different coverage groups. (B) The mean coverage of 2560 exons in the design region. (C) The sensitivity to detect single nucleotide polymorphisms versus the according mean coverage. (D) The high and uniform mean coverage for 12 multiplexed replicates. The blue dot line represents the average coverage for 12 replicates.

five algorithms (see online supplementary table S4). After all these stringent filtering steps, the remaining variants are likely to cause the disease in patients.

Identification of pathogenic mutations

To identify the potential pathogenic mutations among several rare variants in each patient, we looked for variants that matched the reported inheritance pattern of the respective genes:

1. Homozygous or compound heterozygous variants in recessive retinal disease genes, or
2. Reported heterozygous variants known to cause dominant retinal diseases, or
3. Novel heterozygous loss-of-function (LOF) variants in dominant retinal disease genes, if heterozygous LOF mutations in those genes are previously known to cause dominant retinal diseases.

All potential pathogenic variants identified above were validated by Sanger sequencing. Segregation analysis was performed if DNA from family members was available. Through this procedure, we identified pathogenic mutations for 72 out of 179 patients (40%). Among the 72 patients, 58 patients carried mutations in known LCA or juvenile RP genes and exhibited corresponding phenotypes, while 14 harboured mutations in retinal disease genes that were not consistent with their initial clinical diagnosis (figure 2B). A total of 83 distinct pathogenic mutations were identified in the 72 patients, including a large number of novel mutations (n=45) (table 2). Most of these mutations were missense (39%) and nonsense (35%) mutations (figure 2C).

Table 1 Target NGS statistics for 179 patients

Per base coverage	62
% Target bp covered ≥1×	97
% Target bp covered ≥10×	84
% Target bp covered ≥20×	70
Total number of variants (SNPs and indels)	407
Rare variants	24
Rare variants that lead to protein coding change:	8.23
Missense change	3.81
Nonsense change	0.28
Splicing site change	0.15
Non-frameshift indels	1.56
Frameshift indels	2.46

All the values are the mean number derived from 179 patients.
NGS, next generation sequencing; SNPs, single nucleotide polymorphisms.

Molecular diagnosis of patients

Patients carrying mutations in known LCA or juvenile RP genes

In total, we identified 58 patients who carried mutations in known LCA or juvenile RP genes and exhibited corresponding

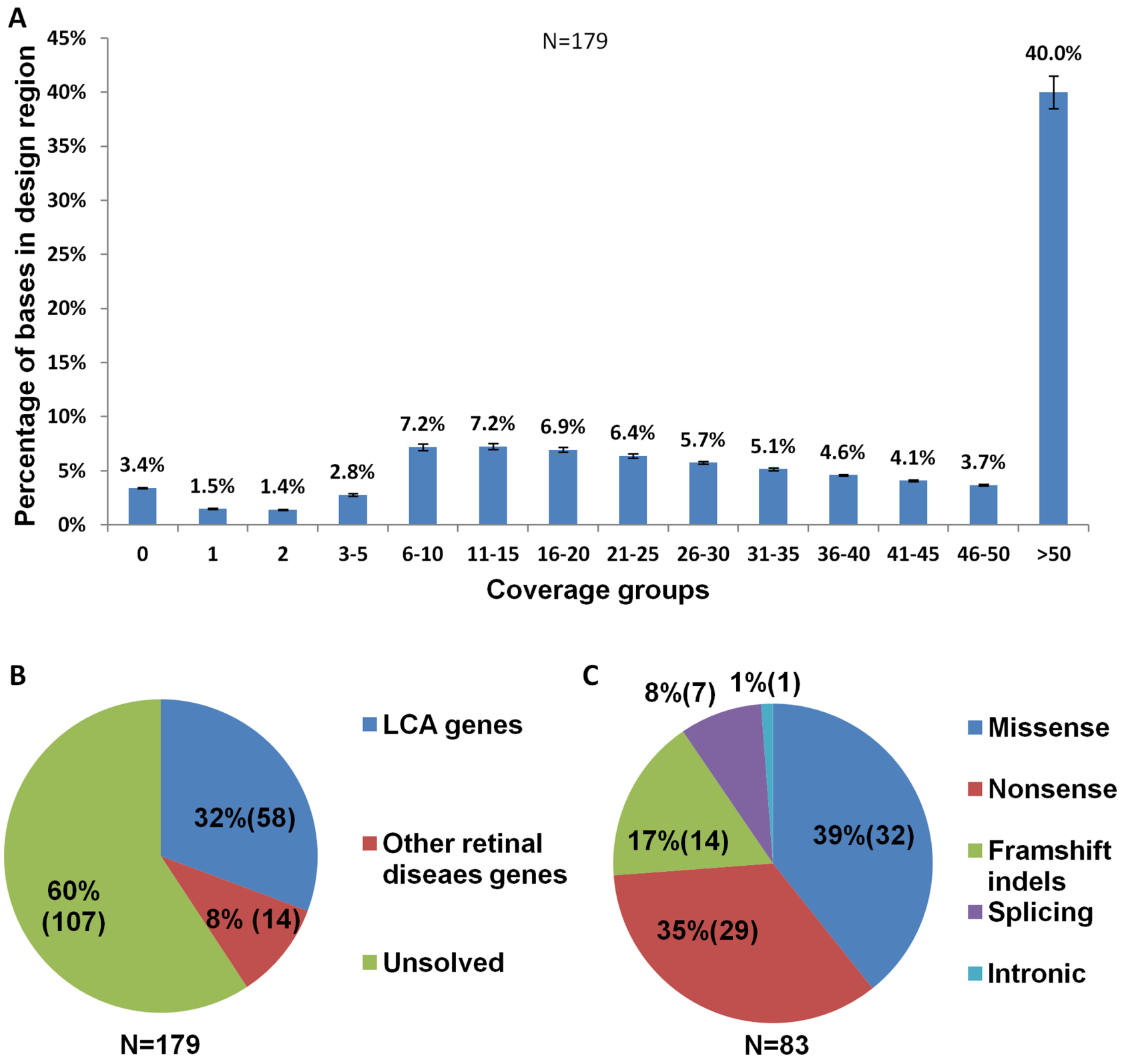

Figure 2 The targeted next generation sequencing statistics for 179 patients. (A) The percentage of bases in design region in each coverage group for 179 patients. (B) The percentage of 179 patients in different categories. (C) The percentage of different types of pathogenic mutations identified in the 72 patients. LCA, Leber congenital amaurosis.

phenotypes (tables 4–6). According to the American College of Medical Genetics standards to report sequence variants, mutations identified in our study can be classified into three categories with different clinical significance: (1) reported mutations that are known to cause retinal diseases; (2) novel LOF mutations that are expected to cause retinal diseases; (3) novel missense mutations that are predicted to be pathogenic by in silico prediction algorithms and may be causative of retinal diseases (see online supplementary table S4).[35] To demonstrate the different confidence levels for different patients, we classified these patients into three groups based on the clinical significance of their mutations: patients in group 1 and 2 carried reported or novel LOF mutations with higher confidence, while patients in group 3 harboured one or more novel missense mutations with lower confidence (table 3).

We identified 26 patients in group 1 who carried homozygous or compound heterozygous mutations that were known to cause recessive LCA or juvenile RP (tables 3 and 4, online supplementary table S1). For example, patient 3916 carried compound heterozygous reported nonsense mutations c.582C>G (p.Y194X) and frameshift deletion c.805_809del (p.A269GfsX2) in *RDH12* (table 4). The patient exhibited LCA phenotypes and the two mutations were previously known to cause LCA (see online supplementary figure S1, table S1).[36 37]

Table 2 Number of pathogenic mutations identified in this study

	Reported	Novel	Total
LCA and juvenile RP genes	30	38	68
Retinal disease genes inconsistent with initial diagnosis	8	7	15
Total	38	45	83

LCA, Leber congenital amaurosis; RP, retinitis pigmentosa.

In this group of patients, *AIPL1* was the most frequently mutated gene, which appeared in five patients. The nonsense mutation c.834G>A (p.W278X) in *AIPL1*, the intronic mutation c.2991+1655A>G in *CEP290*, and the frameshift insertion c.805_809del (p.A269GfsX2) in *RDH12* were the most frequent mutations, all carried by three patients.

We identified 22 patients in group 2 who carried novel LOF mutations in known LCA or juvenile RP genes (tables 3 and 5). First, 13 patients carried homozygous or compound heterozygous novel LOF mutations. For example, a novel homozygous frameshift deletion c.613_614del (p.S205YfsX27) was identified in exon3 of *LRAT* in patient 4019. To our knowledge, this is the first reported disease allele outside *LRAT* exon2.[48 51–53] The c.613_614del is predicted to change the 205–230 amino acids in the C terminus of *LRAT* protein, which is thought to be important for the *LRAT* protein enzymatic activity and its localisation to the endoplasmic reticulum membrane.[54 55] Second, eight patients carried one reported mutation plus one novel LOF mutation. Third, patient 3561 carried a novel heterozygous frameshift insertion in *OTX2*. This insertion is likely to be pathogenic because a heterozygous protein truncating mutation in *OTX2* was previously reported to cause ocular malformation and LCA.[56] In this group of patients, *CEP290* was the most frequently mutated gene, which appeared in seven patients.

We identified 10 patients in group 3 who carried one or more novel missense mutations in known LCA or juvenile RP genes (table 6). Specifically, four patients carried homozygous or compound heterozygous novel missense mutations, three patients had a novel missense mutation plus a reported mutation, and three patients had a novel missense plus a novel LOF mutation (table 3). For example, patient 3319 carried a homozygous novel missense mutation (c.1439G>C, p.C480S) in *CRB1* that changes a cysteine to a serine. The cysteine is conserved across mammals and this mutation is predicted to be damaging to protein function/structure by in silico

Table 3 Classification of patients according to clinical significance of mutations

Mutated genes	Group	Allele 1	Allele 2	Homo	Compound hetero	Hetero	Total
LCA/juvenile RP genes	1	Reported	Reported	15	11		26
	2	Novel LOF	Novel LOF	8	5		13
		Novel LOF	Reported		8		8
		Novel LOF				1	1
	3	Novel missense	Novel missense	2	2		4
		Novel missense	Reported		3		3
		Novel missense	Novel LOF		3		3
Retinal disease genes inconsistent with initial diagnosis	1	Reported	Reported	7			7
		Reported				1	1
	2	Novel LOF	Novel LOF	1*	1		2
	3	Novel missense	Novel missense	4			4
Total				37	33	2	72

The numbers in the four columns on the right represent the number of patients in each category.
*This patient carried a hemizygous mutation.
Compound hetero, compound heterozygous; Hetero, Heterozygous; Homo, homozygous; LCA, Leber congenital amaurosis; RP, retinitis pigmentosa.

prediction (see online supplementary table S4). Interestingly, similar missense mutations p.C480R and p.C480G at this residue were reported to cause LCA, further supporting the pathogenicity of p.C480S.[43] In this group of patients, *GUCY2D* was the most frequently mutated gene, which appeared in four patients.

Table 4 Twenty-six patients carrying two reported mutations in LCA or juvenile RP genes

Patient ID	Disease presentation	Gene	Type	Mutations
1473	LCA	*AIPL1*	Homozygous	c.834G>A, p.W278X[38]
3745	LCA	*AIPL1*	Compound Heterozygous	c.834G>A, p.W278X[38] c.547G>T, p.G183X[4]
3746	LCA	*AIPL1*	Compound Heterozygous	c.834G>A, p.W278X[38] c.547G>T, p.G183X[4]
393	LCA	*AIPL1*	Homozygous	c.487C>T, p.Q163X[39]
3754	LCA	*AIPL1*	Compound Heterozygous	c.265T>C, p.C89R[15] c.214T>C, p.W72R[4]
3638	LCA	*CEP290*	Homozygous	c.2991+1655A>G[40]
3656	LCA	*CEP290*	Compound Heterozygous	c.5668G>T, p.G1890X[41] c.2991+1655A>G[40]
3661	LCA	*CEP290*	Homozygous	c.2991+1655A>G[40]
3793	LCA	*CEP290*	Homozygous	c.4723A>T, p.K1575X[42]
398	LCA	*CRB1*	Homozygous	c.610_616del, p.I205DfsX133[43]
3738	LCA	*CRB1*	Compound Heterozygous	c.1438T>C, p.C480R[43] c.2945C>A, p.T982K[4]
1251	LCA	*CRB1*	Homozygous	c.3996C>A, p.C1332X[43]
3722	LCA	*GUCY2D*	Compound Heterozygous	c.1343C>A, p.S448X[44] c.2598G>C, p.K866N[45]
3778	LCA	*GUCY2D*	Homozygous	c.1343C>A, p.S448X[44]
3750	LCA	*GUCY2D*	Compound Heterozygous	c.2302C>T, p.R768W[46] c.3271C>T, p.R1091X[4]
3577	LCA	*LCA5*	Homozygous	c.835C>T, p.Q279X[47]
54	LCA	*LRAT*	Homozygous	c.217_218del, p.M73DfsX48[48]
622	LCA	*RDH12*	Compound Heterozygous	c.146C>T, p.T49M[37] c.805_809del, p.A269GfsX2[37]
1256	LCA	*RDH12*	Compound Heterozygous	c.146C>T, p.T49M[37] c.805_809del, p.A269GfsX2[37]
1278	Juvenile RP	*RDH12*	Homozygous	c.164C>T, p.T55M[36]
3916	LCA	*RDH12*	Compound Heterozygous	c.582C>G, p.Y194X[36] c.805_809del, p.A269GfsX2[37]
3784	LCA	*RPE65*	Compound Heterozygous	c.1205G>A, p.W402X[4] c.1022T>C, p.L341S[49]
1259	LCA	*SPATA7*	Homozygous	c.322C>T, p.R108X[9]
1303	LCA	*TULP1*	Homozygous	c.1381C>G, p.L461V[13]
3670	LCA	*TULP1*	Homozygous	c.901C>T, p.Q301X[50]
3671	LCA	*TULP1*	Homozygous	c.901C>T, p.Q301X[50]

LCA, Leber congenital amaurosis; RP, retinitis pigmentosa.

Table 5 Twenty-two patients carrying novel LOF mutations in LCA or juvenile RP genes

Patient ID	Disease presentation	Gene	Type	Mutations
3739	LCA	*CEP290*	Compound Heterozygous	c.5344C>T, p.R1782X c.1667_1668insA, p.I556NfsX20
3640	LCA	*CEP290*	Compound Heterozygous	c.1260_1264del, p.K421GfsX2 c.2991+1655A>G[40]
3645	LCA	*CEP290*	Compound Heterozygous	c.3811C>T, p.R1271X c.2991+1655A>G[40]
3650	LCA	*CEP290*	Compound Heterozygous	c.547_550del, p.Y183RfsX4 c.2991+1655A>G[40]
3653	LCA	*CEP290*	Compound Heterozygous	c.4882C>T, p.Q1628X c.2991+1655A>G[40]
3666	LCA	*CEP290*	Compound Heterozygous	c.1219_1220del, p.M407EfsX14 c.2991+1655A>G[40]
3741	LCA	*CEP290*	Compound Heterozygous	c.4723A>T, p.K1575X[42] c.2052+1_2052+2del
418	LCA	*CRB1*	Homozygous	c.984G>A, p.W328X
3557	LCA	*CRB1*	Homozygous	c.3687C>A, p.C1229X
1413	LCA	*GUCY2D*	Homozygous	c.1116G>A, p.W372X
3796	LCA	*IQCB1*	Compound Heterozygous	c.1518_1519del, p.H506QfsX13[57] c.1381C>T, p.R461X
3752	LCA	*IQCB1*	Compound Heterozygous	c.1518_1519del, p.H506QfsX13[57] c.1465C>T, p.R489X
3737	LCA	*IQCB1*	Compound Heterozygous	c.1465C>T, p.R489X c.1381C>T, p.R461X
4019	LCA	*LRAT*	Homozygous	c.613_614del, p.S205YfsX27
3561	LCA	*OTX2*	Heterozygous	c.543_544insCTCA, p.Q181HfsX7
1842	Juvenile RP	*PDE6A*	Homozygous	c.205C>T, p.Q69X
3676	LCA	*RPGRIP1*	Compound Heterozygous	c.1083_1084insGA, p.V364EfsX12 c.3749–1G>T
3677	LCA	*RPGRIP1*	Compound Heterozygous	c.1083_1084insGA, p.V364EfsX12 c.3749–1G>T
1315	LCA	*SPATA7*	Homozygous	c.1216–1G>A
3679	LCA	*SPATA7*	Homozygous	c.1373del, p.V458EfsX48
3757	LCA	*TULP1*	Compound Heterozygous	c.1376_1377del, p.I459RfsX12 c.725_728del, p.P242QfsX16
1271	LCA	*TULP1*	Homozygous	c.1113–2A>C

LCA, Leber congenital amaurosis; LOF, loss-of-function; RP, retinitis pigmentosa.

Table 6 Ten patients carrying one or more novel missense mutations in LCA or juvenile RP genes

Patient ID	Disease presentation	Gene	Type	Mutations
3319	LCA	*CRB1*	Homozygous	c.1439G>C, p.C480S
3611	LCA	*GUCY2D*	Homozygous	c.2132C>T, p.P711L
3799	LCA	*GUCY2D*	Compound Heterozygous	c.743C>G, p.S248W c.3224+1G>C
3725	LCA	*GUCY2D*	Compound Heterozygous	c.1343C>A, p.S448X[44] c.2678C>T, p.S893F
1272	LCA	*GUCY2D*	Compound Heterozygous	c.1933T>C, p.S645P c.2207T>G, p.M736R
1313	Juvenile RP	*PDE6A*	Compound Heterozygous	c.2333A>T, p.D778V c.1363A>T, p.K455X
3740	LCA	*RDH12*	Compound Heterozygous	c.692G>A, p.G231D c.823G>T, p.E275X
1268	LCA	*TULP1*	Compound Heterozygous	c.1518C>A, p.F506L c.1277C>T, p.P426L
3771	LCA	*TULP1*	Compound Heterozygous	c.1199G>A, p.R400Q[58] c.961T>G, p.Y321D
3681	LCA	*TULP1*	Compound Heterozygous	c.1102G>T, p.G368W[59] c.1064A>T, p.D355V

LCA, Leber congenital amaurosis; RP, retinitis pigmentosa.

Table 7 Eight patients carrying mutations known to cause other retinal diseases

Patient ID	Disease presentation	Gene	Previously reported disease	Type	Mutations
704	Juvenile RP	*BBS1*	BBS	Homozygous	c.1169T>G, p.M390R[60]
647	LCA	*CERKL*	Cone–rod dystrophy	Homozygous	c.375C>G, p.C125W[61]
3748	LCA	*CLN3*	Batten disease	Homozygous	c.597C>A, p.Y199X[62]
617	LCA	*NR2E3*	Enhanced S-cone syndrome	Homozygous	c.119–2A>C[63]
3311	Juvenile RP	*PRPF31*	adRP	Heterozygous	c.220C>T, p.Q74X[64]
1318	LCA	*PRPH2*	adRP	Homozygous	c.637T>C, p.C213R[65]
3256	LCA	*PRPH2*	adRP	Homozygous	c.554T>C, p.L185P[66]
3425	LCA	*SAG*	Oguchi disease	Homozygous	c.874C>T, p.R292X[67]

BBS, Bardet–Biedl syndrome; LCA, Leber congenital amaurosis; RP, retinitis pigmentosa.

Patients carrying mutations in other retinal disease genes

We also identified 14 patients who carried mutations in retinal disease genes that were not consistent with their initial clinical diagnosis, representing 19% of the 72 diagnosed patients. Using the criteria mentioned above, we classified these 14 patients into three groups based on the clinical significance of their mutations.

We identified eight patients in group 1 who carried reported mutations known to cause retinal disease genes that were not consistent with their initial clinical diagnosis (tables 3 and 7). Within this group, seven patients carried homozygous mutations. In addition, juvenile RP patient 3311 carried a heterozygous reported mutation known to cause autosomal dominant RP (adRP).

We identified two LCA patients in group 2 who carried homozygous or compound heterozygous novel LOF mutations in other retinal disease genes (tables 3 and 8). For example, patient 3688 carried a hemizygous novel splice site mutation c.248–1G>T in *RPGR*. Previously reported splice site mutations in *RPGR* were known to cause X-linked RP, supporting that this mutation may cause the retinal defects in patient 3688.

We identified four patients in group 3 who carried homozygous novel missense mutations in retinal diseases genes that were not consistent with their initial clinical diagnosis (tables 3 and 9). For example, patient 1327 carried a homozygous novel missense mutation c.728G>A (p.C243Y) in Bardet–Biedl syndrome (BBS) gene *BBS7*. This mutation changes a cysteine residue that is conserved across vertebrates. It was predicted to be damaging by all of the five in silico prediction algorithms, supporting that this mutation is likely to be pathogenic (see online supplementary table S4).

Revisiting patients carrying mutations in other retinal disease genes

In our study we observed that 14 patients carried mutations in genes that were not consistent with their initial clinical diagnosis. This observation may be explained by novel genotype–phenotype correlations, or by the difficulty assigning clinical diagnosis at the time of initial visit. In most cases, the first visit of a blind or low vision infant occurs shortly after birth. The initial clinical diagnosis may be difficult and influenced by the most obvious ophthalmic and visual findings at that time. To test these two possibilities, we managed to revisit 12 of these 14 patients.

Homozygous mutations in *PRPH2* cause EORD with LCA/juvenile RP phenotypes

After revisiting, we confirmed the clinical diagnosis of LCA in patients 1318 and 3256 (figure 3, online supplementary table S1). Each patient carried a reported homozygous missense mutation in gene *PRPH2*: c.637T>C (p.C213R) and c.554T>C (p.L185P), respectively (table 7). *PRPH2* encodes peripherin, a membrane glycoprotein that is important for the stabilisation and compaction of photoreceptor outer segment discs.[68] The p.C213R mutation is associated with autosomal dominant pattern dystrophy, and the p.L185P mutation, together with a null mutation in *ROM1*, has been reported to cause digenic RP.[65 66] However, it has not been reported that homozygous mutations in *PRPH2* cause severe EORD. To further validate this finding, we sequenced *PRPH2* in another 135 unsolved LCA or juvenile RP patients and found the same homozygous missense mutation p.L185P in *PRPH2* in a third juvenile RP patient, 741. These mutations were confirmed by Sanger sequencing and their segregations with the disease in the families were examined (figure 4). All the patients with homozygous mutations in *PRPH2* exhibited LCA or juvenile RP phenotypes, including visual impairment within the first year of life, nystagmus in the two LCA patients (1318 and 3256), non-detectable or reduced ERGs, and a very similar form of maculopathies in the fundus (figure 3, online supplementary table S1). By contrast, family members who carried heterozygous mutations in *PRPH2* were asymptomatic but showed detectable maculopathy phenotypes. For example, the 56-year-old father of patient 741 had macular pattern dystrophy and clear-cut foveal changes, but his visual acuity was essentially normal in both eyes (see online supplementary figure S2A–C, table S1). Similarly, the mother and the son of patient 1318 were both carriers of the mutation c.637T>C (p.C213R) (figure 4). At 57 years of age, the mother

Table 8 Two patients carrying novel LOF mutations in other retinal disease genes

Patient ID	Disease presentation	Gene	Previously reported disease	Type	Mutations
3494	LCA	*ALMS1*	Alström syndrome	Compound Heterozygous	c.2996C>G, p.S999X c.11410C>T, p.R3804X
3688	LCA	*RPGR*	X-linked RP	Hemizygous	c.248–1G>T

LCA, Leber congenital amaurosis; LOF, loss-of-function; RP, retinitis pigmentosa.

Table 9 four patients carrying homozygous novel missense mutations in other retinal disease genes

Patient ID	Disease presentation	Gene	Previously reported disease	Type	Mutations
3779	LCA	*ALMS1*	Alström syndrome	Homozygous	c.9764C>G, p.S3255C
1327	Juvenile RP	*BBS7*	BBS	Homozygous	c.728G>A, p.C243Y
3773	LCA	*INPP5E*	Joubert syndrome	Homozygous	c.1861C>T, p.R621W
3795	LCA	*SNRNP200*	adRP	Homozygous	c.3133C>A, p.P1045T

BBS, Bardet–Biedl syndrome; LCA, Leber congenital amaurosis; adRP, autosomal dominant retinitis pigmentosa.

was asymptomatic with 20/20 visual acuity but had a florid butterfly-shaped macular pattern dystrophy and a number of other retinal flecks upon examination (see online supplementary figure S2D). The 7-year-old son had a significant refractive defect whereby visual acuity was reduced due to partial amblyopia. His fundus showed a miniature form of foveal butterfly-shaped macular pattern dystrophy that was consistent with an early stage *PRPH2* related phenotype (data not shown). The brother of patient 1318, who was homozygous wild-type for the mutation, had normal visual acuity (20/20) and no maculopathy (data not shown). To our knowledge, our study reported for the first time that homozygous mutations in *PRPH2* cause EORD with LCA/juvenile RP phenotypes.

Revision of the initial clinical diagnosis in two patients

After revisiting, two patients were reclassified to retinal diseases that were consistent with their molecular diagnosis (tables 7 and 8, online supplementary table S1). The clinical diagnosis of the first patient 3425 who carried a reported homozygous nonsense mutation in the known Oguchi disease gene *SAG* was revised to Oguchi disease, which presents as congenital stationary night blindness, fundus discolouration, and slowed dark adaptation.[67] The second patient 3494 carried novel compound heterozygous nonsense mutations in the Alström syndrome gene *ALMS1* (Otable 8). Both mutations segregated with the disease in the family (see online supplementary table S1). Patient 3494 was initially diagnosed with LCA at the age of 8; however, revisiting this patient at the age of 11 revealed other syndromic features including obesity, diabetes mellitus, and learning difficulties (see online supplementary table S1). Furthermore, the fundus examination showed an atrophic bull's eye-like maculopathy, which was often seen in Alström syndrome patients (see online supplementary figure S3). These results indicate that molecular diagnosis can be a useful tool to revise or correct the initial clinical diagnosis.

The LCA-like or juvenile RP-like presentations in eight patients

Guided by the molecular diagnosis, revisiting the phenotypes of an additional eight patients revealed their 'LCA-like' or 'juvenile RP-like' phenotypes that may represent spectrums of corresponding retinal diseases (see online supplementary table S1). For example, patient 3688 carried a novel hemizygous splicing site mutation in X-linked RP gene *RPGR* (table 8). This patient exhibited 'LCA-like' phenotypes including nystagmus at birth, which is typically absent in X-linked RP (see online supplementary table S1). However, it is already known that X-linked RP patients may lose central and peripheral vision more rapidly than average RP patients.[69] Similarly, two patients (647, 617) carried reported mutations in cone–rod dystrophy gene *CERKL* and enhanced S-cone syndrome gene *NR2E3*, respectively (table 7). They exhibited 'LCA-like' phenotypes, including congenital visual impairment and nystagmus at birth (see online supplementary table S1). However, based on the available clinical information, the phenotypes of the two patients may also represent severe spectrums of cone–rod dystrophy and S-cone syndrome, respectively. Patient 3311 carried a heterozygous mutation in *PRPF31* that is known to cause RP with late onset and mild phenotypes.[64] This patient exhibited early onset 'juvenile RP-like', possibly due to modifier effect from another gene (see online supplementary table S1, figure S4).

In addition, four patients (704, 1327, 3748, and 3773) carried mutations in *BBS1*, *BBS7*, *CLN3*, and *INPP5E*, respectively (tables 7 and 9). Mutations in these genes were known to cause syndromes that are characterised by visual impairment and other systemic features.[70–72] It was also reported in some cases that these genes were associated with 'LCA-like' or 'RP-like' phenotypes without defects in other organs.[60 62 73] In our study, revisiting these patients confirmed their severe retinal degenerations without other syndromic features (see online supplementary table S1). For example, patient 704 carried a reported homozygous missense mutation in BBS gene *BBS1* (table 7). This mutation segregated with disease within the family (see online supplementary table S1). Revisiting this patient at the age of 53 confirmed the 'juvenile RP-like' phenotypes without other syndromic features (see online supplementary table S1). However, the retinal features of this patient were consistent with those observed in other BBS patients with *BBS1* mutations (see online supplementary figure S5).[72] Due to these molecular findings and retinal features, we should still follow up the potential development of syndromic phenotypes in these patients.

Collectively, these results suggest that the clinical manifestations of LCA/juvenile RP and related retinal diseases are overlapped, and that patients with 'LCA-like' or 'juvenile RP-like' phenotypes may actually carry mutations in non-canonical LCA/juvenile RP genes.[74] Therefore, molecular diagnosis should be used to refine the clinical diagnosis and get a better understanding of the disease. To achieve a more accurate diagnosis for these patients, it is essential to screen for mutations in a larger set of retinal disease genes.

DISCUSSION

In this study, we developed a targeted NGS based method for the molecular diagnosis of LCA and most other retinal diseases. We systematically evaluated this method on a HapMap sample and then applied it to 179 unrelated and prescreened LCA or juvenile RP patients. To our knowledge, our sample set represents the largest cohort of unrelated patients diagnosed with LCA or juvenile RP that is systematically screened for all known LCA genes and most other known retinal disease genes. In-depth analysis of this dataset led to several important findings.

A large number of novel mutations have been identified in our study, representing 54% (45/83) of the identified mutations in this patient cohort (table 2). Our observations are consistent

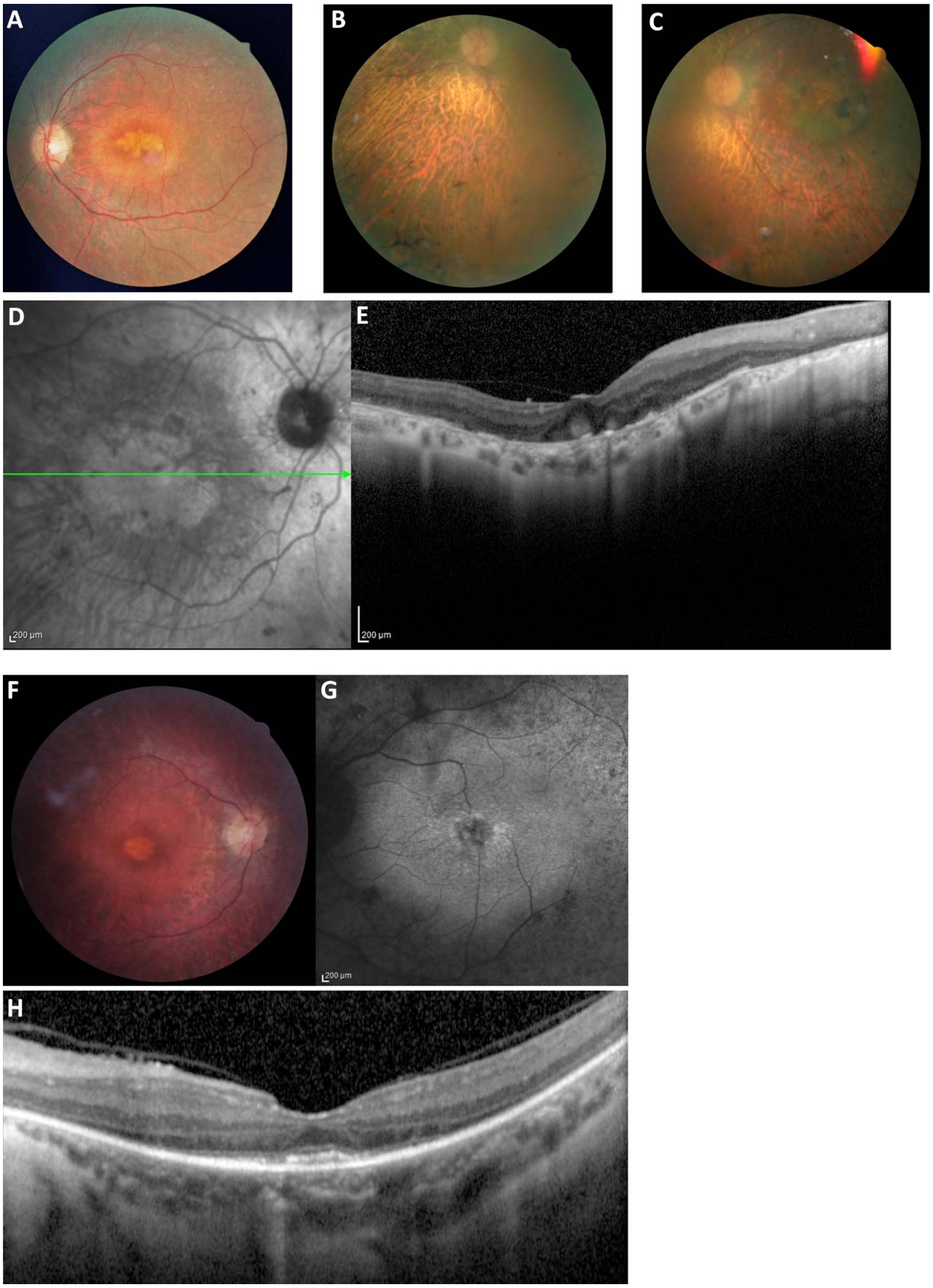

Figure 3 The phenotypes of patients 1318, 3256, and 741 who carry homozygous mutations in *PRPH2*. (A) Fundus photograph of patient 1318 shows a prominent multilobulated central atrophic maculopathy surrounded by concentric rings of yellow deposits, with vessel narrowing and fine diffuse peripheral retinal changes. (B–D) Fundus photographs of patient 3256 show pigment deposits both peripherally and in the macular region, extensive disease with choroidal sclerosis, vessel narrowing, and optic disc pallor; a central extensive atrophic maculopathy is seen in C and D. (E) Optical coherence tomography images of patient 3256 confirm the extensive maculopathy and unusual globular lesions in the foveal region. (F) Fundus photograph of patient 741 shows the obvious diffuse retinal dystrophy with retinal vessel narrowing, retinal pigment epithelium mottling and loss, and a multilobulated maculopathy. (G) Fundus autofluorescence of patient 741 shows diffuse retinal abnormalities, perifoveal hyper-autofluorescence and a multilobulated foveal abnormality. (H) Optical coherence tomography images of patient 741 shows inner segment/outer segment junction confined to the central macula, which explains well the fairly good visual acuity (20/40), and an unusual appearing deposit in the foveal regions. Note the similarity with the maculopathy shown in A, D, F, and G. The photographs of patients 1318, 3256, and 741 were taken at the age of 29, 66, and 30 years, respectively.

with the 1000 genome project's finding that every individual's genome contains a large number of rare variants.[25] Compared with common variants that arose earlier during the evolution, these recent rare variants may have greater impact on disease pathogenesis.[75] Therefore, we expect that a significant number of novel mutations will continue to be discovered every time a new patient is sequenced. Since NGS based molecular diagnosis can capture novel mutations, it is likely to achieve a high diagnosis rate. Among the 45 novel mutations that we identified, 29 were LOF mutations and 16 were missense mutations. All these novel mutations are likely to be pathogenic. First, these mutations are rare in large control databases. Collectively the

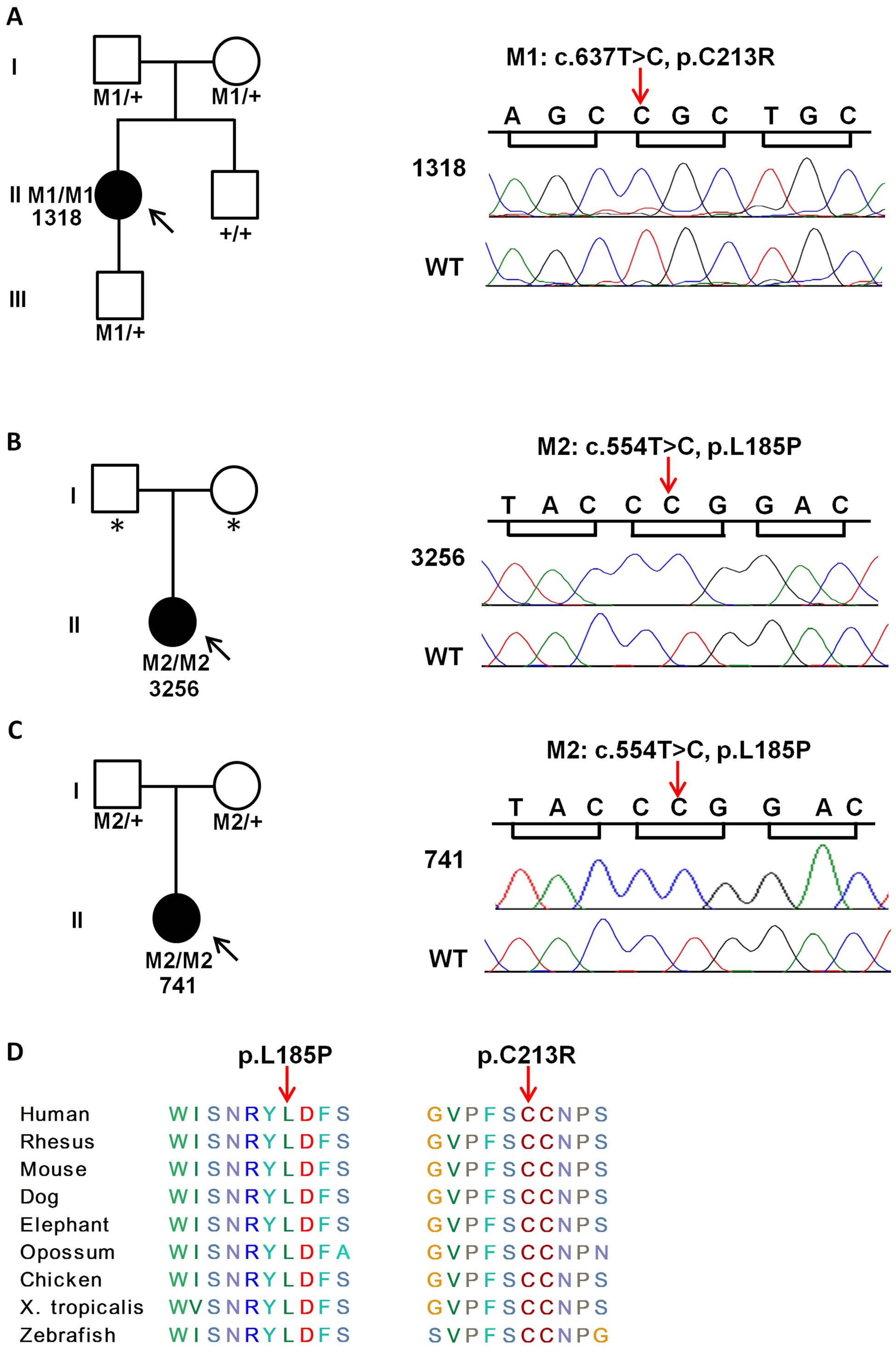
A
I
M1/+
M1/+
II M1/M1
1318
+/+
III
M1/+
M1: c.637T>C, p.C213R
A G C C G C T G C
1318
WT
B
I
*
*
II
M2/M2
3256
M2: c.554T>C, p.L185P
T A C C C G G A C
3256
WT
C
I
M2/+
M2/+
II
M2/M2
741
M2: c.554T>C, p.L185P
T A C C C G G A C
741
WT
D
p.L185P
p.C213R
Human WISNRYLDFS GVPFSCCNPS
Rhesus WISNRYLDFS GVPFSCCNPS
Mouse WISNRYLDFS GVPFSCCNPS
Dog WISNRYLDFS GVPFSCCNPS
Elephant WISNRYLDFS GVPFSCCNPS
Opossum WISNRYLDFA GVPFSCCNPN
Chicken WISNRYLDFS GVPFSCCNPS
X. tropicalis WVSNRYLDFS GVPFSCCNPS
Zebrafish WISNRYLDFS SVPFSCCNPG

Figure 4 Pathogenic mutations of *PRPH2* identified in three patients. (A–C) Pedigree information of three patients and Sanger sequencing results for the two mutations in patients and controls. (A) The c.637T>C mutation is homozygous in patient 1318, heterozygous in both parents and the son, and homozygous wild-type in the brother. (B) The c.554T>C mutation is homozygous in patient 3256. (C) The c.554T>C mutation is homozygous in patient 741 and heterozygous in both parents. (D) Amino acid residues affected by the two missense mutations are conserved across different species. Solid symbols: affected; open symbols: unaffected; squares: male; circles: female; arrow: proband; asterisk: the DNA was not available for both parents of 3256; M1 and M2 represent the two mutations, respectively.

databases used in our study contain more than 7400 control individuals. Second, all of these mutations match the reported inheritance pattern of the respective genes. In particular, the pathogenicity of all novel missense mutations reported in our study was supported by five well-established algorithms (see online supplementary table S4). Our study adds a significant number of novel pathogenic mutations to our current knowledge of disease causing mutations. These mutations can serve as references and directly benefit the future molecular diagnosis of patients clinically diagnosed with LCA or juvenile RP.

We identified the genetic defects in 40% of our patient cohort. This lower ratio is primarily due to the fact that our patient cohort had been prescreened. Among the initial cohort of 389 patients, we had previously identified mutations in known LCA genes for 210 patients (see Methods). Among the remaining 179 patients included in this study, mutations in known LCA genes were identified in 56 patients. Therefore, about 68% ((210+56)/389) of our initial cohort can be explained by mutations in known LCA genes. This is concordant with the estimation that mutations in current known LCA genes explain about 70% of LCA cases.[11] Among the 56 patients who carry mutations in known LCA genes, 24 patients have prescreening information available (see online supplementary table S5). We found that 16 patients had neither been screened by LCA APEX array nor been Sanger sequenced for the corresponding genes identified in this study. The remaining eight patients had been screened by LCA APEX array and/or Sanger sequencing for the corresponding genes identified in this study. Their mutations had not been identified in the prescreening because the mutations had not been covered by LCA APEX array and/or because Sanger sequencing only covered the frequently mutated exons of related genes.[15]

To our knowledge, our results demonstrate for the first time that homozygous mutations in *PRPH2* cause EORD. The phenotypes of the three patients with homozygous mutations in *PRPH2* were severe and quite consistent, especially with regard to the maculopathy phenotypes. By contrast, their family members who carried heterozygous mutations in *PRPH2* had milder phenotypes. These results are consistent with the previous observations in *PRPH2* mouse models. The *rds/rds* mouse that carried a homozygous null mutation in *PRPH2* failed to develop photoreceptor outer segments and showed early onset and severe retinal degeneration, whereas the heterozygous *rds/*+mouse displayed milder retinal degeneration and visual loss, suggesting that dose dependent phenotypic expression is an essential feature in the working of the *PRPH2* gene.[76 77] Until the discovery of these three patients homozygous for *PRPH2* mutations, the full severity of the retinal degeneration seen in the *rds/rds* mouse had not yet been observed in humans. In our study, individuals with heterozygous mutations in *PRPH2* were asymptomatic but had detectable macular flecks upon subsequent examination, exhibiting the clinical presentation of a macular pattern dystrophy, which is fully consistent with previously reported *PRPH2* mediated phenotypes.[65] By contrast, the severe early onset retinal defects in the three patients with homozygous mutations in *PRPH2* are novel and likely due to dose dependent effect.

It may be argued that the *rds/rds* mouse and our patients harboured different mutations and that individuals with the heterozygous p.L185P mutation in previously reported digenic RP families were originally reported as asymptomatic.[78] However, the p.L185P mutation is now known to exert a measurable partial LOF effect. Work from Molday and co-workers established that this peripherin mutant is conditionally defective with respect to subunit assembly, and is capable of forming peripherin dimers but not tetramers.[79 80] Furthermore, Kedzierski *et al* have shown that *rds/*+mice overexpressing L185P peripherin mutant indeed exhibited a mild phenotype. These mice had outer nuclear layer loss, partially disorganised outer segments, and reduced ERG responses. As observed in our patients homozygous for the p.L185P mutation, *rds/rds* mice overexpressing L185P peripherin mutant exhibited dramatically reduced levels of peripherin expression in their retinas, and a much more severe histological and electroretinographic retinal phenotype.[81] Taken together, these findings suggest that, although asymptomatic, individuals harbouring the heterozygous p.L185P mutation should be expected to exhibit a subclinical phenotype and it is possible that, as in our cases, later in life they may all consistently develop asymptomatic macular flecks or other minor yet measurable phenotypic manifestations.

Interestingly, similar examples have been reported for many other genes.[82 83] *PITX3* is a gene that is usually mutated in dominant congenital cataracts and anterior segment dysgenesis. However, patients with two mutations in this gene exhibited microphthalmia and central nervous system (CNS) abnormalities.[84] For another example, homozygous mutations in the low density lipoprotein (LDL) receptor gene were known to cause much more severe phenotypes of hypercholesterolaemia than heterozygous mutations.[85]

From a therapeutic standpoint, the implication for patients with retinal degenerations caused by homozygous mutations in *PRPH2* is that their diseases can be modelled by the *rds/rds* mouse, which has been treated by gene augmentation therapy in proof-of-concept research.[86 87] There is also a long history of investigation of the severe phenotype in this model, features of which can now be studied in the patients to determine how representative the model is in relation to the newly identified human condition.

There are two main explanations for the 60% of our patients for whom we were unable to find pathogenic mutations in this study. First, mutations that were not covered by our method, including intronic mutations, synonymous mutations, large structural variations, and copy number variations, may account for diseases in these patients. Second, these unsolved cases may due to novel disease-causing genes. Indeed, whole exome sequencing (WES) of some of these unsolved cases has led to the identification of a novel LCA gene *NMNAT1*.[6] Therefore, we expect that additional novel disease-causing genes will be identified by performing WES on these unsolved cases.

Our results highlight the utility of molecular information in diagnosing clinically heterogeneous diseases. Assigning clinical diagnosis at the time of initial visit is difficult in some cases, and molecular diagnosis can guide the health care provider to reassess the phenotypes of their patients and achieve a more accurate diagnosis. Indeed, guided by their molecular diagnosis, two patients in our study were reclassified with other retinal diseases. Additionally, the clinical manifestations of different retinal diseases are sometimes overlapped, and molecular diagnosis can help us to better define the disease. In our report, eight patients exhibited 'LCA-like' or 'juvenile RP-like' presentations. Based on the available clinical information, the diagnosis of these patients may be either LCA/juvenile RP, or extreme spectrums of other related retinal diseases, due to the allelic differences or genetic background. Despite the phenotypic similarity between different clinical diagnoses, diseases can be well defined by the molecular diagnosis. Therefore, with the rapid drop of sequencing costs, comprehensive mutation screening that covers all known retinal disease genes should become an integral part of diagnosis in the near future.

In addition to aiding the diagnosis, molecular information can directly contribute to better patient management. Recently, studies on gene therapy for LCA have made significant progress.[88–91] An accurate molecular diagnosis is the first step toward realising the promise of gene therapy. Additionally, it can clarify the prognosis and change the focus of the clinical follow-up. Patients with different molecularly defined diseases may receive a different prognosis and clinical interventions. For example, patients who exhibit LCA phenotypes but carry mutations in syndromic retinal disease genes should be followed for the development of syndromic features and be given corresponding clinical management. Finally, it can facilitate the genetic counselling and decision-making. Carrier tests or predictive tests for retinal diseases can inform prospective parents of their reproductive risk and possibly influence their decisions.

The low coverage regions in our design either had a higher GC content or were within duplicate regions (see online supplementary tables S2 and S3). Indeed, the GC content bias of coverage in Illumina sequencing data has been previously reported and the bias could be potentially introduced in many steps during sequencing.[92–94] It was recently recognised that PCR amplification before sequencing may be the major source of GC content bias; protocols to minimise such bias were proposed accordingly.[95 96] In addition, low coverage in duplicated regions is likely due to the inability to map reads to a single unique position. The relatively shorts reads (90~300 bp) generated by most currently available NGS platforms lack enough sequence specificity to be mapped to a single location among multiple duplicated regions. To uncover the genomic information of duplicated regions, long range PCR or NGS sequencer producing longer reads may be utilised.

In summary, we were able to identify pathogenic mutations for 40% of this prescreened patient cohort. A total of 45 novel pathogenic mutations were found. Interestingly, we found that homozygous mutations in *PRPH2* can cause LCA and juvenile RP. Our study highlighted the utility of comprehensive molecular information as an integral part of the diagnosis process to achieve more accurate diagnosis and potentially better disease treatment and management.

Author affiliations
[1]Human Genome Sequencing Center, Baylor College of Medicine, Houston, Texas, USA
[2]Departments of Molecular and Human Genetics, Baylor College of Medicine, Houston, Texas, USA
[3]McGill Ocular Genetics Laboratory (MOGL), Departments of Paediatric Surgery, Human Genetics and Ophthalmology, Montreal Children's Hospital, McGill University Health Center, Montreal, Quebec, Canada
[4]Structural and Computational Biology & Molecular Biophysics Graduate Program, Baylor College of Medicine, Houston, Texas, USA
[5]Scheie Eye Institute, Department of Ophthalmology, University of Pennsylvania, Philadelphia, Pennsylvania, USA
[6]Hamilton Eye Institute, University of Tennessee Health Science Center, Memphis, Tennessee, USA
[7]Retina Foundation of the Southwest and Department of Ophthalmology, University of Texas Southwestern Medical School, Dallas, Texas, USA
[8]Department of Ophthalmology and Visual Sciences Center for Retinal and Macular Degeneration, University of Michigan, Ann Arbor, Michigan, USA
[9]The Chicago Lighthouse for the Blind and Visually Impaired, Chicago, Illinois, USA
[10]Ophthalmology, Cleveland Clinic, Cleveland, Ohio, USA
[11]Program in Developmental Biology, Baylor College of Medicine, Houston, Texas, USA

Acknowledgements We sincerely thank all the patients and their families for their participation. We thank Ms Shirley Briand, Ms Alcira Vieiri and Ms Renee Pigeon for coordinating the blindness clinics at the McGill Ocular Genetics Laboratory. XW is supported by predoctoral fellowship: The Burroughs Wellcome Fund, The Houston Laboratory and Population Sciences Training Program in Gene Environment Interaction. HW is supported by NIH postdoctoral fellowship 5F32EY19430. JEZ is supported by NIH training grant T32 EY007102. RKK is supported by the Foundation Fighting Blindness Canada, the Canadian Institutes for Health Research, FRSQ, the Foundation for Retinal Research, and Reseau Vision. AI is supported by grant from Research to Prevent Blindness, Inc, New York, NY (unrestricted grant to UTHSC Department of Ophthalmology and a Physician Scientist Award to AI). This work is supported by grants from the Retinal Research Foundation and the National Eye Institute (R01EY018571 and R01EY020540) to RC.

Contributors RC, XW and RKK designed the study. SGJ, AI, DB, JRH, GAF, EIT and DW performed the clinical study. XW, HW, VS, HFT, VK, KW, HR, IL, JEZ, SS, SB, AK, JS, FW and YL performed the molecular study. XW integrated the data and performed the analysis. XW, HFT, RC, RKK, JEZ, SGJ, AI wrote the manuscript.

Funding Retinal Research Foundation and the National Eye Institute.

Competing interests None.

Provenance and peer review Not commissioned; externally peer reviewed.

REFERENCES

1 Franceschetti A, Dieterle P. [Diagnostic and prognostic importance of the electroretinogram in tapetoretinal degeneration with reduction of the visual field and hemeralopia]. *Confin Neurol* 1954;14:184–6.
2 Leber T. Ueber Retinitis pigmentosa und angeborene Amaurose. *Graefes Arch Clin Exp Ophthalmol* 1869;15:1–25.
3 Koenekoop RK. An overview of Leber congenital amaurosis: a model to understand human retinal development. *Surv Ophthalmol* 2004;49:379–98.
4 Stone EM. Leber congenital amaurosis—a model for efficient genetic testing of heterogeneous disorders: LXIV Edward Jackson Memorial Lecture. *Am J Ophthalmol* 2007;144:791–811.
5 Estrada-Cuzcano A, Koenekoop RK, Coppieters F, Kohl S, Lopez I, Collin RW, De Baere EB, Roeleveld D, Marek J, Bernd A, Rohrschneider K, van den Born LI, Meire F, Maumenee IH, Jacobson SG, Hoyng CB, Zrenner E, Cremers FP, den Hollander AI. IQCB1 mutations in patients with Leber congenital amaurosis. *Invest Ophthalmol Vis Sci* 2011;52:834–9.
6 Koenekoop RK, Wang H, Majewski J, Wang X, Lopez I, Ren H, Chen Y, Li Y, Fishman GA, Genead M, Schwartzentruber J, Solanki N, Traboulsi EI, Cheng J, Logan CV, McKibbin M, Hayward BE, Parry DA, Johnson CA, Nageeb M, Poulter JA, Mohamed MD, Jafri H, Rashid Y, Taylor GR, Keser V, Mardon G, Xu H, Inglehearn CF, Fu Q, Toomes C, Chen R. Mutations in NMNAT1 cause Leber congenital amaurosis and identify a new disease pathway for retinal degeneration. *Nat Genet* 2012;44:1035–9.
7 Falk MJ, Zhang Q, Nakamaru-Ogiso E, Kannabiran C, Fonseca-Kelly Z, Chakarova C, Audo I, Mackay DS, Zeitz C, Borman AD, Staniszewska M, Shukla R, Palavalli L, Mohand-Said S, Waseem NH, Jalali S, Perin JC, Place E, Ostrovsky J, Xiao R, Bhattacharya SS, Consugar M, Webster AR, Sahel JA, Moore AT, Berson EL, Liu Q, Gai X, Pierce EA. NMNAT1 mutations cause Leber congenital amaurosis. *Nat Genet* 2012;44:1040–5.
8 Perrault I, Hanein S, Zanlonghi X, Serre V, Nicouleau M, Defoort-Delhemmes S, Delphin N, Fares-Taie L, Gerber S, Xerri O, Edelson C, Goldenberg A, Duncombe A, Le Meur G, Hamel C, Silva E, Nitschke P, Calvas P, Munnich A, Roche O, Dollfus H, Kaplan J, Rozet JM. Mutations in NMNAT1 cause Leber congenital amaurosis with early-onset severe macular and optic atrophy. *Nat Genet* 2012;44:975–7.
9 Wang H, den Hollander AI, Moayedi Y, Abulimiti A, Li Y, Collin RW, Hoyng CB, Lopez I, Abboud EB, Al-Rajhi AA, Bray M, Lewis RA, Lupski JR, Mardon G, Koenekoop RK, Chen R. Mutations in SPATA7 cause Leber congenital amaurosis and juvenile retinitis pigmentosa. *Am J Hum Genet* 2009;84:380–7.
10 Sergouniotis PI, Davidson AE, Mackay DS, Li Z, Yang X, Plagnol V, Moore AT, Webster AR. Recessive mutations in KCNJ13, encoding an inwardly rectifying potassium channel subunit, cause Leber congenital amaurosis. *Am J Hum Genet* 2011;89:183–90.
11 den Hollander AI, Roepman R, Koenekoop RK, Cremers FP. Leber congenital amaurosis: genes, proteins and disease mechanisms. *Prog Retin Eye Res* 2008;27:391–419.
12 Chiang PW, Wang J, Chen Y, Fu Q, Zhong J, Yi X, Wu R, Gan H, Shi Y, Barnett C, Wheaton D, Day M, Sutherland J, Heon E, Weleber RG, Gabriel LA, Cong P, Chuang K, Ye S, Sallum JM, Qi M. Exome sequencing identifies NMNAT1 mutations as a cause of Leber congenital amaurosis. *Nat Genet* 2012;44:972–4.
13 den Hollander AI, Lopez I, Yzer S, Zonneveld MN, Janssen IM, Strom TM, Hehir-Kwa JY, Veltman JA, Arends ML, Meitinger T, Musarella MA, van den Born LI, Fishman GA, Maumenee IH, Rohrschneider K, Cremers FP, Koenekoop RK. Identification of novel mutations in patients with Leber congenital amaurosis and juvenile RP by genome-wide homozygosity mapping with SNP microarrays. *Invest Ophthalmol Vis Sci* 2007;48:5690–8.
14 Yzer S, Leroy BP, De Baere E, de Ravel TJ, Zonneveld MN, Voesenek K, Kellner U, Ciriano JP, de Faber JT, Rohrschneider K, Roepman R, den Hollander AI, Cruysberg JR, Meire F, Casteels I, van Moll-Ramirez NG, Allikmets R, van den Born LI, Cremers FP. Microarray-based mutation detection and phenotypic characterization of patients with Leber congenital amaurosis. *Invest Ophthalmol Vis Sci* 2006;47:1167–76.
15 Zernant J, Kulm M, Dharmaraj S, den Hollander AI, Perrault I, Preising MN, Lorenz B, Kaplan J, Cremers FP, Maumenee I, Koenekoop RK, Allikmets R. Genotyping microarray (disease chip) for Leber congenital amaurosis: detection of modifier alleles. *Invest Ophthalmol Vis Sci* 2005;46:3052–9.
16 Henderson RH, Waseem N, Searle R, van der Spuy J, Russell-Eggitt I, Bhattacharya SS, Thompson DA, Holder GE, Cheetham ME, Webster AR, Moore AT. An assessment of the apex microarray technology in genotyping patients with Leber congenital amaurosis and early-onset severe retinal dystrophy. *Invest Ophthalmol Vis Sci* 2007;48:5684–9.
17 Shanks ME, Downes SM, Copley RR, Lise S, Broxholme J, Hudspith KA, Kwasniewska A, Davies WI, Hankins MW, Packham ER, Clouston P, Seller A, Wilkie AO, Taylor JC, Ragoussis J, Nemeth AH. Next-generation sequencing (NGS)

as a diagnostic tool for retinal degeneration reveals a much higher detection rate in early-onset disease. *Eur J Hum Genet* 2012.

18 Neveling K, Collin RW, Gilissen C, van Huet RA, Visser L, Kwint MP, Gijsen SJ, Zonneveld MN, Wieskamp N, de Ligt J, Siemiatkowska AM, Hoefsloot LH, Buckley MF, Kellner U, Branham KE, den Hollander AI, Hoischen A, Hoyng C, Klevering BJ, van den Born LI, Veltman JA, Cremers FP, Scheffer H. Next-generation genetic testing for retinitis pigmentosa. *Hum Mutat* 2012;33:963–72.

19 Coppieters F, De Wilde B, Lefever S, De Meester E, De Rocker N, Van Cauwenbergh C, Pattyn F, Meire F, Leroy BP, Hellemans J, Vandesompele J, De Baere E. Massively parallel sequencing for early molecular diagnosis in Leber congenital amaurosis. *Genet Med* 2012;14:576–85.

20 Galvin JA, Fishman GA, Stone EM, Koenekoop RK. Evaluation of genotype-phenotype associations in leber congenital amaurosis. *Retina* 2005;25:919–29.

21 Li H, Durbin R. Fast and accurate short read alignment with Burrows-Wheeler transform. *Bioinformatics* 2009;25:1754–60.

22 McKenna A, Hanna M, Banks E, Sivachenko A, Cibulskis K, Kernytsky A, Garimella K, Altshuler D, Gabriel S, Daly M, DePristo MA. The Genome Analysis Toolkit: a MapReduce framework for analyzing next-generation DNA sequencing data. *Genome Res* 2010;20:1297–303.

23 Challis D, Yu J, Evani US, Jackson AR, Paithankar S, Coarfa C, Milosavljevic A, Gibbs RA, Yu F. An integrative variant analysis suite for whole exome next-generation sequencing data. *BMC Bioinformatics* 2012;13:8.

24 Sherry ST, Ward MH, Kholodov M, Baker J, Phan L, Smigielski EM, Sirotkin K. dbSNP: the NCBI database of genetic variation. *Nucleic Acids Res* 2001;29:308–11.

25 1000 Genomes Project Consortium. A map of human genome variation from population-scale sequencing. *Nature* 2010;467:1061–73.

26 Wang K, Li M, Hakonarson H. ANNOVAR: functional annotation of genetic variants from high-throughput sequencing data. *Nucleic Acids Res* 2010;38:e164.

27 Liu X, Jian X, Boerwinkle E. dbNSFP: a lightweight database of human nonsynonymous SNPs and their functional predictions. *Hum Mutat* 2011;32:894–9.

28 Kumar P, Henikoff S, Ng PC. Predicting the effects of coding non-synonymous variants on protein function using the SIFT algorithm. *Nat Protoc* 2009;4:1073–81.

29 Pollard KS, Hubisz MJ, Rosenbloom KR, Siepel A. Detection of nonneutral substitution rates on mammalian phylogenies. *Genome Res* 2010;20:110–21.

30 Chun S, Fay JC. Identification of deleterious mutations within three human genomes. *Genome Res* 2009;19:1553–61.

31 Adzhubei IA, Schmidt S, Peshkin L, Ramensky VE, Gerasimova A, Bork P, Kondrashov AS, Sunyaev SR. A method and server for predicting damaging missense mutations. *Nat Methods* 2010;7:248–9.

32 Schwarz JM, Rodelsperger C, Schuelke M, Seelow D. MutationTaster evaluates disease-causing potential of sequence alterations. *Nat Methods* 2010;7:575–6.

33 The International HapMap Consortium. The International HapMap Project. *Nature* 2003;426:789–96.

34 Stenson PD, Mort M, Ball EV, Howells K, Phillips AD, Thomas NS, Cooper DN. The Human Gene Mutation Database: 2008 update. *Genome Med* 2009;1:13.

35 Richards CS, Bale S, Bellissimo DB, Das S, Grody WW, Hegde MR, Lyon E, Ward BE. ACMG recommendations for standards for interpretation and reporting of sequence variations: revisions 2007. *Genet Med* 2008;10:294–300.

36 Thompson DA, Janecke AR, Lange J, Feathers KL, Hubner CA, McHenry CL, Stockton DW, Rammesmayer G, Lupski JR, Antinolo G, Ayuso C, Baiget M, Gouras P, Heckenlively JR, den Hollander A, Jacobson SG, Lewis RA, Sieving PA, Wissinger B, Yzer S, Zrenner E, Utermann G, Gal A. Retinal degeneration associated with RDH12 mutations results from decreased 11-cis retinal synthesis due to disruption of the visual cycle. *Hum Mol Genet* 2005;14:3865–75.

37 Janecke AR, Thompson DA, Utermann G, Becker C, Hubner CA, Schmid E, McHenry CL, Nair AR, Ruschendorf F, Heckenlively J, Wissinger B, Nurnberg P, Gal A. Mutations in RDH12 encoding a photoreceptor cell retinol dehydrogenase cause childhood-onset severe retinal dystrophy. *Nat Genet* 2004;36:850–4.

38 Sohocki MM, Bowne SJ, Sullivan LS, Blackshaw S, Cepko CL, Payne AM, Bhattacharya SS, Khaliq S, Qasim Mehdi S, Birch DG, Harrison WR, Elder FF, Heckenlively JR, Daiger SP. Mutations in a new photoreceptor-pineal gene on 17p cause Leber congenital amaurosis. *Nat Genet* 2000;24:79–83.

39 Sohocki MM, Perrault I, Leroy BP, Payne AM, Dharmaraj S, Bhattacharya SS, Kaplan J, Maumenee IH, Koenekoop R, Meire FM, Birch DG, Heckenlively JR, Daiger SP. Prevalence of AIPL1 mutations in inherited retinal degenerative disease. *Mol Genet Metab* 2000;70:142–50.

40 den Hollander AI, Koenekoop RK, Yzer S, Lopez I, Arends ML, Voesenek KE, Zonneveld MN, Strom TM, Meitinger T, Brunner HG, Hoyng CB, van den Born LI, Rohrschneider K, Cremers FP. Mutations in the CEP290 (NPHP6) gene are a frequent cause of Leber congenital amaurosis. *Am J Hum Genet* 2006;79:556–61.

41 Sayer JA, Otto EA, O'Toole JF, Nurnberg G, Kennedy MA, Becker C, Hennies HC, Helou J, Attanasio M, Fausett BV, Utsch B, Khanna H, Liu Y, Drummond I, Kawakami I, Kusakabe T, Tsuda M, Ma L, Lee H, Larson RG, Allen SJ, Wilkinson CJ, Nigg EA, Shou C, Lillo C, Williams DS, Hoppe B, Kemper MJ, Neuhaus T, Parisi MA, Glass IA, Petry M, Kispert A, Gloy J, Ganner A, Walz G, Zhu X, Goldman D, Nurnberg P, Swaroop A, Leroux MR, Hildebrandt F. The centrosomal protein nephrocystin-6 is mutated in Joubert syndrome and activates transcription factor ATF4. *Nat Genet* 2006;38:674–81.

42 Perrault I, Delphin N, Hanein S, Gerber S, Dufier JL, Roche O, Defoort-Dhellemmes S, Dollfus H, Fazzi E, Munnich A, Kaplan J, Rozet JM. Spectrum of NPHP6/CEP290 mutations in Leber congenital amaurosis and delineation of the associated phenotype. *Hum Mutat* 2007;28:416.

43 Lotery AJ, Jacobson SG, Fishman GA, Weleber RG, Fulton AB, Namperumalsamy P, Heon E, Levin AV, Grover S, Rosenow JR, Kopp KK, Sheffield VC, Stone EM. Mutations in the CRB1 gene cause Leber congenital amaurosis. *Arch Ophthalmol* 2001;119:415–20.

44 Perrault I, Rozet JM, Gerber S, Ghazi I, Ducroq D, Souied E, Leowski C, Bonnemaison M, Dufier JL, Munnich A, Kaplan J. Spectrum of retGC1 mutations in Leber's congenital amaurosis. *Eur J Hum Genet* 2000;8:578–82.

45 Coppieters F, Casteels I, Meire F, De Jaegere S, Hooghe S, van Regemorter N, Van Esch H, Matuleviciene A, Nunes L, Meersschaut V, Walraedt S, Standaert L, Coucke P, Hoeben H, Kroes HY, Vande Walle J, de Ravel T, Leroy BP, De Baere E. Genetic screening of LCA in Belgium: predominance of CEP290 and identification of potential modifier alleles in AHI1 of CEP290-related phenotypes. *Hum Mutat* 2010;31:E1709–66.

46 Lotery AJ, Namperumalsamy P, Jacobson SG, Weleber RG, Fishman GA, Musarella MA, Hoyt CS, Heon E, Levin A, Jan J, Lam B, Carr RE, Franklin A, Radha S, Andorf JL, Sheffield VC, Stone EM. Mutation analysis of 3 genes in patients with Leber congenital amaurosis. *Arch Ophthalmol* 2000;118:538–43.

47 den Hollander AI, Koenekoop RK, Mohamed MD, Arts HH, Boldt K, Towns KV, Sedmak T, Beer M, Nagel-Wolfrum K, McKibbin M, Dharmaraj S, Lopez I, Ivings L, Williams GA, Springell K, Woods CG, Jafri H, Rashid Y, Strom TM, van der Zwaag B, Gosens I, Kersten FF, van Wijk E, Veltman JA, Zonneveld MN, van Beersum SE, Maumenee IH, Wolfrum U, Cheetham ME, Ueffing M, Cremers FP, Inglehearn CF, Roepman R. Mutations in LCA5, encoding the ciliary protein lebercilin, cause Leber congenital amaurosis. *Nat Genet* 2007;39:889–95.

48 Senechal A, Humbert G, Surget MO, Bazalgette C, Arnaud B, Arndt C, Laurent E, Brabet P, Hamel CP. Screening genes of the retinoid metabolism: novel LRAT mutation in leber congenital amaurosis. *Am J Ophthalmol* 2006;142:702–4.

49 Morimura H, Fishman GA, Grover SA, Fulton AB, Berson EL, Dryja TP. Mutations in the RPE65 gene in patients with autosomal recessive retinitis pigmentosa or leber congenital amaurosis. *Proc Natl Acad Sci U S A* 1998;95:3088–93.

50 Li Y, Wang H, Peng J, Gibbs RA, Lewis RA, Lupski JR, Mardon G, Chen R. Mutation survey of known LCA genes and loci in the Saudi Arabian population. *Invest Ophthalmol Vis Sci* 2009;50:1336–43.

51 Thompson DA, Li Y, McHenry CL, Carlson TJ, Ding X, Sieving PA, Apfelstedt-Sylla E, Gal A. Mutations in the gene encoding lecithin retinol acyltransferase are associated with early-onset severe retinal dystrophy. *Nat Genet* 2001;28:123–4.

52 Clark GR, Crowe P, Muszynska D, O'Prey D, O'Neill J, Alexander S, Willoughby CE, McKay GJ, Silvestri G, Simpson DA. Development of a diagnostic genetic test for simplex and autosomal recessive retinitis pigmentosa. *Ophthalmology* 2010;117:2169–77, e3.

53 Collin RW, van den Born LI, Klevering BJ, de Castro-Miro M, Littink KW, Arimadyo K, Azam M, Yazar V, Zonneveld MN, Paun CC, Siemiatkowska AM, Strom TM, Hehir-Kwa JY, Kroes HY, de Faber JT, van Schooneveld MJ, Heckenlively JR, Hoyng CB, den Hollander AI, Cremers FP. High-resolution homozygosity mapping is a powerful tool to detect novel mutations causative of autosomal recessive RP in the Dutch population. *Invest Ophthalmol Vis Sci* 2011;52:2227–39.

54 Moise AR, Golczak M, Imanishi Y, Palczewski K. Topology and membrane association of lecithin: retinol acyltransferase. *J Biol Chem* 2007;282:2081–90.

55 Hu J, Ng PC. Predicting the effects of frameshifting indels. *Genome Biol* 2012; 13:R9.

56 Henderson RH, Williamson KA, Kennedy JS, Webster AR, Holder GE, Robson AG, FitzPatrick DR, van Heyningen V, Moore AT. A rare de novo nonsense mutation in OTX2 causes early onset retinal dystrophy and pituitary dysfunction. *Mol Vis* 2009;15:2442–7.

57 Otto EA, Loeys B, Khanna H, Hellemans J, Sudbrak R, Fan S, Muerb U, O'Toole JF, Helou J, Attanasio M, Utsch B, Sayer JA, Lillo C, Jimeno D, Coucke P, De Paepe A, Reinhardt R, Klages S, Tsuda M, Kawakami I, Kusakabe T, Omran H, Imm A, Tippens M, Raymond PA, Hill J, Beales P, He S, Kispert A, Margolis B, Williams DS, Swaroop A, Hildebrandt F. Nephrocystin-5, a ciliary IQ domain protein, is mutated in Senior-Loken syndrome and interacts with RPGR and calmodulin. *Nat Genet* 2005;37:282–8.

58 Singh HP, Jalali S, Narayanan R, Kannabiran C. Genetic analysis of Indian families with autosomal recessive retinitis pigmentosa by homozygosity screening. *Invest Ophthalmol Vis Sci* 2009;50:4065–71.

59 Hanein S, Perrault I, Gerber S, Tanguy G, Barbet F, Ducroq D, Calvas P, Dollfus H, Hamel C, Lopponen T, Munier F, Santos L, Shalev S, Zafeiriou D, Dufier JL, Munnich A, Rozet JM, Kaplan J. Leber congenital amaurosis: comprehensive survey of the genetic heterogeneity, refinement of the clinical definition, and genotype-phenotype correlations as a strategy for molecular diagnosis. *Hum Mutat* 2004;23:306–17.

60 Estrada-Cuzcano A, Koenekoop RK, Senechal A, De Baere EB, de Ravel T, Banfi S, Kohl S, Ayuso C, Sharon D, Hoyng CB, Hamel CP, Leroy BP, Ziviello C, Lopez I, Bazinet A, Wissinger B, Sliesoraityte I, Avila-Fernandez A, Littink KW, Vingolo EM, Signorini S, Banin E, Mizrahi-Meissonnier L, Zrenner E, Kellner U, Collin RW, den Hollander AI, Cremers FP, Klevering BJ. BBS1 mutations in a wide spectrum of phenotypes ranging from nonsyndromic retinitis pigmentosa to Bardet-Biedl syndrome. *Arch Ophthalmol* 2012;130:1425–32.

61 Littink KW, Koenekoop RK, van den Born LI, Collin RW, Moruz L, Veltman JA, Roosing S, Zonneveld MN, Omar A, Darvish M, Lopez I, Kroes HY, van Genderen MM, Hoyng CB, Rohrschneider K, van Schooneveld MJ, Cremers FP, den Hollander AI. Homozygosity mapping in patients with cone-rod dystrophy: novel mutations and clinical characterizations. *Invest Ophthalmol Vis Sci* 2010;51:5943–51.

62 Sarpong A, Schottmann G, Ruther K, Stoltenburg G, Kohlschutter A, Hubner C, Schuelke M. Protracted course of juvenile ceroid lipofuscinosis associated with a novel CLN3 mutation (p.Y199X). *Clin Genet* 2009;76:38–45.

63 Haider NB, Jacobson SG, Cideciyan AV, Swiderski R, Streb LM, Searby C, Beck G, Hockey R, Hanna DB, Gorman S, Duhl D, Carmi R, Bennett J, Weleber RG, Fishman GA, Wright AF, Stone EM, Sheffield VC. Mutation of a nuclear receptor gene, NR2E3, causes enhanced S cone syndrome, a disorder of retinal cell fate. *Nat Genet* 2000;24:127–31.

64 Sullivan LS, Bowne SJ, Birch DG, Hughbanks-Wheaton D, Heckenlively JR, Lewis RA, Garcia CA, Ruiz RS, Blanton SH, Northrup H, Gire AI, Seaman R, Duzkale H, Spellicy CJ, Zhu J, Shankar SP, Daiger SP. Prevalence of disease-causing mutations in families with autosomal dominant retinitis pigmentosa: a screen of known genes in 200 families. *Invest Ophthalmol Vis Sci* 2006;47:3052–64.

65 Payne AM, Downes SM, Bessant DA, Bird AC, Bhattacharya SS. Founder effect, seen in the British population, of the 172 peripherin/RDS mutation-and further refinement of genetic positioning of the peripherin/RDS gene. *Am J Hum Genet* 1998;62:192–5.

66 Kajiwara K, Hahn LB, Mukai S, Travis GH, Berson EL, Dryja TP. Mutations in the human retinal degeneration slow gene in autosomal dominant retinitis pigmentosa. *Nature* 1991;354:480–3.

67 Nakamura M, Yamamoto S, Okada M, Ito S, Tano Y, Miyake Y. Novel mutations in the arrestin gene and associated clinical features in Japanese patients with Oguchi's disease. *Ophthalmology* 2004;111:1410–14.

68 Travis GH, Sutcliffe JG, Bok D. The retinal degeneration slow (rds) gene product is a photoreceptor disc membrane-associated glycoprotein. *Neuron* 1991;6:61–70.

69 Iannaccone A. The genetics of hereditary retinopathies and optic neuropathies. *Compr Ophthalmol Update* 2005;6:39–62.

70 Badano JL, Ansley SJ, Leitch CC, Lewis RA, Lupski JR, Katsanis N. Identification of a novel Bardet-Biedl syndrome protein, BBS7, that shares structural features with BBS1 and BBS2. *Am J Hum Genet* 2003;72:650–8.

71 The International Batten Disease Consortium. Isolation of a novel gene underlying Batten disease, CLN3. *Cell* 1995;82:949–57.

72 Bielas SL, Silhavy JL, Brancati F, Kisseleva MV, Al-Gazali L, Sztriha L, Bayoumi RA, Zaki MS, Abdel-Aleem A, Rosti RO, Kayserili H, Swistun D, Scott LC, Bertini E, Boltshauser E, Fazzi E, Travaglini L, Field SJ, Gayral S, Jacoby M, Schurmans S, Dallapiccola B, Majerus PW, Valente EM, Gleeson JG. Mutations in INPP5E, encoding inositol polyphosphate-5-phosphatase E, link phosphatidyl inositol signaling to the ciliopathies. *Nat Genet* 2009;41:1032–6.

73 Cox KF, Kerr NC, Kedrov M, Nishimura D, Jennings BJ, Stone EM, Sheffield VC, Iannaccone A. Phenotypic expression of Bardet-Biedl syndrome in patients homozygous for the common M390R mutation in the BBS1 gene. *Vision Res* 2012;75:77–87.

74 Wang X, Wang H, Cao M, Li Z, Chen X, Patenia C, Gore A, Abboud EB, Al-Rajhi AA, Lewis RA, Lupski JR, Mardon G, Zhang K, Muzny D, Gibbs RA, Chen R. Whole-exome sequencing identifies ALMS1, IQCB1, CNGA3, and MYO7A mutations in patients with Leber congenital amaurosis. *Hum Mutat* 2011;32:1450–9.

75 Lupski JR, Belmont JW, Boerwinkle E, Gibbs RA. Clan genomics and the complex architecture of human disease. *Cell* 2011;147:32–43.

76 van Nie R, Ivanyi D, Demant P. A new H-2-linked mutation, rds, causing retinal degeneration in the mouse. *Tissue Antigens* 1978;12:106–8.

77 Hawkins RK, Jansen HG, Sanyal S. Development and degeneration of retina in rds mutant mice: photoreceptor abnormalities in the heterozygotes. *Exp Eye Res* 1985;41:701–20.

78 Kajiwara K, Berson EL, Dryja TP. Digenic retinitis pigmentosa due to mutations at the unlinked peripherin/RDS and ROM1 loci. *Science* 1994;264:1604–8.

79 Goldberg AF, Molday RS. Defective subunit assembly underlies a digenic form of retinitis pigmentosa linked to mutations in peripherin/rds and rom-1. *Proc Natl Acad Sci U S A* 1996;93:13726–30.

80 Loewen CJ, Moritz OL, Molday RS. Molecular characterization of peripherin-2 and rom-1 mutants responsible for digenic retinitis pigmentosa. *J Biol Chem* 2001;276:22388–96.

81 Kedzierski W, Nusinowitz S, Birch D, Clarke G, McInnes RR, Bok D, Travis GH. Deficiency of rds/peripherin causes photoreceptor death in mouse models of digenic and dominant retinitis pigmentosa. *Proc Natl Acad Sci USA* 2001;98:7718–23.

82 Wittstrom E, Ekvall S, Schatz P, Bondeson ML, Ponjavic V, Andreasson S. Morphological and functional changes in multifocal vitelliform retinopathy and biallelic mutations in BEST1. *Ophthalmic Genet* 2011;32:83–96.

83 Burgess R, Millar ID, Leroy BP, Urquhart JE, Fearon IM, De Baere E, Brown PD, Robson AG, Wright GA, Kestelyn P, Holder GE, Webster AR, Manson FD, Black GC. Biallelic mutation of BEST1 causes a distinct retinopathy in humans. *Am J Hum Genet* 2008;82:19–31.

84 Bidinost C, Matsumoto M, Chung D, Salem N, Zhang K, Stockton DW, Khoury A, Megarbane A, Bejjani BA, Traboulsi EI. Heterozygous and homozygous mutations in PITX3 in a large Lebanese family with posterior polar cataracts and neurodevelopmental abnormalities. *Invest Ophthalmol Vis Sci* 2006;47:1274–80.

85 Naoumova RP, Thompson GR, Soutar AK. Current management of severe homozygous hypercholesterolaemias. *Curr Opin Lipidol* 2004;15:413–22.

86 Ali RR, Sarra GM, Stephens C, Alwis MD, Bainbridge JW, Munro PM, Fauser S, Reichel MB, Kinnon C, Hunt DM, Bhattacharya SS, Thrasher AJ. Restoration of photoreceptor ultrastructure and function in retinal degeneration slow mice by gene therapy. *Nat Genet* 2000;25:306–10.

87 Schlichtenbrede FC, da Cruz L, Stephens C, Smith AJ, Georgiadis A, Thrasher AJ, Bainbridge JW, Seeliger MW, Ali RR. Long-term evaluation of retinal function in Prph2Rd2/Rd2 mice following AAV-mediated gene replacement therapy. *J Gene Med* 2003;5:757–64.

88 Bennett J, Ashtari M, Wellman J, Marshall KA, Cyckowski LL, Chung DC, McCague S, Pierce EA, Chen Y, Bennicelli JL, Zhu X, Ying GS, Sun J, Wright JF, Auricchio A, Simonelli F, Shindler KS, Mingozzi F, High KA, Maguire AM. AAV2 gene therapy readministration in three adults with congenital blindness. *Sci Transl Med* 2012;4:120ra15.

89 Maguire AM, Simonelli F, Pierce EA, Pugh EN Jr., Mingozzi F, Bennicelli J, Banfi S, Marshall KA, Testa F, Surace EM, Rossi S, Lyubarsky A, Arruda VR, Konkle B, Stone E, Sun J, Jacobs J, Dell'Osso L, Hertle R, Ma JX, Redmond TM, Zhu X, Hauck B, Zelenaia O, Shindler KS, Maguire MG, Wright JF, Volpe NJ, McDonnell JW, Auricchio A, High KA, Bennett J. Safety and efficacy of gene transfer for Leber's congenital amaurosis. *N Engl J Med* 2008;358:2240–8.

90 Bainbridge JW, Smith AJ, Barker SS, Robbie S, Henderson R, Balaggan K, Viswanathan A, Holder GE, Stockman A, Tyler N, Petersen-Jones S, Bhattacharya SS, Thrasher AJ, Fitzke FW, Carter BJ, Rubin GS, Moore AT, Ali RR. Effect of gene therapy on visual function in Leber's congenital amaurosis. *N Engl J Med* 2008;358:2231–9.

91 Jacobson SG, Cideciyan AV, Ratnakaram R, Heon E, Schwartz SB, Roman AJ, Peden MC, Aleman TS, Boye SL, Sumaroka A, Conlon TJ, Calcedo R, Pang JJ, Erger KE, Olivares MB, Mullins CL, Swider M, Kaushal S, Feuer WJ, Iannaccone A, Fishman GA, Stone EM, Byrne BJ, Hauswirth WW. Gene therapy for Leber congenital amaurosis caused by RPE65 mutations: safety and efficacy in 15 children and adults followed up to 3 years. *Arch Ophthalmol* 2011;130:9–24.

92 Hansen KD, Brenner SE, Dudoit S. Biases in Illumina transcriptome sequencing caused by random hexamer priming. *Nucleic Acids Res* 2010;38:e131.

93 Quail MA, Kozarewa I, Smith F, Scally A, Stephens PJ, Durbin R, Swerdlow H, Turner DJ. A large genome center's improvements to the Illumina sequencing system. *Nat Methods* 2008;5:1005–10.

94 Dohm JC, Lottaz C, Borodina T, Himmelbauer H. Substantial biases in ultra-short read data sets from high-throughput DNA sequencing. *Nucleic Acids Res* 2008;36:e105.

95 Kozarewa I, Ning Z, Quail MA, Sanders MJ, Berriman M, Turner DJ. Amplification-free Illumina sequencing-library preparation facilitates improved mapping and assembly of (G+C)-biased genomes. *Nat Methods* 2009;6:291–5.

96 Aird D, Ross MG, Chen WS, Danielsson M, Fennell T, Russ C, Jaffe DB, Nusbaum C, Gnirke A. Analyzing and minimizing PCR amplification bias in Illumina sequencing libraries. *Genome Biol* 2011;12:R18.