

ONLINE MUTATION REPORT

Mowat–Wilson syndrome and mutation in the zinc finger homeo box 1B gene: a well defined clinical entity

P Cerruti Mainardi, G Pastore, C Zweier, A Rauch

J Med Genet 2004;41:e16 (<http://www.jmedgenet.com/cgi/content/full/41/2/e16>). doi: 10.1136/jmg.2003.009548

Mowat *et al* in 1998 delineated a new syndrome characterised by a distinct facial phenotype, Hirschsprung disease (HSCR), microcephaly, and mental retardation; they also identified a locus at chromosome 2q21–q23.¹ The six children described were sporadic cases, and the authors suggested a contiguous gene syndrome or a dominant single gene disorder. Three further sporadic cases published earlier as having unclassified syndromic HSCR, Goldberg–Shprintzen syndrome, or 2q22–23 deletion,^{2–4} were recognised by Mowat *et al* having the same distinctive facial appearance as their patients. Kääriäinen *et al* reported five patients with a similar phenotype.⁵ Mutations in *ZFH1B* (*SIP1*) were identified by Wakamatsu *et al* in a patient with a translocation t(2;13)(q22;q22) and in another three patients, all with syndromic HSCR.⁶ Mutations in *ZFH1B* (*SIP1*) were also identified by Cacheux *et al*⁷ in two patients of Kääriäinen *et al*: patient 1 with a t(2;11)(q22.2;q21) and in patient 3; and in patients 1, 2, and 3 of Mowat *et al*.¹ Subsequently Yamada *et al* reported *ZFH1B* mutations in other patients with complex developmental disorders,⁸ as did Amiel *et al* in patients with syndromic Hirschsprung disease.⁹ Investigation of four patients by Zweier *et al*¹⁰ and one patient by Garavelli *et al*¹¹ showed the distinct phenotype and the mutation in *ZFH1B* (*SIP1*) and confirmed the syndrome described by Mowat *et al*.¹ Recently an article by Wilson *et al* reported 15 new patients with *ZFH1B* mutations, and a review of Mowat–Wilson syndrome was published by Mowat *et al*.^{12–13}

Although in total 45 cases with deletions or mutations in *ZFH1B* (*SIP1*) have been recorded,^{4–14} detailed clinical descriptions are rare. We report two new patients from Northern Italy with all the typical signs of the syndrome and with mutations in *ZFH1B* (*SIP1*).

CLINICAL DESCRIPTION

Patient 1

This boy was the first child of unrelated parents. The sister was healthy. He was born at 41 weeks' gestation with a birth weight of 3200 g (10th–25th centile), a length of 48 cm (10th), and a head circumference of 33 cm (3rd–10th). Hirschsprung disease (HSCR) was diagnosed on day 2; a colostomy was carried out on day 3 and closed at 8 months. He had serious constipation from the first months of life and also a high degree of vesicoureteric reflux. At 14 months, hypotonia and psychomotor developmental delay was observed. Because of facial abnormalities a karyotype was performed, with normal results. He developed seizures at 16 months, when EEG showed epileptic anomalies prevailing on the right hemisphere, and sodium valproate therapy was started.

On examination at 5 years of age, the boy showed several minor facial anomalies: fine hair, high forehead, frontal bossing, broad nasal bridge, medially flaring thick eyebrows,

Key points

- In 1998 a new syndrome characterised by a distinct facial phenotype, Hirschsprung disease (HSCR), microcephaly, and mental retardation was delineated by Mowat *et al*, who also identified a locus at chromosome 2q21–q23. In 2001, mutations in *ZFH1B* were reported by Wakamatsu *et al* in patients with syndromic HSCR, and by Cacheux *et al* in patients of Mowat *et al*. Zweier *et al* pointed out that “Mowat–Wilson” syndrome was a distinct and recognisable syndrome, caused by mutations in the *ZFH1B* gene, in which the presence of HSCR was not constant.
- We observed two new patients with all typical signs of Mowat–Wilson syndrome, which enabled us to confirm that it is typical and recognisable, like classical genetic syndromes, and finds its marker in *ZFH1B* (*SIP1*) gene mutation. The comparison with the other 45 patients with deletions or mutations in *ZFH1B* (*SIP1*) as reported up to now shows a striking resemblance of the facial features, and uniformity of the associated malformations as well as of clinical problems and severe mental retardation.
- We wish to highlight the importance of clinical recognition of the syndrome with or without HSCR in the selection of patients for cytogenetic and molecular analyses. An early diagnosis is also important for genetic counselling, to distinguish this syndrome from others with HSCR and autosomal recessive transmission, since patients with Mowat–Wilson syndrome so far reported have been sporadic cases.
- Our two patients with the same severe phenotype as the patients reported with large q22 deletions show that Mowat–Wilson syndrome is not a contiguous gene syndrome, and that truncating mutations of one allele of the *ZFH1B* gene involved in neural crest development result in this complex phenotype.
- The new heterozygous stop mutation Y293X in patient 2 is novel. Patient 1 shows a heterozygous stop mutation R695X, already reported in other 5 patients. Comparison of the clinical data of these six patients concerning the associated malformations demonstrates the phenotypic variability of a single mutation in Mowat–Wilson syndrome.

Abbreviations: HSCR, Hirschsprung disease

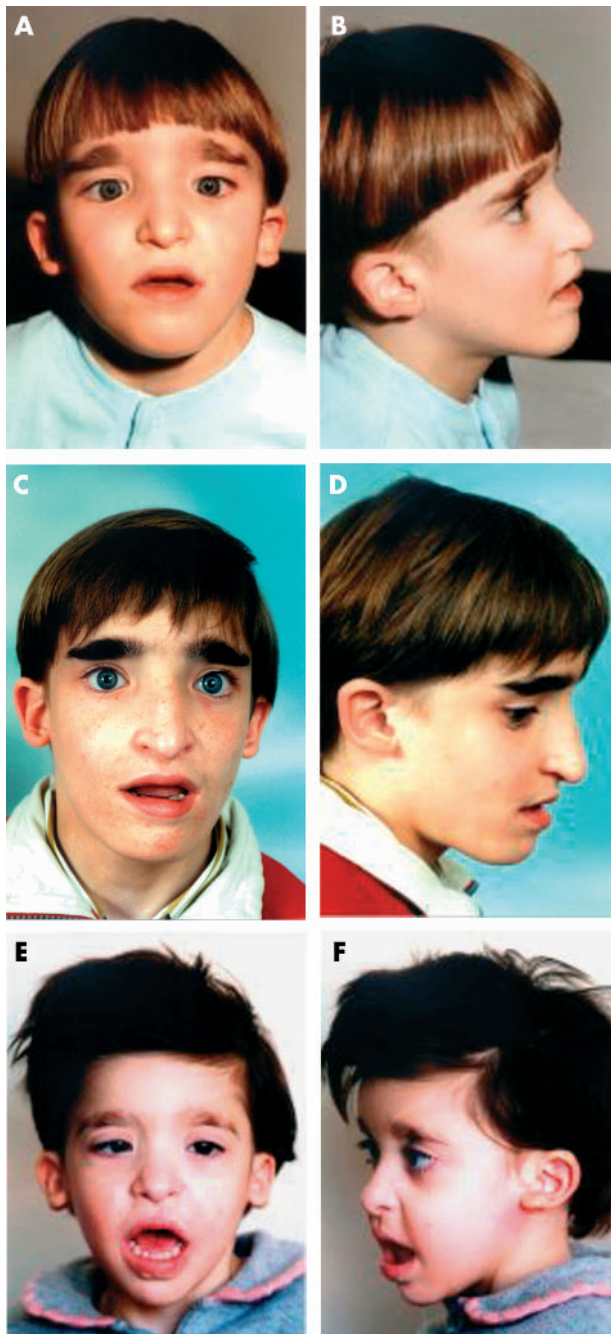

Figure 1 (A) and (B), patient 1 at age 5 years. (C) and (D), patient 1 at age 13 years and 8 months. (E) and (F), patient 2 at age 3 years and 5 months.

downward slanting palpebral fissures, hypertelorism, epicanthus, deepset blue eyes, small nose with prominent columella, open mouth, triangular jaw, prominent chin, and posterior lowset ears with uplifted lobes, shown in fig 1(A) and (B). He also presented a high arched palate, penoscrotal hypospadias with penis recurvation (treated surgically at 4 years 5 months), right cryptorchidism, pes planus with calcaneovalgus, mild pectus excavatum, long tapered fingers, single transverse palmar creases, microcephaly (48.5 cm, <3rd centile), and severe psychomotor retardation. Denver testing¹⁵ showed that he grasped at 15 months; he walked alone at 3 years; and he was affectionate and smiling, but had no speech. A cardiac systolic murmur was present. ECG was normal, but echocardiography showed

a mild fibrosis of the anterior leaflet of the tricuspid valve with slight valvular insufficiency. Seizures were frequent and resistant to treatment. MRI of the brain showed a marked hypoplasia of the corpus callosum and narrow cerebral ventriculi. Audiometric examination was normal; ocular fundus examination showed in the right eye an optic papilla with a grey pigmentary halo, whereas the left eye was normal. Standard karyotyping was repeatedly normal, and FRAXA mutation, Angelman syndrome, and metabolic diseases were excluded.

On the last examination at 13 years and 8 months, patient 1's weight was 29 kg (<3rd centile), his height was 138 cm (<3rd) (target >10th), and his head circumference was 50 cm (<3rd). A long face, horizontal palpebral fissures, less evident epicanthic folds, and abnormal maxillary incisors were observed. The other facial anomalies were unchanged, as shown in fig 1 (C) and (D). Thinness was present; pubertal development was advanced. No seizures had occurred from age 8 years; EEG showed non-specific anomalies. The severe psychomotor and mental retardation persisted. Denver testing¹⁵ revealed that the patient ran and walked up steps at 6 years; drank unaided at 8 years; was toilet trained with help at 8 years; and still had no speech.

Since we suspected that he had Mowat–Wilson syndrome, *ZFX1B* mutational analysis was performed.

Patient 2

This girl was the first child of unrelated parents. The brother was healthy. She was born at 41 weeks' gestation with a birth weight of 3700 g (75th centile), a length of 51 cm (75th), and a head circumference of 32 cm (3rd). Cyanosis and cardiac systolic murmur were present at birth, and echocardiogram showed Fallot's tetralogy with an absent pulmonary valve. Dysmorphism was observed but the karyotype was normal. At 20 days the patient had vomiting and abdominal distension; HSCR was diagnosed, and a colostomy was carried out at day 22. When, at 3 months, surgery for the Fallot's tetralogy was performed, agenesis of the pulmonary valve and severe dilation of pulmonary branches were found. At 11 months the colostomy was closed. At 1 year of age the patient developed recurrent seizures; EEG showed slow widespread anomalies prevalent on frontotemporal bilateral derivations, and phenobarbitone therapy was started. Ultrasound of the brain recorded hypoplasia of the corpus callosum. During the first year of life hypotonia and psychomotor retardation were observed.

On the last examination at 3 years and 5.5 months, the patient's weight was 11.3 kg (<3rd centile), length 93 cm (25th), and head circumference 43 cm (<3rd). She had fine hair, a high forehead, frontal bossing, prominent supraorbital ridges, medially flaring eyebrows, hypertelorism, deepset eyes, a small nose with a prominent columella, open mouth, prominent chin, and posterior lowset ears with uplifted lobes, shown in fig 1 (E) and (F). She also presented a high arched palate, long tapered fingers, single incomplete transverse palmar creases, and pes planus with calcaneovalgus. A cardiac systolic murmur persisted and seizures were recurrent. Cranial MRI confirmed hypoplasia of the corpus callosum. She presented a severe psychomotor retardation; Denver testing¹⁵ revealed that she sat "head steady" at 1 year, did not sit without support, grasped at 2.5 years, and turned to voice at 2 years and had no speech.

As the clinical picture was typical of Mowat–Wilson syndrome, *ZFX1B* mutational analysis was undertaken.

METHODS AND RESULTS

ZFX1B investigations

FISH analysis for exclusion of whole gene deletions was performed as described earlier,¹⁰ with normal results in both

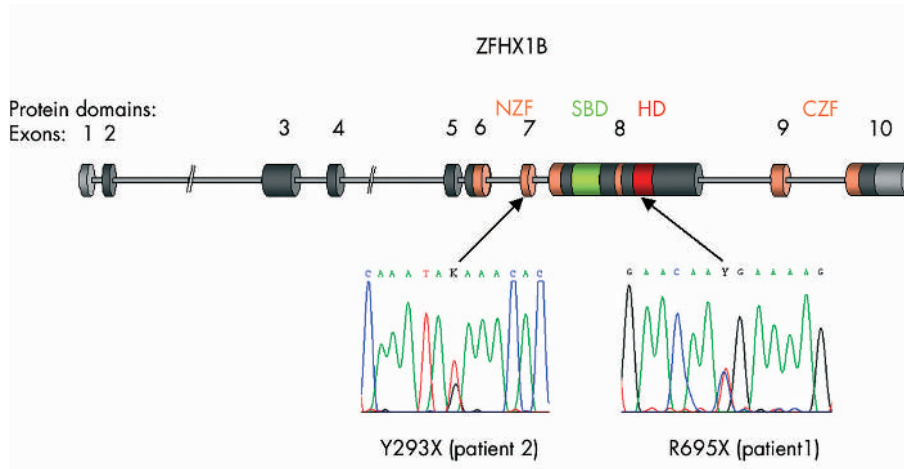


Figure 2 Scheme of *ZFH1B* exons and corresponding protein structure adapted from Zweier *et al.*,¹⁰ showing the position of the presented mutations. NZF, N-terminal zinc finger cluster; CZF, C-terminal zinc finger cluster; SBD, Smad binding domain; HD, homeodomain-like segment.

patients. Sequencing of the complete coding sequence of *ZFH1B*¹⁰ showed a new heterozygous exon 8 stop mutation nt2083 c-t (R695X) in patient 1, and a new heterozygous exon 7 stop mutation nt 879 t-g (Y293X) in patient 2 (fig 2).

In tables 1 and 2, clinical and molecular data on our two patients are compared with those of the 45 patients with deletion or mutation in *ZFH1B* (*SIP1*) so far reported.^{1 4-14}

DISCUSSION

These patients presented all the clinical features of Mowat–Wilson syndrome, as defined by Zweier *et al.*¹⁰ and Garavelli *et al.*,¹¹ and confirm that it is distinct and recognisable like classical genetic syndrome that finds its marker in *ZFH1B*

(*SIP1*) gene mutations. The clinical picture is different from that of Goldberg–Shprintzen syndrome,¹⁶ which is characterised by a different facial phenotype; commonly palpebral ptosis and cleft palate are commonly observed as well as generally milder mental retardation. Only two of at least 17 published cases supposed to have Goldberg–Shprintzen syndrome occurred sporadically, the majority of cases being sibs and/or offspring of consanguineous mating.^{2 16-23} Only recently a patient with suggested Goldberg–Shprintzen syndrome was investigated for *ZFH1B* mutations and was shown to have none.²⁴ The differential diagnosis is important for genetic counselling, because Goldberg–Shprintzen syndrome is most likely autosomally recessive, whereas all

Table 1 Mowat–Wilson syndrome and mutation in *ZFH1B*; clinical data.^{1 4-14}

Clinical features	1	2	Total patients(S)	% of total
Facial characteristics				
Sparse/fine hair	+	+	9/13(N)	69.2
High, broad forehead/frontal bossing	+	+	9/11	81.8
Medially flaring thick eyebrows	+	+	36/36	100.0
Hypertelorism	+	+	38/38	100.0
Strabismus	-	+	18/23	78.3
Deepset eyes	+	+	36/36	100.0
Epicanthus	+	-	8/13	61.5
Downward slanting palpebral fissures	+	+	11/15	73.3
Broad nasal bridge/saddle nose	+	+	42/43	97.7
Small nose, round tip/prominent columella	+	+	28/29	96.5
Open mouth	+	+	24/28	85.7
Prominent pointed chin/triangular jaw	+	+	40/40	100.0
Posterior lowset ears with uplifted lobes	+	+	36/36	100.0
Other malformations and problems				
HSCR	+	+	30/47	63.8
Seizures	+	+	35/46	76.1
Congenital heart disease	-	+	22/47	46.8
Agensis/hypoplasia of corpus callosum	+	+	15/33	45.4
Renal anomalies	+	-	10/27	37.0
Hypospadias	+	15 NR	12/25	48.0
Cryptorchidism	+	15 NR	11/25	44.0
Cleft submucous palate / high arched palate	+	+	10/27	37.0
Dermatoglyphic anomalies	+	+	8/9	88.8
Tapered fingers	+	+	16/19	84.2
Pes planus with calcaneovalgus	+	+	10/11	90.9
Mental retardation	+	+	47/47	100.0
Microcephaly (≤3rd centile at last follow up)	+	+	40/46	86.9
Hypotonia	+	+	25/26	96.2
Short stature (<3rd centile at last follow up)	+	-	12/29	41.4
Happy, affectionate personality	+	+	24/25	96.0

1, patient 1 (male); 2, patient 2 (female); S, all 47 were sporadic cases, 32 of whom were males and 15 females; N, number of patients for whom data were available; NR, not relevant.

Table 2 Clinical features of 47 patients and mutations/deletions of ZFH1B

Study	Patient Sex (A)	Age (A)	Gestation (G)	Birth weight (g), C	Birth length (cm), C	Birth CC (cm), C	Micro-cephaly (U)	Facial features (FF)	HSCR	Seizures	Heart defects	Callosum agenesis	Genital anomalies	Renal anomalies	W	MR	Mutation	Exon mutated
Mowat <i>et al</i> ¹	1	M	3	42	3950	75 th	55	97 th	35.5	50 th	3 rd	+	+	+	+	del(2)(q22-q23)	All	
Kääriäinen <i>et al</i> ⁵	2	M	4 1/2	?	3700	75 th	50	50 th	33	3 rd -10 th	3 rd	+	+	+	+	920delA	8	
Cacheux <i>et al</i> ⁷	3	F	3	?	4820	>97 th	52	90 th	34	25 th -50 th	<3 rd	+	+	+	+	594delC	6	
	4	M	3 1/2	?	3400	50 th	49.5	25 th	33.5	10 th	<3 rd	+	+	+	+	1421insA	8	
	5	M	9	33	1880	25 th	43	25 th	30.5	25 th	<3 rd	+	+	+	+	Translocation	int 2	
	6	F	8	38	3380	75 th	52	90 th -97 th	34.5	75 th	3 rd	+	+	+	+	1216delAC	8	
Lurie <i>et al</i> ⁴	7	M	2 1/2	?	4025	90 th	?	?	?	?	<3 rd	+	+	+	+	del(2)(q22-q23)	All	
Wakamatsu <i>et al</i> ⁶	8	F	6	40	3000	25 th	?	?	31.5	<3 rd	+ ^f	+	+	+	+	Deletion	All	
Yamada <i>et al</i> ⁶	9	F	18	41	3045	10 th -25 th	?	?	33	10 th	+	+	+	+	+	R549X	8	
	10	M	23	38	2820	25 th	?	?	31.5	3 rd	+	?	?	?	?	R695X	8	
	11	M	23	39	3200	25 th -50 th	?	?	31	<3 rd	+	?	?	?	?	11734delAACA	8	
	12	M	26	42	3570	25 th -50 th	?	?	?	?	+	?	?	?	?	R695X	8	
	13	M	28	40	3950	90 th	55	97 th	33	3 rd -10 th	+	?	?	?	?	R695X	8	
	14	M	23	40	3410	50 th	50	25 th -50 th	33	3 rd -10 th	+	+	?	?	?	R695X	8	
	15	M	25	39	3260	50 th	48	10 th -25 th	33	10 th	+	+	?	?	?	760insCA	6	
	16	F	4	36	2690	50 th	46.5	25 th -50 th	30.5	3 rd -10 th	+	+	NR	?	?	270delG	3	
	17	M	1 1/2	38	2960	25 th	47	10 th	32	3 rd	+	?	?	?	?	2178delTT	8	
Amiel <i>et al</i> ⁹	18	M	?	?	?	?	?	?	?	?	?	+	Hypospadias	?	?	?	935delG	8
	19	M	?	?	?	?	?	?	?	?	+	+	Cryptorchidism	VUR	?	?	1805delA	8
	20	F	?	?	?	?	?	?	?	?	+	+	NR	?	?	Deletion	All	
	21	F	?	?	?	?	?	?	?	?	+	+	NR	?	?	Deletion	All	
	22	M	?	?	?	?	?	?	?	?	+	+	Hypospadias	?	?	Deletion	All	
	23	F	?	?	?	?	?	?	?	?	+	+	Cryptorchidism	?	?	2453insT	8	
	24	F	?	?	?	?	?	?	?	?	+	+	NR	?	?	Deletion	All	
	25	F	?	?	?	?	?	?	?	?	+	+	NR	?	?	L562X	8	
Zweier <i>et al</i> ¹⁰	26	M	1 mo	40	3940	90 th	54	90 th	?	?	10 th	+	Cryptorchidism	+	+	3567insCC	10	
	27	M	6 mo	40	3600	50 th	54	90 th	?	?	<3 rd	+	+	+	+	1892delA	8	
	28	M	6 10mo	40	2670	10 th	47	3 rd	32	25 th	<3 rd	+	Cryptorchidism	+	+	553insTG	5	
	29	M	1 mo	37	2910	40 th	49	50 th	32.8	25 th -50 th	25 th -50 th	+	Hypospadias	+	+	S852X	8	
Garavelli <i>et al</i> ¹¹	30	M	1 mo	40	3750	75 th	51	50 th	34	25 th	10 th	+	Hypospadias	+	+	901delC	7	
Wilson <i>et al</i> ¹²	31	M	?	?	?	?	?	?	?	?	3 rd	+	Hypospadias	VUR,	?	+	S856X	8
	32	M	?	?	?	?	?	?	?	?	<3 rd	+	Hypospadias	Hydronephrosis	?	+	615-616delTG	6
	33	M	?	?	?	?	?	?	?	?	3 rd	+	Hypospadias	?	?	851-852delGC	7	
	34	M	?	?	?	?	?	?	?	?	3 rd	+	Cryptorchidism,	VUR	?	+	2661delC	8
	35	F	?	?	?	?	?	?	?	?	<<3 rd	+	NR	?	?	3350delC	10	
	36	F	?	?	?	?	?	?	?	?	10 th -25 th	+	NR	?	?	2967-85delGT	9	
	37	M	?	?	?	?	?	?	?	?	<<3 rd	+	?	?	?	219insC	3	
	38	M	?	?	?	?	?	?	?	?	3 rd	+	Webbed penis	?	?	1366insT	6	
	39	F	?	?	?	?	?	?	?	?	25 th	+	NR	?	?	S142X	5	

Table 2 Continued

Study	Patient Sex (A)	Age (A)	Gestation (G)	Birth weight (g), C	Birth length (cm), C	Birth CC (cm), C	Microcephaly (L)	Facial features (FF)	HSCR	Seizures	Heart defects	Callosum agenesis	Genital anomalies	Renal anomalies	W	MR	Mutation	Exon mutated
	40	M ?	?	?	?	?	-	+	-	+	+	?	Hypospadias Cryptorchidism	VUR	?	+	R695X	8
	41	M ?	?	?	?	?	25 th <3 rd	+	+	-	-	?	-	?	?	+	G461X	8
	42	M ?	?	?	?	?	<3 rd	+	-	+	+	?	Cryptorchidism, Bilateral PUJ hooded prepuce	Bilateral PUJ	?	+	R343X	8
	43	M ?	?	?	?	?	<3 rd	+	-	-	+	-	Hypospadias	-	?	+	2335delA	6
	44	F ?	?	?	?	?	<3 rd	+	-	+	+	-	NR	-	?	+	1666delAAGA	8
	45	M ?	?	?	?	?	<3 rd	+	-	-	-	-	-	?	?	+	IVS2+1G-A	int 2
Present study	46	M	13 8mo	3200	10 th -25 th	48	3 rd -10 th	+	+	+	-	+	Hypospadias Cryptorchidism	VUR	3	+	R695X	8
	47	F	3 5mo	3700	75 th	51	3 rd	+	+	+	+	+	NR	-	-	+	Y293X	7

F, female; M, male; +, presence of clinical sign; -, absence of clinical sign; ?, not available; NR, not relevant; A, years; G, weeks; CC, cranial circumference (cm); C, centiles; L, centile at last follow up; N, microcephaly not otherwise specified; FF, facial features as described by Mowat *et al.*; CON, constipation; VUR, vesicoureteric reflux; PUJ, pelviureteric junction obstruction; W, walking age (years); MR, mental retardation.

patients with Mowat–Wilson syndrome so far reported have been sporadic cases.

Mowat–Wilson syndrome patients, besides having a distinct facial phenotype and severe mental retardation, often present HSCR, epilepsy, and major and minor malformations which suggest the diagnosis and direct analyses to a rearrangement in 2q22-q23 or, if not present, in the gene mutation. The presence of HSCR is a strong cross reference marker, and the importance of a careful clinical assessment in all newborns with HSCR has been outlined recently.²⁵ On the other hand, Zweier *et al*¹⁰ found the *ZFH1B* mutation in all four patients with typical facial phenotype, two having and two not having HSCR. The mutation was not found in the fifth patient with syndromic HSCR but different facial anomalies. The authors conclude that HSCR is one of the multiple variable anomalies of Mowat–Wilson syndrome.

Wakamatsu *et al*⁶ identified a *ZFH1B* deletion in a patient with translocation t(2;13)(q22;q22), and *ZFH1B* mutations in another three patients with syndromic HSCR selected from a series of 200 patients with HSCR. The same authors¹⁴ in a study of 10 patients with mutation in *ZFH1B* (including the four patients previously described)⁶ found HSCR only in four out of 10 (two did not have HSCR, four had constipation), and they concluded that the mutation in *ZFH1B* caused a complex developmental disorder with a great variety of clinical features. They¹⁴ also noticed a strong resemblance of these patients to those described by Mowat *et al.*¹ Amiel *et al.*⁹ in a study of the *ZFH1B* mutation in 19 patients with syndromic HSCR selected from 250 patients with HSCR, showed a mutation in eight patients (one of them with constipation only). They emphasised the fact that Mowat *et al*¹ first recognised the distinct clinical features of these patients and identified a locus at chromosome 2q22-23. Recently Wilson *et al*¹² and Mowat *et al*¹³ reported 15 new patients with *ZFH1B* mutations and provided a detailed discussion on the clinical features and the change in facial phenotype with age in this syndrome.

The comparison of the data on our patients with those on the 45 patients with mutation in *ZFH1B* already reported in the literature (tables 1 and 2), showed that the main facial features (medially flaring thick eyebrows, hypertelorism deepset eyes, strabismus, broad nasal bridge, rounded nasal tip, open mouth, prominent pointed chin, and lowset ears with uplifted lobes) described by Mowat *et al*¹³ were present in most of the patients (table 1). These observations, together with the published photographs,^{1 5 6 8-14} demonstrated a striking resemblance in facial features. Furthermore, in these patients there was a high frequency of some major malformations, such as HSCR (63.8%), heart defects (46.8%), agenesis of the corpus callosum (45.4%), and seizures (76.1%) (table 1). Minor malformations were frequent but not invariably reported. The mental retardation, usually severe, was constant; the delay in the acquisition of motor skills was more variable (table 2). The male/female ratio was 2.13/1, the difference being statistically significant (p<0.01) compared with the general population. The patients presented normal weight and length at birth. The cranial circumference at birth was close to or below the 3rd centile in 11 out of 19 patients (58%) (and in general one centile less than that of weight and height), whereas 40 out of 46 patients (86.9%) had a cranial circumference on or below the 3rd centile at the last follow up (tables 1 and 2). On the grounds of these observations we want to highlight the importance of clinical recognition of the syndrome with or without HSCR, in order to select cases for cytogenetic and molecular analyses.

Whereas our patient 1's mutation R695X had already been reported in a patient with syndromic HSCR,⁶ in three patients

with complex developmental disorder,⁸ and in one patient of Wilson *et al*,¹² the mutation Y293X in our patient 2 was novel. The latter would result in a premature translational stop within the N-terminal zinc finger cluster of the putative protein, which therefore would miss the Smad binding domain, the homeodomain, and the C-terminal zinc finger cluster. Our patient with the R695X mutation had HSCR, as did one of the reported cases, but of the remaining four patients one did not have HSCR and three had moderate to severe constipation only. Congenital heart defects were reported in one of them. Agenesis of corpus callosum was seen in our patient, and excluded in the only reported patient who had had brain studies. Thus, some phenotypic variability of a single mutation is demonstrated in Mowat–Wilson syndrome. Genotype-phenotype correlation in large scale deletions have been discussed elsewhere.²⁶

These two patients, with the same severe phenotype as the patients reported with large q22 deletions, show that Mowat–Wilson syndrome is not a contiguous gene syndrome, and that truncating mutations of one allele of the *ZFH1B* gene involving neural crest development result in this complex phenotype. Nevertheless, it is noteworthy that an atypical phenotype with late adult onset severe constipation and mild mental retardation in the absence of specific facial anomalies, seizures, and other malformations might be caused by non-truncating mutations, such as a 3 bp in frame deletion.²⁷

A Mowat–Wilson syndrome mutation database will be available at following URL: <http://www.humgenet.uni-erlangen.de/2kforschung/mowat-syndrom.html>

ACKNOWLEDGEMENTS

We wish to thank M Godi, research assistant, and the Fondazione Cassa di Risparmio di Vercelli for its support. We are grateful to the families for their cooperation.

Authors' affiliations

P Cerruti Mainardi, G Pastore, Pediatric Department and Genetics Unit, S. Andrea Hospital, Vercelli, Italy

C Zweier, A Rauch, Institute of Human Genetics, Friedrich Alexander University of Erlangen-Nuremberg, Erlangen, Germany

A Mowat–Wilson syndrome mutation database will be available at following URL: <http://www.humgenet.uni-erlangen.de/2kforschung/mowat-syndrom.html>

Correspondence to: Dr P Cerruti Mainardi, Divisione di Pediatria – Servizio di Genetica, Ospedale S. Andrea, Corso Abbiate 21, 13100 Vercelli, Italy; pcerruti@net4u.it

Received 11 April 2003

Accepted 3 June 2003

REFERENCES

- Mowat DR, Croaker GDH, Cass DT, *et al*. Hirschsprung disease, microcephaly, mental retardation, and characteristic facial features: delineation of a new syndrome and identification of a locus at chromosome 2q22-q23. *J Med Genet* 1998;**35**:617–23.
- Hurst JA, Markiewicz M, Kumar D, *et al*. Unknown syndrome: Hirschsprung's disease, microcephaly, and iris coloboma: a new syndrome of defective neuronal migration. *J Med Genet* 1988;**25**:494–7.
- Tanaka H, Ito J, Cho K, *et al*. Hirschsprung disease, unusual face, mental retardation, epilepsy, and congenital heart disease: Goldberg-Shprintzen syndrome. *Pediatr Neurol* 1993;**9**:479–81.
- Lurie IW, Supowitz KR, Rosenblum-Vos LS, *et al*. Phenotypic variability of del(2)(q22-q23): report of a case and review of the literature. *Genet Couns* 1994;**5**:11–14.
- Kääriäinen H, Wallgren-Pettersson C, Clarke A, *et al*. Hirschsprung disease, mental retardation and dysmorphic facial features in five unrelated children. *Clin Dysmorphol* 2001;**10**:157–63.
- Kamakatsu N, Yamada Y, Yamada K, *et al*. Mutations in *SIP1*, encoding Smad interacting protein-1, cause a form of Hirschsprung disease. *Nat Genet* 2001;**27**:369–70.
- Cacheux V, Dastot Le Moal F, Kääriäinen H, *et al*. Loss-of-function mutations in *SIP1* Smad interacting protein 1 result in a syndromic Hirschsprung disease. *Hum Mol Genet* 2001;**10**:1503–10.
- Yamada K, Yamada Y, Nomura N, *et al*. Nonsense and frameshift mutations in *ZFH1B*, encoding Smad-interacting protein 1, cause a complex developmental disorder with a great variety of clinical features. *Am J Hum Genet* 2001;**69**:1178–85.
- Amiel J, Espinosa-Parrilla Y, Steffann J, *et al*. Large-scale deletions and *SMAD1P1* truncating mutations in syndromic Hirschsprung disease with involvement of midline structures. *Am J Hum Genet* 2001;**69**:1370–7.
- Zweier C, Albrecht B, Mitulla B, *et al*. "Mowat-Wilson" syndrome with and without Hirschsprung disease is a distinct, recognizable multiple congenital anomalies-mental retardation syndrome caused by mutations in the Zinc Finger Homeo Box 1 B gene. *Am J Med Genet* 2002;**108**:177–81.
- Garavelli L, Donadio A, Zanacca C, *et al*. Hirschsprung disease, mental retardation, characteristic facial features, and mutation in the gene *ZFH1B* (*SIP1*): confirmation of the Mowat-Wilson syndrome. *Am J Med Genet* 2003;**116A**:385–8.
- Wilson M, Mowat D, Dastot-LeMoal F, *et al*. Further delineation of the phenotype associated with heterozygous mutations in *ZFH1B*. *Am J Med Genet* 2003;**119**(A):257–65.
- Mowat DR, Wilson MJ, Goossens M. Mowat-Wilson syndrome. *J Med Genet* 2003;**40**:305–10.
- Nagaya M, Kato J, Niimi N, *et al*. Clinical features of a form of Hirschsprung's disease caused by a novel genetic abnormality. *J Pediatr Surg* 2002;**37**:1117–22.
- Frankenburg WK, Dodds JB, Archer P, *et al*. The Denver II: a major revision restandardization of the Denver Developmental Screening Test. *Pediatrics* 1992;**89**:91–7.
- Goldberg RB, Shprintzen RJ. Hirschsprung megacolon and cleft palate in two sibs. *J Craniofac Genet Dev Biol* 1981;**1**:185–9.
- Brunoni D, Joffe R, Farah LM, *et al*. Syndrome identification case report 92: Hirschsprung megacolon, cleft lip and palate, mental retardation, and minor congenital malformations. *J Clin Dysmorphol* 1983;**1**:20–2.
- Kumasaka K, Clarren SK. Familial patterns of central nervous system dysfunction, growth deficiency, facial clefts and congenital megacolon: a specific disorder? *Am J Med Genet* 1988;**31**:465–6.
- Breslau L, Laan L. Facial cleft and congenital megacolon: a specific disorder? *Am J Med Genet* 1989;**34**:613.
- Halal F, Morel J. The syndrome of Hirschsprung disease, microcephaly, unusual face, and mental retardation. *Am J Med Genet* 1990;**37**:106–8.
- Yomo A, Taira T, Kondo I. Goldberg-Shprintzen syndrome: Hirschsprung disease, hypotonia, and ptosis in sibs. *Am J Med Genet* 1991;**41**:188–91.
- Fryer AE. Goldberg-Shprintzen syndrome: report of a new family and review of the literature. *Clin Dysmorphol* 1998;**7**:97–101.
- Brooks AS, Breuning MH, Osinga B, *et al*. A consanguineous family with Hirschsprung disease, microcephaly, and mental retardation (Goldberg-Shprintzen syndrome). *J Med Genet* 1999;**36**:485–9.
- Silengo M, Ferrero GB, Tornetta L, *et al*. Pachygyria and cerebellar hypoplasia in Goldberg-Shprintzen syndrome. *Am J Med Genet* 2003;**118**(A):388–90.
- Amiel J, Lyonnet S. Hirschsprung disease, associated syndromes, and genetics: a review. *J Med Genet* 2001;**38**:729–39.
- Zweier C, Temple IK, Beemer F, *et al*. Characterization of deletions of the *ZFH1B* region and genotype-phenotype analysis in Mowat-Wilson syndrome. *J Med Genet* 2003;**40**:601–5.
- Yoneda M, Fujita T, Yamada Y, *et al*. Late infantile Hirschsprung disease-mental retardation syndrome with a 3-bp deletion in *ZFH1B*. *Neurology* 2002;**59**:1637–40.



Mowat–Wilson syndrome and mutation in the zinc finger homeo box 1B gene: a well defined clinical entity

P Cerruti Mainardi, G Pastore, C Zweier and A Rauch

J Med Genet 2004 41: e16
doi: 10.1136/jmg.2003.009548

Updated information and services can be found at:
<http://jmg.bmj.com/content/41/2/e16>

These include:

References

This article cites 25 articles, 8 of which you can access for free at:
<http://jmg.bmj.com/content/41/2/e16#BIBL>

Email alerting service

Receive free email alerts when new articles cite this article. Sign up in the box at the top right corner of the online article.

Topic Collections

Articles on similar topics can be found in the following collections

[Calcium and bone](#) (307)
[Clinical diagnostic tests](#) (356)
[Colon cancer](#) (131)
[Epilepsy and seizures](#) (197)
[Neurogastroenterology](#) (21)
[Clinical genetics](#) (257)
[JMG Online mutation reports](#) (168)

Notes

To request permissions go to:
<http://group.bmj.com/group/rights-licensing/permissions>

To order reprints go to:
<http://journals.bmj.com/cgi/reprintform>

To subscribe to BMJ go to:
<http://group.bmj.com/subscribe/>