

## REVIEW ARTICLE

## Mowat-Wilson syndrome

D R Mowat, M J Wilson, M Goossens

*J Med Genet* 2003;**40**:305–310

MWS is a multiple congenital anomaly syndrome, first clinically delineated by Mowat *et al* in 1998. Over 45 cases have now been reported. All patients have typical dysmorphic features in association with severe intellectual disability, and nearly all have microcephaly and seizures. Congenital anomalies, including Hirschsprung disease (HSCR), congenital heart disease, hypospadias, genitourinary anomalies, agenesis of the corpus callosum, and short stature are common. The syndrome is the result of heterozygous deletions or truncating mutations of the *ZFHX1B* (*SIP1*) gene on chromosome 2q22.

features. In infancy (fig 1), there is a square shaped face with a prominent but narrow triangular chin, hypertelorism, deep set but large eyes, broad nasal bridge, saddle nose, prominent, rounded nasal tip, open mouth, full or everted lower lip, posteriorly rotated ears, and large uplifted ear lobes with a central depression. The configuration of the ear lobes, which have been described as like “orechiette pasta” or “red blood corpuscles” in shape, is a consistent and easily recognisable feature (fig 2).

In childhood (fig 3A), the face lengthens and the chin becomes more prominent. The eyebrows are often broad and horizontal with a wide medial separation. The columella becomes more obvious. The vermilion border often has an upper case “M” shape, such that the upper lip is full centrally but thins rapidly laterally. The children commonly have a smiling, open mouthed expression, and drooling is a significant feature in some. In children with blue eyes, patchy clumps of darker iris pigment occur, prompting the description of heterochromia of the irides.

In adolescents and adults the face is long with prognathism and a long, pointed or “chiselled” chin. The nasal tip lengthens and overhangs the philtrum, while the upper-mid portion of the nasal profile becomes convex (fig 3B).

**Neurological**

All subjects with MWS have at least moderate and usually severe intellectual disability, although formal IQ studies have not generally been reported. In our experience, most patients have a happy demeanour with frequent smiling. Speech is absent or restricted to a few words and is disproportionately delayed compared to comprehension. Some patients communicate successfully with signing. The children are usually hypotonic in the first few years of life, with delayed motor milestones. Typically they will cruise or stand holding on to furniture but are late to walk independently. The mean age of walking in our series was ~4 years but a proportion remained non-ambulatory. The gait is wide based and the arms are often held flexed at the elbows, with hands up. This stance, combined with the smiling face, has led to a suggested diagnosis of Angelman syndrome in some patients.

Most patients have had seizures (90%) or an abnormal EEG. The onset of seizures is usually in the second year of life, although they may begin in infancy or late childhood. The seizures can be varied in nature although myoclonic seizures have not been seen. In some cases the seizures have been resistant to treatment in childhood, but appear to be more easily managed in adolescents and adults.

In 1998, Mowat *et al*<sup>1</sup> described six patients with a mental retardation syndrome recognised by its characteristic facial appearance in association with Hirschsprung disease (HSCR). One of their patients had a cytogenetic deletion of 2q22-23 and they noted a previously published patient with a 2q22 deletion and similar clinical features. Based on this they proposed that this syndrome was either caused by microdeletion in chromosome 2q22-2q23 or a de novo mutation of a gene within this region. In 2001, the cause of this syndrome was found to be deletions or intragenic mutations of the *ZFHX1B* gene.<sup>2,3</sup> To date, 45 microdeletion/mutation positive cases have been reported.<sup>2-10</sup> Several other clinical reports published before the *ZFHX1B* gene discovery describe patients with syndromic HSCR who probably also have this syndrome.<sup>11,12</sup> All mutation positive cases show a similar facial appearance to the original patients.<sup>1-12</sup> Although most patients were ascertained on the basis of HSCR, several series have now reported mutations in patients without HSCR.<sup>4,6,8,10</sup> Recognition of the characteristic facies with or without Hirschsprung disease (HSCR) has important implications for genetic counselling. All reported cases of this syndrome have been sporadic, resulting from de novo deletion or heterozygous mutation of the *ZFHX1B* gene. It is important to distinguish this syndrome from the Goldberg-Shprintzen syndrome,<sup>16</sup> which has some clinical overlap but may have an autosomal recessive basis. Although the molecular basis of Goldberg-Shprintzen syndrome has not yet been established, characterisation of the *ZFHX1B* gene suggests clinical and genetic heterogeneity for the phenotypes of HSCR associated with mental retardation and microcephaly.

**CLINICAL FEATURES (TABLE 1)****Facial phenotype**

All our cases and those published cases where a photograph is provided show similar facial

See end of article for authors' affiliations

Correspondence to:  
Dr D Mowat, Department  
of Medical Genetics,  
Sydney Children's  
Hospital, High Street,  
Randwick, NSW 2031,  
Australia;  
[d.mowat@unsw.edu.au](mailto:d.mowat@unsw.edu.au)

**Table 1** Clinical features in patients with deletion or mutation of the *ZFH1B* gene

	Our series (n=21)	Lurie <i>et al</i> <sup>1</sup> (n=1)	Amiel <i>et al</i> <sup>2</sup> (n=8)	Yamada <i>et al</i> <sup>3</sup> (n=10)	Zweier <i>et al</i> <sup>4</sup> (n=4)	Garavelli <i>et al</i> <sup>5</sup> (n=1)	Frequency (n=45)
Male/female	15/6	M	3/5	7/3	4/0	M	31/14
Typical face (photograph seen)	21/21	1/1	5/5	5/5	3/3	1/1	100%
Moderate to severe MR	21	1/1	8/8	10/10	4/4	1/1	100%
Seizures/abn EEG	15/3	1/1	6/7	8/10	3/4	1/1	90%
Microcephaly (<3rd centile)	16/20	1/1	7/7	10/10	2/4	0/1	84%
HSCR proven	13/21	1/1	7/8	4/10	2/4	1/1	
Abnormal male genitalia	11/15	0/1	2/4	Not stated	1/4	1/1	
Short stature (<3rd centile)	8/18	1/1	Not stated	Not stated	3/4	0/1	50%
Congenital heart anomaly	9/21	1/1 AC	5/8	3/10	3/4	0/1	47%
Agenesis of corpus callosum	5/16	?	6/8	1/4	1/3	?	42%
Renal anomaly	6/16	0/1	2/4	Not stated	Not stated	Not stated	38%

### Growth/musculoskeletal

Growth parameters at birth, including head circumference, are usually in the normal range. Postnatal short stature (< or =3rd centile) is usual, although several patients have normal stature, and one of our adult patient's height is on the 90th centile. Microcephaly is sometimes present at birth, but more often becomes apparent in infancy. Not all patients are microcephalic.

Most subjects are of slender build. The fingers are slender and tapered in childhood, with prominence of the interphalangeal joints developing in adolescence and adulthood. The feet usually show mild calcaneovalgus deformity and long toes. One patient has broad halluces and another has unilateral duplication of the hallux.<sup>8</sup>

### Hirschsprung disease

Hirschsprung disease was present in 28 of the 45 published cases (table 2). The penetrance for HSCR in males was 65% (11/31), for females 57% (8/14), and 62% for the total group. The male:female ratio of those with HSCR was 2.5:1, and in those without HSCR was 1.8:1. The data on the length of the aganglionic segment is incomplete in published reports. Long segment and short segment HSCR is described in males and females. Females may be more likely to have long segment HSCR than males.<sup>8</sup> The male preponderance of published cases may be because of biased ascertainment, as males may be more likely to manifest HSCR.<sup>13</sup> Of the 17 cases without HSCR, five are reported to have severe constipation not investigated by rectal biopsy. It is possible that these patients could have very short segment HSCR, as was the case in one of our patients.<sup>13</sup> It is now well established that *ZFH1B* mutations can lead to a mental retardation/MCA syndrome without HSCR,<sup>4-6 8 10</sup> but it is likely that at present the syndrome is under-recognised in this group.

### Congenital heart disease

Congenital heart disease has been reported in 45% of patients with MWS. The heart anomalies reported include patent ductus arteriosus (5), atrial septal defect (4), ventricular septal defect (3), tetralogy of Fallot (3), pulmonary atresia (1), pulmonary stenosis (3), aortic coarctation (2), bicuspid aortic valve (1), and aortic valve stenosis (1).<sup>1 4-6 8 9 15</sup>

### Genitourinary anomalies

Genitourinary anomalies are common in MWS. Anomalies described include hypospadias (9), "webbed penis" (3), bifid scrotum (2), cryptorchidism/undescended testes (6), duplex kidney (1), pelvic kidney (1), vesicoureteric reflux (5), and hydronephrosis (2). Hypospadias is a common finding in males. In 24 patients where this information was available, hypospadias was present in 60% of patients (15/25). So far, no

girls with renal tract anomalies have been reported, but many have not had the relevant imaging studies.<sup>1 4 5 7 8 15</sup>

### Cerebral structural anomalies

Microcephaly is a common but not invariable feature, present in 84% of reported cases. Cerebral anomalies described include total or partial agenesis of the corpus callosum (13/31=42%), cerebral atrophy (7), poor hippocampal formation, and frontotemporal hypoplasia (3) with temporal dysplasia. Not all published cases have had cranial imaging so these findings may be under-represented.<sup>1 4-6 8 15</sup>

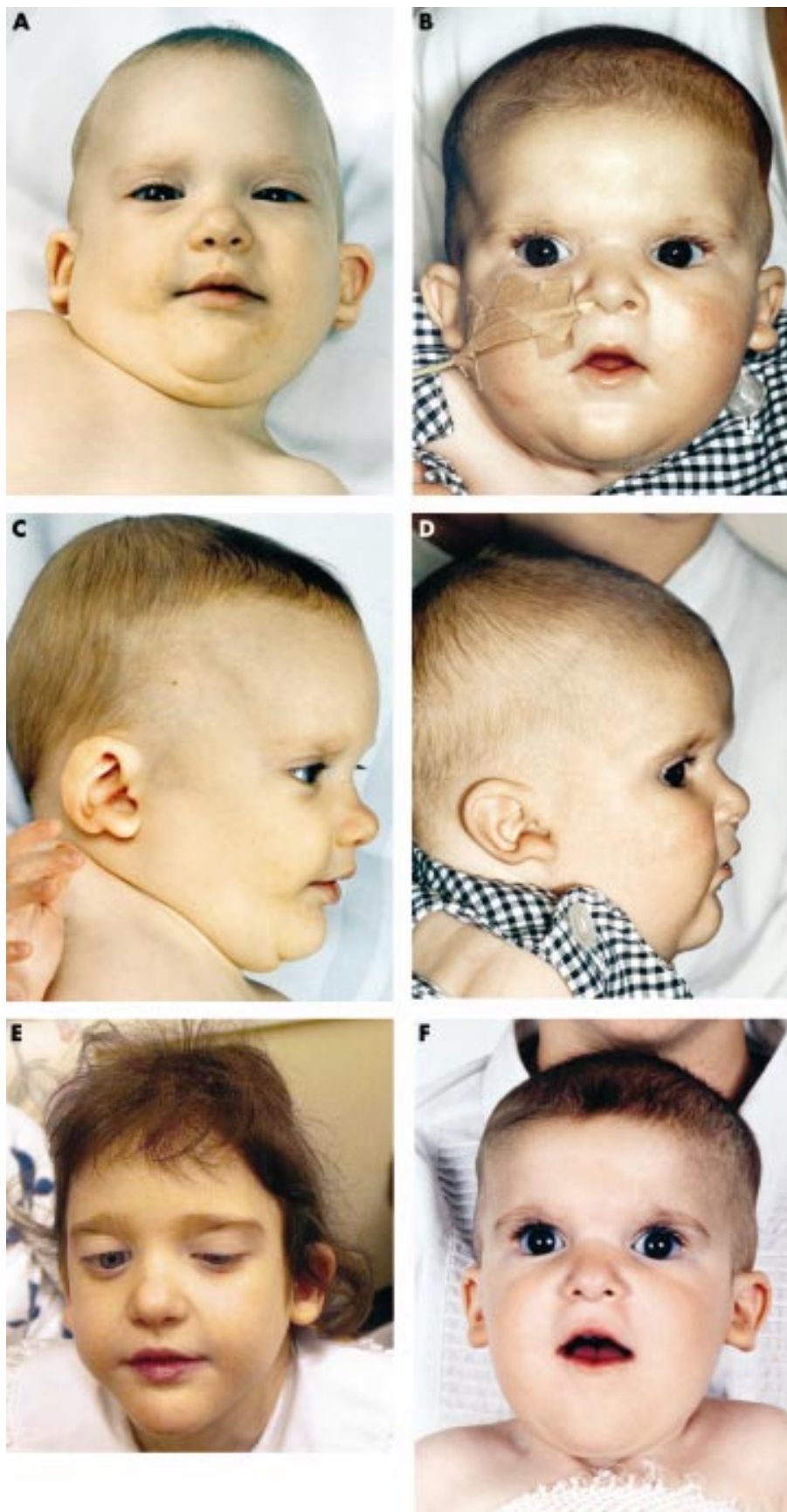
### Other clinical features

Bifid uvula/submucous cleft was reported in three of our patients. A high arched palate is often present, possibly secondary to hypotonia. Pyloric stenosis has been reported in three patients. Early "nystagmus" owing to fixation difficulties is frequently reported in infancy, but this resolves. Many patients have convergent strabismus. One patient has unilateral ptosis but none has an ocular coloboma. Some patients with blue irides have shown dark pigment clumps in the irides, described as heterochromia irides by some authors. No patient has had sensorineural deafness. Wilson *et al*<sup>8</sup> described one patient who gradually developed widespread "raindrop" depigmentation in the truncal region, of uncertain cause.

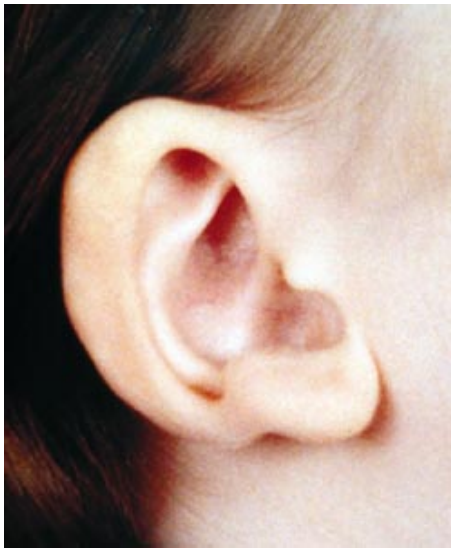### DIFFERENTIAL DIAGNOSIS

The series reported by Amiel *et al*<sup>2</sup> suggests that there is genetic heterogeneity for syndromic HSCR as only eight of the 19 patients they selected with microcephaly/MR/HSCR were found to have deletion or mutation of the *ZFH1B* gene. Goldberg-Shprintzen syndrome (GSS) is another form of syndromic HSCR with microcephaly and MR.<sup>16</sup> Although there is considerable overlap, the spectrum of the clinical features and the facial dysmorphism in GSS appear to be different from MWS. Features more commonly described in GSS include cleft palate, ptosis, synophrys, arched eyebrows, curled eyelashes, and ocular coloboma.<sup>11 12 14 16-22</sup> The underlying basis of GSS may be autosomal recessive, as sib recurrence and consanguinity is reported, but the molecular basis remains unclear. So far, no information about *ZFH1B* gene analysis in patients with definite GSS has been reported.

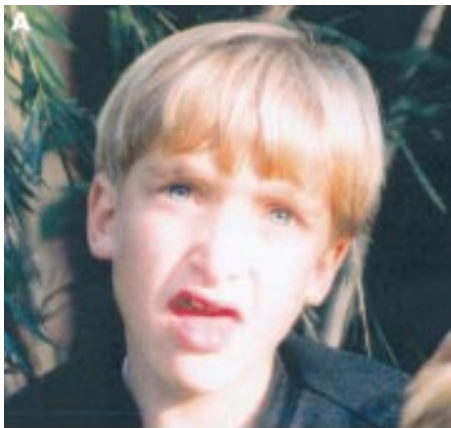Other conditions causing mental retardation and HSCR include chromosomal deletions involving loci of known HSCR causing genes (del 10q11, del 13q22) and Waardenburg type IV (*SOX10*), Smith-Lemli-Opitz, Bardet-Biedl, and BRESHEK syndromes.<sup>13</sup> Patients with HSCR and hypospadias should have 7-dehydrocholesterol levels performed to exclude Smith-Lemli-Opitz syndrome.



**Figure 1** Facial appearance in infancy and childhood of case 6<sup>o</sup> (421 ins A S481X) and case 5<sup>o</sup> (594 del C S211X).



**Figure 2** Characteristic appearance of the posteriorly rotated ears with an uplifted ear lobe and central depression ("corpuscular-like").



**Figure 3** Facial appearance of case 15<sup>8</sup> (425 C to S142X) in childhood (A) and adolescence (B).

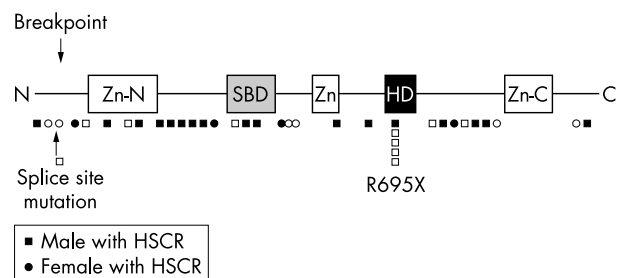
Some patients with MWS have been thought to have Angelman syndrome,<sup>23</sup> based on the presence of severe MR, seizures, ataxia, microcephaly, prominent jaw, and a happy behavioural phenotype. One patient with unilateral duplica-

**Table 2** Sex ratio and penetrance for HSCR in MWS patients

HSCR	Males	Females	Total
+	20 (65%)	8 (56%)	28
-	11 (35%)	6 (44%)	17
All	31	14	45

**Table 3** *ZFH1B* gene abnormalities causing MWS<sup>1-9</sup>

Cytogenetic abnormality	
Translocation	1
Translocation with deletion	1
Deletion	
Standard	2
High resolution	1
Microdeletions	3
Frameshift/nonsense mutations	36
Splice site mutation	1
Total	45

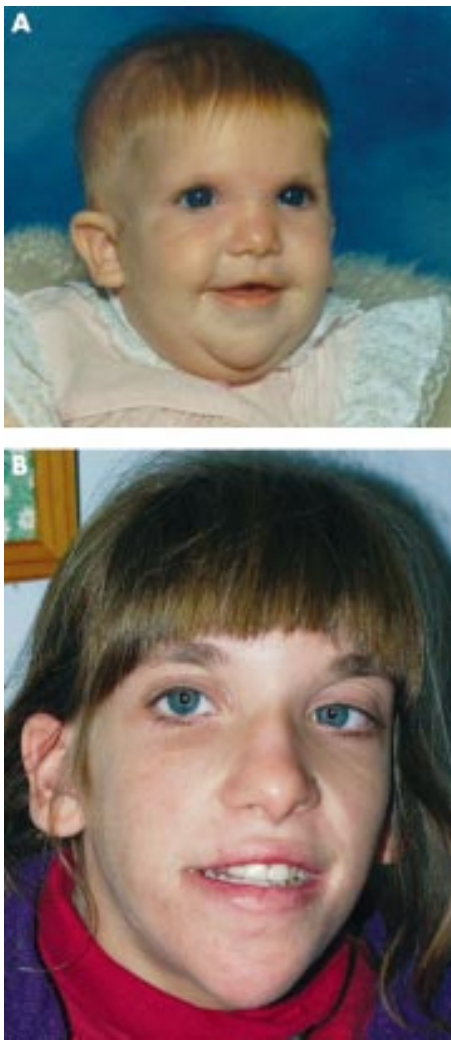

**Figure 4** Schematic representation of the SIP1 protein showing the predicted sites of protein truncation from identified mutations. Zn=N amino terminal zinc finger, SBD=Smad binding domain, Zn=zinc finger, HD=homeobox domain, Zn-C=carboxy terminal zinc finger.

tion of the hallux and agenesis of the corpus callosum was previously diagnosed as having the acrocallosal syndrome.<sup>8</sup>

### THE *ZFH1B* GENE

Mowat-Wilson syndrome was initially localised to the chromosome 2q22-23 region, based on two patients with interstitial deletions in this region.<sup>1,9</sup> In 2001, Wakamatsu *et al*<sup>2</sup> identified the *SIP1* gene (later designated *ZFH1B*) within a 5 kb microdeletion associated with a translocation involving 2q22 in a patient with characteristic features and confirmed its causative role by identification of intragenic mutations in three further patients with similar syndromic HSCR. Cacheux *et al*<sup>3</sup> independently identified a patient with a (2;11) translocation disrupting the *SIP1* gene, and found intragenic mutations in a further four cases, including three of the originally reported patients.<sup>1,5</sup> Amiel *et al*<sup>5</sup> screened 19 patients with HSCR/MR/microcephaly, selected from cohort of 250 patients with HSCR, and found microdeletions or mutations of the *ZFH1B* gene in eight. All of the patients with identified mutations had the typical dysmorphic features and seven had HSCR. Yamada *et al*<sup>6</sup> described mutations in six patients with the dysmorphic phenotype, but without HSCR. Zweier *et al*<sup>4</sup> identified mutations in two patients without HSCR and Wilson *et al*<sup>8</sup> described a further six patients without HSCR. These reports confirmed that HSCR is not an essential feature of mutations in *ZFH1B*. Finally, several patients have now



**Figure 5** Example of a female without detectable mutation as an infant (A) and in early adolescence (B).

been reported with the typical clinical syndrome, with and without HSCR, where no abnormality involving *ZFHX1B* can be shown.<sup>6-8</sup>

*ZFHX1B*, located on chromosome 2q22, spans approximately 70 kb of DNA, consists of 10 exons and 9 introns, and encodes a protein product, Smad interacting protein 1 (SIP1), consisting of 1214 amino acids. SIP1 is a member of the  $\delta$ EF1/Zfh-1 family of two handed zinc finger/homeodomain transcription factors involved in the TGF- $\beta$ /BMP/Smad mediated signalling cascade.<sup>24</sup> SIP1 shows 97% homology to the mouse form (Sip1) at the amino acid level, with exactly the same functional domains.<sup>3</sup> SIP1 contains a Smad binding domain (SBD), a homeobox-like domain (HD), interspersed with a zinc finger cluster, and two other separated zinc finger clusters (ZF) at the amino and carboxy terminals.<sup>25</sup> *ZFHX1B* mRNA is detected in nearly all human tissues (heart, brain, placenta, lung, liver, skeletal muscle) as well as mouse heart and brain.<sup>3</sup> SIP1 expression is also detected in fetal human tissues including brain, kidney, liver, and spleen. Mouse Sip1 is expressed in many brain regions (hypothalamus, cerebellum, cortex, rhombencephale, hippocampus, mid brain, and spinal cord). As a transcription modulator, SIP1 is likely to have a crucial role in embryonic development.<sup>26-28</sup> XSIP1, the *Xenopus* homologue of SIP1, has been shown to be active in early embryogenesis. It is strongly expressed early in prospective neuroectoderm, then in the neural plate, and later in the neural tube and neural crest.<sup>3, 30-31</sup> SIP1 interacts with other Smad

proteins 2, 3, and 5.<sup>30</sup> Activated Smad proteins form hetero-oligomeric complexes that translocate to the nucleus to control the expression of target genes in a cell specific manner. SIP1 appears to be a promoter of invasion in malignant epithelial tumours. It acts by downregulating E-cadherin transcription via binding to both conserved E2 boxes of the minimal E-cadherin promoter.<sup>32</sup> The mechanism underlying the phenotypic effects of *SIP1* mutation has not yet been determined. Understanding this process may provide insights into the development of the enteric nervous system and the cause of intellectual disability. Interestingly Espinosa-Parrilla *et al*<sup>33</sup> recently showed the lack of SMADIP1 expression in the developing human heart even though many patients have congenital heart defects.

### GENOTYPE-PHENOTYPE CORRELATIONS

MWS has been associated with heterozygous deletions, translocations, and intragenic mutations of *ZFHX1B* (table 3). All but one of the intragenic mutations are nonsense or frameshift mutations, expected to produce a truncated or absent protein, suggesting that haploinsufficiency leads to an altered gene dosage effect at critical stages of early development (fig 4). One patient has a splice site mutation (splice site G to A +1 exon 2) which causes complete loss of normal splicing. This causes a total absence of splicing, producing a protein which has retained the intron (exon 2-intron 2-exon 3). This changes the reading frame leading to a stop at the next nonsense codon, resulting in a truncated protein. The mutations are located throughout the coding region of the gene; although 58% of mutations are in exon 8, this comprises around 60% of the coding sequence.

All seven patients (three males and four females), with deletion of the entire *ZFHX1B* gene have HSCR,<sup>1, 5, 6, 9</sup> as does the patient with a translocation disrupting the gene in intron 2. Only one of the five patients with R695X (the only recurrent mutations so far reported) has HSCR. Of the 32 other intragenic mutations, 16 are in patients with HSCR, but there is no clear genotype-phenotype correlation in respect to location of the mutation and penetrance of the HSCR phenotype. Zweier *et al*<sup>8</sup> showed persistence of truncated SIP1 mRNA in a patient with a (nt553-554 ins TG) in exon 5, indicating that mRNA decay and complete haploinsufficiency of SIP1 may not be present in all cases. No other studies of this nature have been reported. There are no patients with missense mutations to help determine the effects of disruption of specific domains within SIP1. There are no data available to suggest that some of the deleted patients have a similar sized deletion. The presence of genomic repeats flanking the *ZFHX1B* gene to account for the deleted patients has not been determined. It is not known whether the parental origin of the deleted or mutated *ZFHX1B* gene has an effect on phenotype as these data have not been provided.

### MWS without *ZFHX1B* mutation

Several series have now reported typical patients (diagnosed by clinicians familiar with the phenotype), who do not have demonstrable mutations in *ZFHX1B*. These include one patient of Yamada *et al*<sup>6</sup>, three patients of Amiel *et al*,<sup>5</sup> and two further patients from our cohort (fig 5).<sup>5, 6, 8, 15</sup> These patients may have undetected abnormalities involving *ZFHX1B*, but genetic heterogeneity for this syndrome cannot be completely excluded, in particular mutations affecting alternative genes acting on the same developmental pathways.

### GENETIC COUNSELLING

All cases of MWS have been sporadic, caused by de novo deletions or new dominant mutations in *ZFHX1B*. Where the diagnosis is certain, in a sporadic patient, families can be counselled that the recurrence risk is low, although the possibility of germline mosaicism cannot be excluded.

.....  
**Authors' affiliations**

**D Mowat**, Department of Medical Genetics, The Sydney Children's Hospital, University of New South Wales, Sydney, NSW 2031, Australia  
**M J Wilson**, Department of Clinical Genetics, Western Sydney Genetics Program, The Children's Hospital at Westmead, Hawkesbury Road, Westmead, Sydney, NSW 2145, Australia  
**M Goossens**, INSERM U468 et Service de Biochimie et Genetique, AP-HP, Hopital Henri Mondor, 51 Avenue du Marechal de Lattre de Tassigny, 94010 Creteil, France

**REFERENCES**

- Mowat DR**, Croaker GDH, Cass DT, Kerr BA, Chaitow J, Adès LC, Chia NL, Wilson MJ. Hirschsprung disease, microcephaly, mental retardation, and characteristic facial features: delineation of a new syndrome and identification of a locus at chromosome 2q22-q23. *J Med Genet* 1998;**35**:617-23.
- Wakamatsu N**, Yamada Y, Ono T, Nomura N, Taniguchi H, Kitoh H, Mutoh N, Yamanaka T, Mushiaki K, Kato K, Sonta S, Nagaya M. Mutations in *SIP1*, encoding Smad interacting protein-1, cause a form of Hirschsprung disease. *Nat Genet* 2001;**27**:369-70.
- Cacheux V**, Dastot-Le Moal F, Kääriäinen H, Bondurand N, Rintala R, Boissier B, Wilson M, Mowat D, Goossens M. Loss-of-function mutations in *SIP1* Smad interacting protein 1 results in a syndromic Hirschsprung disease. *Hum Mol Genet* 2001;**10**:1503-10.
- Zweier C**, Albrecht B, Mitulla B, Behrens R, Beese M, Gillissen-Kaesbach G, Rott H, Rauch A. "Mowat-Wilson" syndrome with and without Hirschsprung disease is a distinct, recognizable multiple congenital anomalies-mental retardation syndrome caused by mutations in the zinc finger homeo box 1B gene. *Am J Med Genet* 2002;**108**:177-81.
- Amiel J**, Espinosa-Parrilla Y, Steffann J, Pelet A, Gosset P, Choiset A, Tanaka H, Prieur M, Vekemans M, Munnich A, Lyonnet S. Large scale deletions and *SMAD1P1* truncating mutations in syndromic Hirschsprung disease with midline structure involvement. *Am J Hum Genet* 2002;**69**:1370-7.
- Yamada K**, Yamada Y, Nomura N, Miura K, Wakako R, Hayakawa C, Matsumoto A, Kumagai T, Yoshimura I, Miyazaki S, Kato K, Sonta S, Ono H, Yamanaka T, Nagaya M, Wakamatsu N. Nonsense and frameshift mutations in *ZFH11N*, encoding Smad-interacting protein 1, cause a complex developmental disorder with a great variety of clinical features. *Am J Hum Genet* 2002;**69**:1179-85.
- Garavelli I**, Onadio A, Zanacca C, Della Giustina E, Bertani G, Albertini G, Zollino M, Rauch A, Banchini G, Neri G. Hirschsprung disease, mental retardation, characteristic facial features and mutation in the gene *ZFH11B* (*SIP1*): confirmation of the Mowat-Wilson syndrome. *Am J Med Genet* (in press).
- Wilson M**, Mowat D, Kääriäinen H, Dastot-Le Moal F, Cacheux V, Curry C, Townsend S, Braddock S, Aftimos S, Gattas M, Barray C, Clayton-Smith J, Donnai D, Zehnirwirth H, Kerr B, Cass DT, Goossens M. Mutations in the *SIP1* gene cause a distinctive dysmorphic syndrome with or without HSCR. *Am J Med Genet* (submitted).
- Lurie IW**, Supovitz KR, Rosenblum-Vos LS, Wulfsberg EA. Phenotypic variability of del(2)(q22-q23): report of a case and review of the literature. *Genet Couns* 1994;**5**:11-14.
- Ryan A**, Burn J, Court S, Jackson T, Clayton-Smith J, Barwick B. Two brothers with varying combinations of severe developmental delay, epilepsy, microcephaly, tetralogy of Fallot and hydronephrosis. *Clin Dysmorphol* 1999;**8**:15-18.
- Hurst JA**, Markiewicz M, Kumar D, Brett EM. Unknown syndrome. Hirschsprung's disease, microcephaly, and iris coloboma: a new syndrome of defective neuronal migration. *J Med Genet* 1988;**25**:494-500.
- Ohnuma K**, Imaizumi K, Masuno M, Nakamura M, Kuroki Y. Magnetic resonance imaging abnormalities of the brain in Goldberg-Shprintzen syndrome (Hirschsprung disease, microcephaly, iris coloboma). *Am J Med Genet* 1997;**73**:230-2.
- Amiel J**, Lyonnet S. Hirschsprung disease, associated syndromes, and genetics: a review. *J Med Genet* 2001;**38**:729-39.
- Fryer A**. Goldberg-Shprintzen syndrome: report of a new family and review of the literature. *Clin Dysmorphol* 1998;**7**:97-101.
- Kääriäinen H**, Wallgren-Pettersson C, Clarke A, Pihko H, Taskinen H, Rintala R. Hirschsprung disease, mental retardation and dysmorphic facial features in five unrelated children. *Clin Dysmorphol* 2001;**10**:157-63.
- Goldberg RB**, Shprintzen RJ. Hirschsprung megacolon and cleft palate in two sibs. *J Craniofac Genet Dev Biol* 1981;**1**:185-9.
- Brunoni D**, Joffe R, Farah LMS, Cunha AJ. Hirschsprung megacolon, cleft lip and palate, mental retardation and minor malformations. *J Clin Dysmorphol* 1983;**1**:20-2.
- Kumasaka K**, Clarren SK. Familial patterns of central nervous system dysfunction, growth deficiency, facial clefts and congenital megacolon: a specific disorder? *Am J Med Genet* 1988;**31**:465-6.
- Tanaka H**, Ito J, Cho K, Mikawa M. Hirschsprung disease, unusual face, mental retardation, epilepsy, and congenital heart disease: Goldberg-Shprintzen syndrome. *Pediatr Neural* 1993;**9**:233-8.
- Halal F**, Morel J. The syndrome of Hirschsprung disease, microcephaly, unusual face, and mental retardation. *Am J Med Genet* 1990;**37**:106-8.
- Yomo A**, Taira T, Kondo I. Goldberg Shprintzen syndrome: Hirschsprung disease, hypotonia, and ptosis in siblings. *Am J Med Genet* 1991;**41**:188-91.
- Brooks A**, Breuning M, Osinga J, vd Smagt J, Catsman C, Buys C, Meijers C, Hofstra M. A consanguineous family with Hirschsprung disease, microcephaly, and mental retardation (Goldberg-Shprintzen syndrome). *J Med Genet* 1999;**36**:485-9.
- Williams C**, Lossie A, Driscoll D, and the RC Phillips Unit. Angelman syndrome: mimicking conditions and phenotypes. *Am J Med Genetics* 2001;**101**:59-64.
- Remacle JE**, Kraft H, Lerchner W, Wuytens G, Collart C, Verschuereen K, Smith JC, Huylebroeck D. New mode of DNA binding of multi-zinc finger transcription factors:  $\delta$ EF1 family members bind with two hands to two target sites. *EMBO J* 1999;**18**:5073-84.
- Verschuereen K**, Remacle JE, Collart C, Kraft H, Baker BS, Tylzanowski P, Nelles L, Wuytens G, Su M-T, Bodmer R, Smith JC, Huylebroeck D. *SIP1*, a novel zinc finger/homeodomain repressor, interacts with smad proteins and binds to 5CACCT sequences in candidate target genes. *J Biol Chem* 1999;**274**:20489-98.
- Ten Dijke P**, Miyazono K, Heldin C. Signalling inputs converge on nuclear effectors in TGF-beta signaling. *Trends Biochem Sci* 2000;**25**:64-70.
- Watanabe M**, Whitman M. the role of transcription factors involved in TGFbeta superfamily signaling during development. *Cell Mol Biol* 1999;**45**:537-43.
- Heldin C**, Miyazono K, ten Dijke P. TGF-beta signaling from cell membrane to nucleus through SMAD proteins. *Nature* 1997;**390**:465-71.
- Atisano I**, Wrana J. Smads as transcriptional co-modulators. *Curr Opin Cell Biol* 2000;**12**:235-43.
- van Grunsven L**, Papin C, Avalosse B, Opdecamp K, Huylebroeck D, Smith J, Bellefroid E. *XSIPI1*, a Xenopus zinc finger/homeodomain encoding gene highly expressed during early neural development. *Mech Dev* 2000;**94**:189-93.
- Eisaki A**, Kuroda H, Fukui A, Asashima M. *XSIPI1*, a member of two-handed zinc finger proteins, induced anterior neural markers in *Xenopus laevis* animal cap. *Biochem Biophys Res Commun* 2000;**271**:151-7.
- Comijn J**, Bex G, Vermassen P, Verschuereen K, van Grunsven L, Bruyneel E, Mareel M, Huylebroeck D, van Roy F. The two-handed E box zinc finger protein *SIP1* downregulates E-cadherin and induces invasion. *Mol Cell* 2001;**7**:1503-10.
- Espinosa-Parilla Y**, Amiel J, Auge J, Encha-Razavi F, Lyonnet S, Vekemans M, Attie-Bitach T. Expression of the *SMAD1P1* gene during early human development. *Mech Dev* 2002;**114**:187.



## Mowat-Wilson syndrome

D R Mowat, M J Wilson and M Goossens

*J Med Genet* 2003 40: 305-310  
doi: 10.1136/jmg.40.5.305

---

Updated information and services can be found at:  
<http://jmg.bmj.com/content/40/5/305>

---

	<i>These include:</i>
<b>References</b>	This article cites 28 articles, 6 of which you can access for free at: <a href="http://jmg.bmj.com/content/40/5/305#ref-list-1">http://jmg.bmj.com/content/40/5/305#ref-list-1</a>
<b>Email alerting service</b>	Receive free email alerts when new articles cite this article. Sign up in the box at the top right corner of the online article.

---

### Topic Collections

Articles on similar topics can be found in the following collections

[Congenital heart disease](#) (82)  
[Epilepsy and seizures](#) (197)  
[Genetic screening / counselling](#) (888)

---

### Notes

---

To request permissions go to:  
<http://group.bmj.com/group/rights-licensing/permissions>

To order reprints go to:  
<http://journals.bmj.com/cgi/reprintform>

To subscribe to BMJ go to:  
<http://group.bmj.com/subscribe/>