

Reciprocal translocation 14q;21q in a patient with the Brachmann-de Lange syndrome

WILLIAM G WILSON, JAN M KENNAUGH, JANE P KUGLER, AND HERMAN E WYANDT

Department of Pediatrics, University of Virginia Medical Center, Charlottesville, Virginia 22908, USA.

SUMMARY A patient with the Brachmann-de Lange syndrome was found to have an apparently balanced de novo translocation 14q;21q. The relationship between this uncommon translocation and the patient's phenotype is unclear. Although most patients with the Brachmann-de Lange syndrome have normal chromosomes, the possibility of aetiological heterogeneity, including some rare chromosomal abnormalities, cannot be dismissed.

Although the Brachmann-de Lange syndrome (BDLS) is a well recognised malformation syndrome, its aetiology remains obscure.¹ Most cases are sporadic and discordant sets of identical twins have been described.² Cytogenetic studies have usually been normal,^{3,4} with the exception of the 3q duplication syndrome which has some similarity to the BDLS.⁵

We report a child with the BDLS who has an uncommon, apparently balanced, de novo reciprocal translocation involving 14q and 21q.

Case report

The patient was born at term following a pregnancy

Received for publication 18 March 1983.

Accepted for publication 25 April 1983.

complicated by poor uterine growth, oligo-hydramnios, and breech presentation. Her birth weight (1971 g), length (45 cm), and head circumference (29 cm) were below the 5th centile for gestational age. She suffered respiratory difficulties in the neonatal period and was briefly intubated for mechanical ventilation. Her physical examination revealed a small female infant with cutis marmorata, synophrys, long eyelashes, a small upturned nose, a long philtrum with thin upper lip, a complete cleft of the secondary palate, and micrognathia (fig 1). There was limitation of extension at the elbows. The hands were small and the thumbs appeared to be proximally placed. Single transverse palmar creases were present and the distal phalanges of the second and fifth fingers were shortened. The toenails were hypoplastic and there was partial syndactyly of the second and third toes. A clinical diagnosis of the BDLS was made and a peripheral blood sample was obtained for chromosome analysis, the results of which are described below. Evaluation of persistent regurgitation revealed pyloric stenosis, duodenal bands, and malrotation of the small intestine, all of which were surgically corrected. The child has grown slowly during the first year of life and is delayed in all areas of development.

The family history is unremarkable for other members with mental retardation or dysmorphic features similar to those of the patient. The mother is

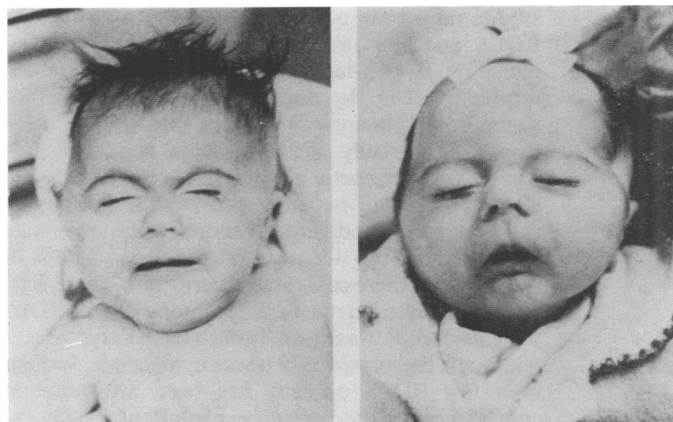

FIG 1 Patient in the newborn period (left) and at 3 months of age (right).

aged 29 years and the father aged 36 years; this was the first pregnancy for both.

CYTOGENETIC STUDIES

Blood was obtained in the newborn period and at the age of 3 months for cytogenetic analysis of lymphocytes. Some cultures were treated with methotrexate to obtain cells in prometaphase.⁶ Quinacrine banding and trypsin-Giemsa banding were done and revealed an apparently balanced translocation between the long arms of chromosomes 14 and 21, or 46,XX,t(14pter→14q32::21q11→21qter;21pter→21q11::14q32→14qter) in all cells examined (figs 2 and 3). Lymphocyte karyotypes of both parents were normal.

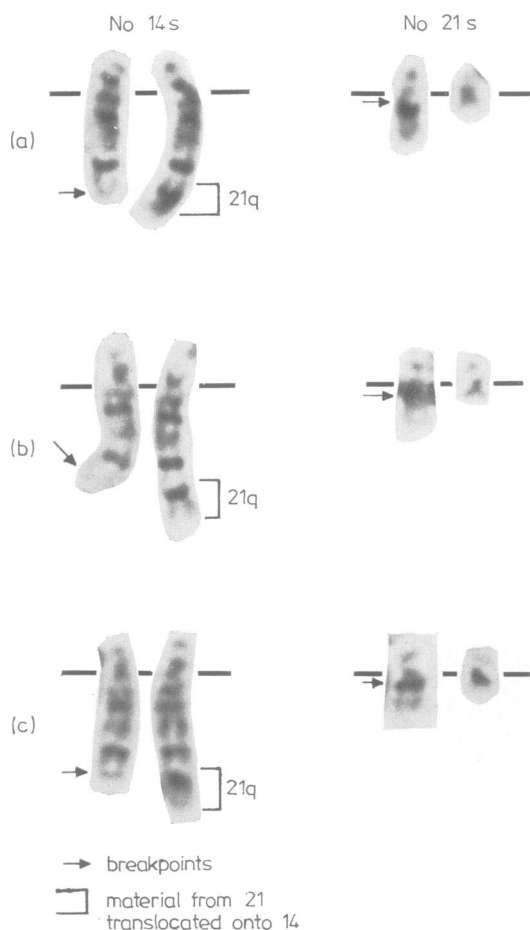


FIG 2 Representative examples of chromosomes 14 and 21 from the patient. The area involved in the translocation and the location of the breakpoints are shown.

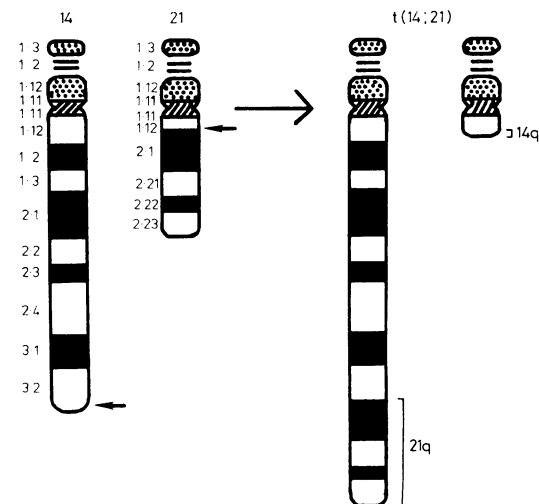


FIG 3 Schematic illustration of reciprocal translocation in patient.

Discussion

The patient has the phenotype of BDLs, including gastrointestinal malformations which have been described in this syndrome.⁷ The clinical diagnosis of BDLs was made before the internal malformations were recognised or the results of the karyotyping were known.

The translocation between 14q and 21q in our patient appears to be balanced, with no detectable extra or deleted material. Neither parent carries the translocation in peripheral blood lymphocytes. Therefore, the translocation could have arisen de novo or could be present in a parent as an undetected cell line.

The relationship between the translocation in our patient and the BDLs is not clear. Chromosome studies have been performed on many patients with BDLs and the results of most of these studies, including high resolution banding, have been normal.^{3,4} The 3q duplication syndrome, which shares some phenotypic features with BDLs, is felt to be a clinically distinguishable syndrome.⁵ A variety of cytogenetic abnormalities have occasionally been seen in patients with BDLs.^{1,3} Many of these were reported before banding techniques were available, so the identity of the breakpoints or fragments in these cases is undetermined. There is no consistent cytogenetic finding among those BDLs patients who have an abnormal karyotype.^{1,3} Although the presence of these cytogenetic findings in a few BDLs patients has been attributed to coincidence,³ alternative explanations such as

genocopies of the BDLS phenotype should also be considered. It is still conceivable that BDLS is related to a minor chromosome deletion or duplication so subtle that it has not been detected by current techniques. As the technology improves, additional studies of the BDLS will be helpful, perhaps with emphasis placed on those chromosomes which have been involved in cytogenetic abnormalities in BDLS patients.

References

- ¹ Berg JM, McCreary BD, Ridler MAC, Smith GF. *The de Lange syndrome*. Oxford: Pergamon Press, 1970.
- ² Stevenson RE, Scott CI. Discordance for Cornelia de Lange syndrome in twins. *J Med Genet* 1976;**13**:402-4.
- ³ Beck B, Mikkelsen M. Chromosomes in the Cornelia de Lange syndrome. *Hum Genet* 1981;**59**:271-6.

- ⁴ Breslau EJ, Distèche C, Hall JG, Thuline H, Cooper P. Prometaphase chromosomes in five patients with the Brachmann-de Lange syndrome. *Am J Med Genet* 1981;**10**:179-86.
- ⁵ Steinbach P, Adkins WN, Caspar H, *et al*. The dup(3q) syndrome: report of eight cases and review of the literature. *Am J Med Genet* 1981;**10**:159-77.
- ⁶ Yunis JJ. High resolution of human chromosomes. *Science* 1976;**191**:1268-70.
- ⁷ France NE, Crome L, Abraham JM. Pathological features in the de Lange syndrome. *Acta Paediatr Scand* 1969;**58**:470-80.

Correspondence and requests for reprints to Dr William G Wilson, Department of Pediatrics, Box 386, University of Virginia Medical Center, Charlottesville, Virginia 22908, USA.

De novo duplication of the 7q11→q22 region

NATALINE B KARDON, LYNDA POLLACK, JESSICA DAVIS, AFINA BROEKMAN, AND MARION KRAUSS

Department of Pediatrics, North Shore University Hospital, and Department of Pediatrics, Cornell University Medical College, New York, USA.

SUMMARY A patient with de novo partial trisomy for the 7q11→7q22 region as defined by methotrexate high resolution banding is described. He presented with delayed growth and development and characteristic physical features. These consisted of frontal bossing, prominent metopic suture, almond shaped eyes, enophthalmos, large, low set, posteriorly rotated ears, long philtrum, narrow upper lip, high arched palate, and a short neck. Specific genitourinary anomalies were noted.

Partial duplication of chromosome 7q was first described by Carpentier *et al*.¹ Banding techniques provided further phenotypic delineation, and in 1976 Turleau *et al*² proposed two distinct syndromes based on different breakpoints. To date approximately 20 cases have been reported and most have resulted from a familial balanced translocation.³

Wahrman *et al*⁴ described a patient with possible duplication of 7q11→7qter. We wish to describe a phenotypically similar patient with de novo partial duplication of 7q.

Case report

The proband, a white male, was born on 13.2.78 to unrelated 29-year-old Italian-Irish parents following a term pregnancy complicated by first trimester bleeding. Birth weight was 2500 g. The delivery and neonatal course were unremarkable. There is a single sib, a 5-year-old sister, who was the only survivor of a premature triplet delivery.

The patient was initially evaluated at 10 months of age because of delayed growth and development. Physical examination (fig 1) revealed a small alert male infant whose height and weight were below the 3rd centile. Pertinent findings included frontal bossing, prominent metopic suture, almond shaped eyes, enophthalmos, large, low set, posteriorly rotated ears, long philtrum, narrow upper lip, high arched palate, and a short neck. An accessory nipple was present on his right lower lateral chest. He had a small penis and bilateral cryptorchidism. On neurological examination he had normal muscle tone and normal reflexes. He sat without support, but he did not support his weight or attempt to stand. Dermatoglyphs were unremarkable.

At 15 months of age he was admitted to hospital because of failure to thrive. Proximal renal tubular acidosis was diagnosed, but the patient did not gain



Reciprocal translocation 14q;21q in a patient with the Brachmann-de Lange syndrome.

W G Wilson, J M Kennaugh, J P Kugler and H E
Wyandt

J Med Genet 1983 20: 469-471
doi: 10.1136/jmg.20.6.469

Updated information and services can be found at:
<http://jmg.bmj.com/content/20/6/469>

Email alerting service

These include:

Receive free email alerts when new articles cite this article. Sign up in the box at the top right corner of the online article.

Notes

To request permissions go to:
<http://group.bmj.com/group/rights-licensing/permissions>

To order reprints go to:
<http://journals.bmj.com/cgi/reprintform>

To subscribe to BMJ go to:
<http://group.bmj.com/subscribe/>