

REVIEW

Mulibrey nanism: clinical features and diagnostic criteria

N Karlberg, H Jalanko, J Perheentupa, M Lipsanen-Nyman

J Med Genet 2004;41:92–98. doi: 10.1136/jmg.2003.014118

Mulibrey nanism (MUL) is an autosomal recessive disease caused by mutations in the *TRIM37* gene encoding the peroxisomal TRIM37 protein of unknown function. In this work, we analysed the clinical characteristics of 85 Finnish patients with MUL, most of whom were homozygous for the Finn major mutation of *TRIM37*. The patients' hospital records from birth to the time of the diagnosis at age 0.02–52 years (median 2.1 years) were retrospectively analysed. All except four of the patients (95%) had a prenatal onset growth failure without postnatal catch up growth. The mean length standard deviation score (SDS) was –3.1 and –4.0 at birth and at diagnosis, respectively. In infancy, feeding difficulties, and respiratory tract infections were the most common problems. Congestive heart failure and pericardial constriction were diagnosed during infancy in 12% and 6% of the patients, respectively. At the time of the diagnosis, characteristic craniofacial features of scaphocephaly, facial triangularity, high and broad forehead, and low nasal bridge were evident in over 90% of the patients. In addition, practically all patients were gracile and had thin extremities. Other findings included a peculiar high-pitched voice (96%), yellowish dots in ocular fundi (79%), cutaneous naevi flammei (65%), hepatomegaly (45%), and fibrous dysplasia of long bones (25%). Mild muscular hypotonicity (68%) was the only neurological abnormality. The clinical features of the Finnish patients with MUL formed a distinct entity. The most consistent findings were growth failure and characteristic craniofacial features. However, organ manifestations varied considerably in early childhood. Based on these findings, we propose new diagnostic criteria for MUL.

and Turkish (c.855_862delTGAATTAG).¹² All five mutations result in a shift of the reading frame, resulting in a truncated TRIM37 protein.¹³ TRIM37 is a 130 kDa protein expressed in many tissues¹⁴ and located in the peroxisomes, suggesting that MUL is a peroxisomal disease.¹⁵ TRIM37 belongs to a new subfamily of zinc finger proteins (previously designated RBCC for ring-B box-coiled coil). The function of the TRIM37 protein and the pathogenetic mechanisms underlying MUL are unknown.

Diagnostic evaluation and clinical care of the patients with MUL in Finland has been centred in our institution. Here we report the clinical findings from birth to the time of the diagnosis in all known Finnish patients, and present revised diagnostic criteria.

PATIENTS AND METHODS

Patients

The series included all the known 85 Finnish patients with MUL diagnosed by the original criteria.² DNA was available from 80 patients; 78 of them homozygous for the Finn major mutation, and two compound heterozygotes for the two Finnish mutations. The other five patients had died before mutation analysis became available. In four of those five cases, DNA was obtained from family member(s); one parent couple, two single parents, and one sibling, all carriers of the Finn major mutation. The phenotype of the remaining patient left no doubt about the diagnosis.

Collection of data

The hospital ethics committee approved the study. We retrospectively analysed the patients' hospital records from birth to the time of diagnosis. We recorded data on their clinical events and on their appearance and dysmorphic features. The patients were photographed, and x rays of the skull, thorax, and long bones as well as appropriate laboratory assays were obtained on the first visits. The obstetric and growth histories were collected from hospitals and child welfare centres. The patients' parents, relatives, and physicians were interviewed for missing details. Birth size and subsequent lengths/heights were expressed as standard deviation scores (SDS) according to the Finnish standards, and postnatal weights as percentage deviations from the mean weight for height and sex.

Mulibrey nanism (*muscle-liver-brain-eye* nanism, MUL; OMIM #253250) is an autosomal recessive disorder with severe growth failure and multiple organ manifestations first described in the early 1970s.^{1,2} Today we know of some 110 patients, 85 of them from Finland. Sporadic cases have been reported from various ethnic groups all over the world.^{3–12}

MUL is caused by mutations in the *TRIM37* gene on chromosome 17q22–q23.¹³ Five different mutations have been reported in patients with MUL. Two of them are Finnish, the Finn major (c.493–2A→G) and the Finn minor mutation (c.2212delG). The others are Czech (c.838–842delACTTT), American (c.1346–1347insA)¹³

See end of article for authors' affiliations

Correspondence to:
Dr M Lipsanen-Nyman,
The Hospital for Children
and Adolescents,
University of Helsinki,
00029 HYKS, Finland;
marita.lipsanen@hus.fi

Abbreviations: SDS, standard deviation score; SGA, small for gestational age; SRS, Silver-Russell syndrome

RESULTS

The clinical data on the 85 Finnish patients with MUL were systematically analysed from birth to time of the diagnosis. The age at the diagnosis varied from 0.02 to 52 years (median 2.1 years). A third of them were younger than 1 year and two thirds were younger than 5 years.

Pregnancy and delivery

Most of the pregnancies were uneventful. Complications included pre-eclampsia (three cases), anti-Rhesus immunisation (a pair of siblings), gestational diabetes (one), and varicella zoster infection (one). Nineteen of the pregnancies (23%) had been monitored because of poor fetal growth. Fifteen mothers (18%) had had miscarriages in previous pregnancies. Length of gestation varied from 32 to 42 weeks (median 39 weeks); 90% of the children were born at full term. Labour was uncomplicated in all but three cases, in which an urgent caesarean section was performed because of threatened asphyxia. Apgar score at 5 minutes was on average 8 (range 2–10).

Newborn period

Of the newborns, 81 (95%) were small for gestational age (SGA), with birth length SDS below -2.0 for gestational age (fig 1). Birth length SDS was on average -3.1 (range -6.4 to 0.7), and mean birth weight SDS was -2.8 (range -4.0 to 0.5). Occipitofrontal head circumference SDS ranged from -0.9 to 0.8 (mean -0.5) indicating macrocephaly relative to length in the majority of children.

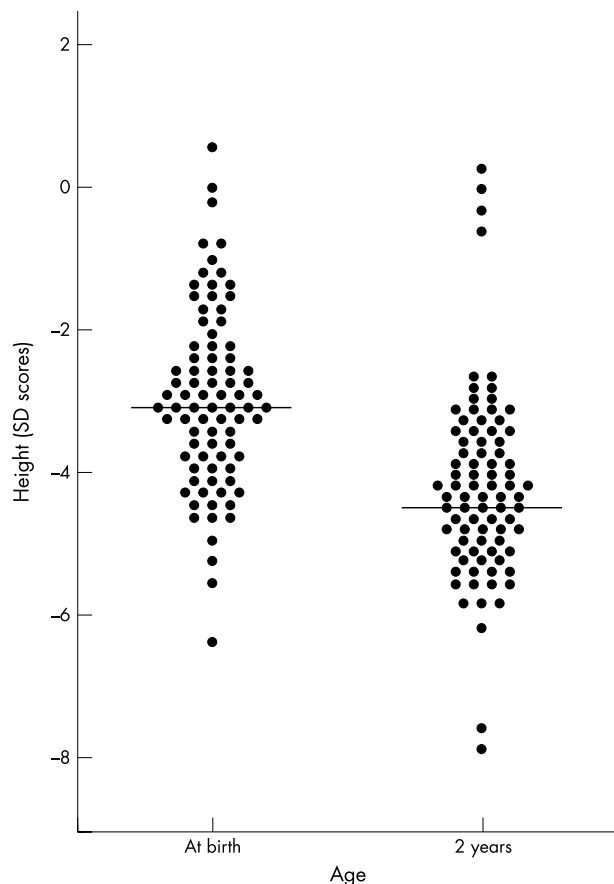


Figure 1 Length SDS at birth and at the age of 2.0 years in 85 infants with MUL, 39 boys and 46 girls. The growth failure progressed postnatally in 74% of the patients.

Table 1 Problems in infancy in 85 patients with Mulibrey nanism

Feature	Frequency (%)
Neonatal problems	
Respiratory problems	31
Ventilatory assistance needed	20
Cyanosis while crying	15
Feeding difficulties	30
Nasogastric feeding tube needed	17
Suspicion of hydrocephalus	6
Suspicion of sepsis	6
Cardiac arrhythmia	1
Growth failure	96
Infections	
Upper respiratory infections >4/year	51
Pneumonia	47
Necessitating hospital care	30
Three or more pneumonias	27
Ventilatory assistance needed	25
Intubation needed	14
Middle ear infections >4/year	38
Feeding difficulties	50
Vomiting	39
Difficulties in sucking	31
Nasogastric feeding tube needed	31
Delay in switching to solid foods	24
Fatigue during eating	21
Percutaneous gastrostomy needed	6
Muscular hypotonicity	46
Suspicion of hydrocephalus	16
Hypoglycaemia	15
Congestive heart failure	11
Resuscitation during first year of life	11
Due to infection	9
Due to aspiration	1
Due to arrhythmia	1
Death during infancy	5
Due to infection	2.5
Due to congestive heart failure	2.5

The newborn period was relatively normal in most cases. MUL was diagnosed in only one of the patients who had no affected siblings (table 1). Fourteen babies needed supplementary oxygen. Respiratory distress syndrome was diagnosed in three; two of them were born prematurely. Cardiac involvement was evident in only one baby with Wolff-Parkinson-White syndrome causing paroxysmal supraventricular tachycardial attacks. One third of the newborns had serious feeding difficulties; 14 of them needed a nasogastric tube. Twelve babies were hospitalised from 14 to 55 days because of feeding difficulties or pulmonary problems.

Later infancy

The growth failure progressed over the first 2 years of life in 63 patients (74%) with an SDS decrease of more than 1.0 (range -1.0 to -3.5). Catch up growth with a gain in length SDS of more than 1.0 (range 1.1 to 2.9) occurred in five (6%) of the infants. One boy and two girls reached a length SDS above -2.0 at the age of 2.0 years; one girl grew steadily from birth staying at an SDS of -1.4 . At the age of 2.0 years, length SDS was on average -4.4 (range 0.1 to -7.8) (fig 1). Weight gain was also poor. Mean relative weight for height at the age of 2.0 years was $-21%$ (range -35 to $3%$).

Half of the patients failed to thrive. Feeding difficulties were the most common clinical problem such that one third needed nasogastric feeding and five children needed a percutaneous gastrostomy (table 1). A high frequency of upper respiratory infections and middle ear infections was evident; pneumonias were diagnosed in nearly half of the infants by the age of 2.0 years (table 1). Episodes of respiratory failure induced by an infection occurred in 25% of the infants. Nine infants had to be resuscitated (table 1).

Four and nine patients had congestive heart failure by the age of 1.0 and 2.0 years, respectively; four of them died.

Psychomotor development was normal or slightly delayed in a great majority of the infants. Mild hypotonicity was evident in nearly half of the infants, and a delay in both motor development and speech was noted in nearly one third. Age at the first steps and the first words ranged from 0.8 to 2.6 years (mean 1.2 years) and 0.9 to 3.1 years (mean 1.3 years), respectively. A mildly hydrocephalic skull with frontal bossing and abnormally wide fontanelles evoked suspicion of hydrocephalus in 15% of the infants (table 1).

Findings at the time of diagnosis

Clinical findings

At the time of the diagnosis all but four (96%) of the patients were below length SDS of -2.5 . Nearly all the patients were gracile with relative macrocephaly, and thin extremities with proximal relative shortness and narrow shoulder (fig 2). The characteristic triangular face with high, broad forehead and low nasal bridge was present in over 90%, and scaphocephaly with occipitofrontal bossing was seen in over 80% of the patients (table 2, fig 3)

Fifteen patients (18%) had signs of heart disease (table 3). Ten of them met the criteria of congestive heart failure, and four had pericardial constriction necessitating pericardiectomy. One woman had been pericardiectomised at the age of 32 years (12 years before the diagnosis) due to constrictive pericarditis. Eighteen patients (15%) had structural heart anomalies (table 3).

Thirty eight patients (45%) had hepatomegaly and six of them had liver tumours. Wilms' tumour was detected in two patients before MUL was diagnosed. Both patients had non-symptomatic haematuria with a palpable abdominal mass as the only signs. Renal and genital anomalies were observed in 18% and 9% of the patients, respectively (table 3).

A peculiar voice characterised by high pitch and slight coarseness was noted in nearly all of the prepubertal patients. Characteristic ocular findings¹⁶ were yellow dots in the midperiphery of ocular fundi, seen in 80% of the patients. Additional ocular findings were retinal hypopigmentation and pigment dispersion with clusters of pigment in the

Table 2 Dysmorphic features of appearance at the time of diagnosis in 85 patients with Mulibrey nanism

Feature	Frequency(%)
Head	
Characteristic face: triangular face, high and broad forehead; low nasal bridge and telecanthus	90
Scaphocephaly	81
Hypoplastic tongue	80
Low set located posteriorly rotated ears	54
Dental crowding	50
High hairline	45
Wide fontanelles and sutures in infancy	37
Abnormally wide metopic suture	31
Cleft palate	2
Body	
Thin extremities	99
Accentuated lumbar lordosis	96
General gracility	95
Narrow shoulders	94
Small bell shaped thoracic cage	94
Barrell-like trunk	92
Cutaneous naevi flammei	65
Hypoplastic buttocks	52
Constitution	
Relative proximal shortness of limbs	90
Large head relative to stature	81
Large hands and feet relative to stature	67
Skeletal asymmetry	15

retina. Two thirds of the patients had cutaneous naevi flammei, most commonly in the lower limbs (80%).

Radiological findings

Slender long bones with thick cortex and narrow medullary channel (fig 4) and a low, shallow (J shaped) sella turcica (fig 5) were the characteristic radiological findings present in nearly all patients (table 4). More than half of the patients had true orbital hypertelorism. The orbital fossae were slightly upward slanting with laterally rotated axis (fig 5). Fibrous dysplasia was present in 15% of the patients, mostly in the lower limbs (fig 4). Six patients had fibrous dysplasia in more than two locations (range 2 to 4). A slight asymmetry

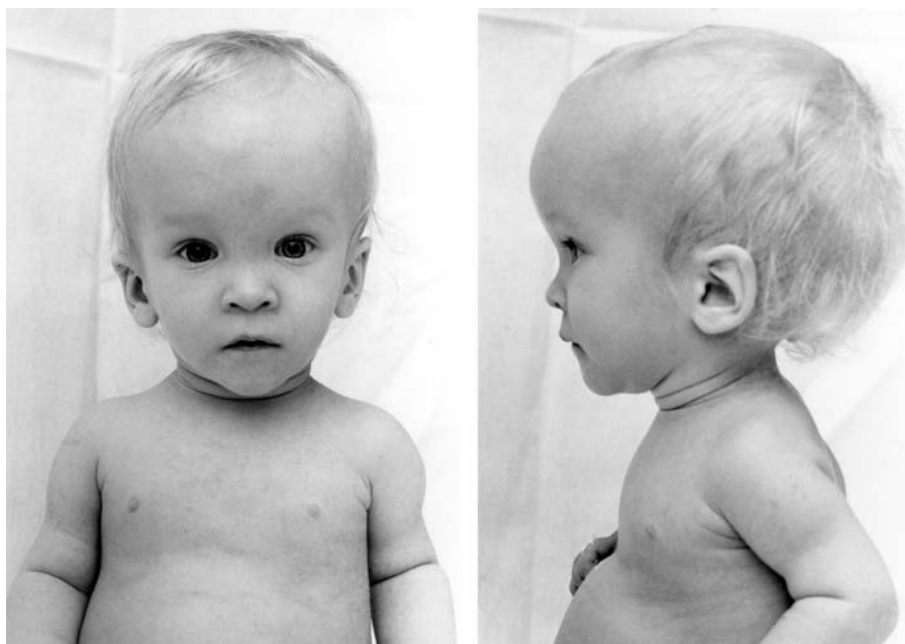


Figure 2 The characteristic craniofacial features; triangular face, low nasal bridge, high and broad forehead, and scaphocephaly with occipitofrontal bossing.

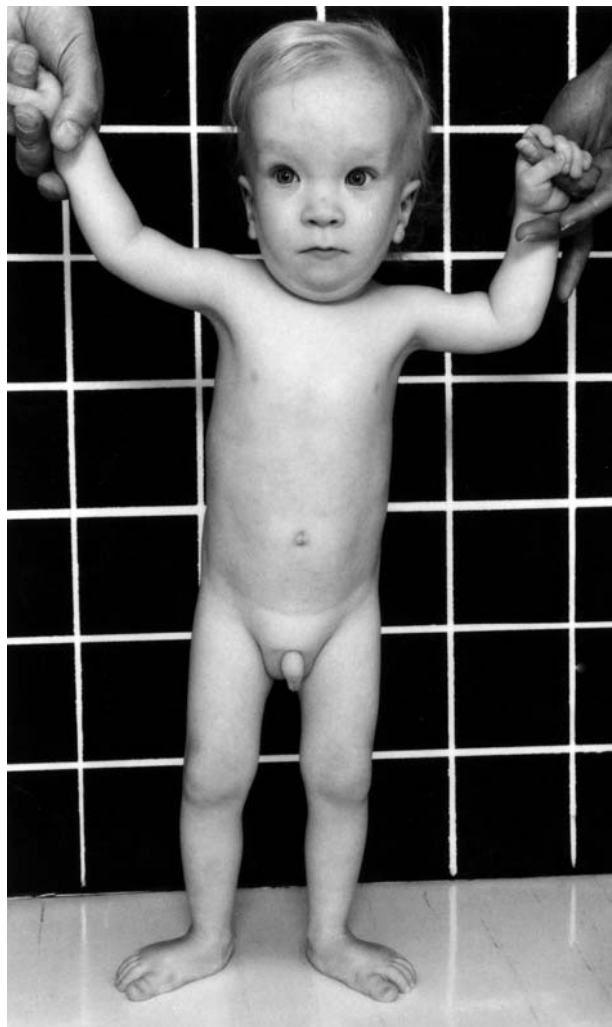

Figure 3 The characteristic appearance; triangular face, relative macrocephaly, general gracility, small bell shaped thoracic cage, and thin and proximally short limbs.

of extremities was noted in 17 patients (20%), which in two thirds was due to shortening by fibrous dysplasia. The thoracic cage was small and bell shaped with unusually thin ribs in nearly all patients (table 4, fig 6). Twelve patients had an enlarged heart on chest radiography.

Laboratory findings

Serum levels of the aminotransferases were slightly elevated in nearly half of the patients, AST up to 110 U/l (mean 61 U/l) and ALT up to 193 U/l (mean 41 U/l). Blood haemoglobin, white cells and platelets, glucose, gas analysis, and serum concentrations of electrolytes and creatinine were within the normal limits in the majority of patients. No other laboratory parameters were commonly abnormal.

DISCUSSION

In this work, we analysed retrospectively the clinical characteristics of patients with MUL in all 85 known Finnish patients at the time of diagnosis. At least 79 were homozygous for the Finn major mutation of the *TRIM37* gene. The results confirm that MUL is a distinct but variable entity. The most consistent findings were intrauterine onset growth failure and characteristic craniofacial features. Organ manifestations varied considerably in early childhood. In seven of the families, there was an affected sibling. In five of

Table 3 Organ manifestations at the time of diagnosis in 85 patients with Mulibrey nanism

Feature	Findings in age groups			Frequency (%)
	<1 year (n = 29)	1–5 years (n = 29)	>5 years (n = 27)	
Heart				
Signs of heart disease	6	4	5	18
Cardiomegaly	4	2	6	14
Dyspnoea	4	1	5	12
Prominent veins on upper body	3	1	5	11
Cardiac anomaly	6	2	4	15
ASD	3	1	2	8
VSD	1	1	2	5
Open ductus arteriosus	2	0	0	3
Heart failure (CHF)	4	1	5	12
Pericardial constriction	2	1	2	6
Liver				
Hepatomegaly	16	9	13	45
Hepatosplenomegaly	4	1	4	11
Ascites	3	0	6	11
Liver tumours	2	2	2	9
Urogenital				
Renal anomaly	4	4	6	18
Hydronephrosis	2	0	3	6
Abnormally located kidney	1	1	2	5
Hypoplastic kidneys	1	2	1	5
Horseshoe kidney	1	1	0	2
Male genital anomaly*				6
Cryptorchidism	1/13	3/15	1/11	6
Female genital anomaly†				2
Hyperplastic labiae	0/16	1/14	0/16	1
Prominent clitoris	0/16	1/14	1/16	2
Wilms' tumour	0	1	1	3
Benign renal neoplasia	1	0	1	3
Nervous system				
Yellowish dots in the ocular fundi	20	17	24	79
Muscular hypotonicity	23	19	15	68
Large cerebral ventricles and basal cisterns	16	13	8	44
Slow speech development	7	9	5	30
Slow motor development	5	9	6	29
Skin				
Cutaneous naevi flammei	16	20	19	65

*Males (n = 39); †females (n = 46)

these, the clinical findings were quite similar in the siblings, but in two families the phenotype showed great variation.

The clinical features have been previously reported.^{1 2 10 16 17} These reports, however, were based on small numbers of genetically unconfirmed patients. In our present series we verified the *TRIM37* mutations and concentrated on the phenotype in infancy and at the time of diagnosis.

The clinical diagnosis of MUL is a challenge during the first months of life. Infants with intrauterine growth failure are a heterogeneous group, and the facial features of patients with MUL are not unique in this group. In addition, relative macrocephaly with wide fontanelles might give a false impression of prematurity or hydrocephalus. However, the pre- and post-natal growth characteristics narrow the group in which MUL should be looked for. Generally, infants with MUL are both abnormally short and light for length. Additionally, they not only fail to catch up in postnatal growth, but their growth failure progresses. Of all newborns, 5% are born SGA, but only 1.5% are both short and light for length.¹⁸ Further, most (>70%) healthy infants born SGA show a good catch up growth during the first few months of life.^{18 19} Consequently, it is in the small subgroup of children born SGA and lacking postnatal catch up growth that the possibility of MUL should be considered.

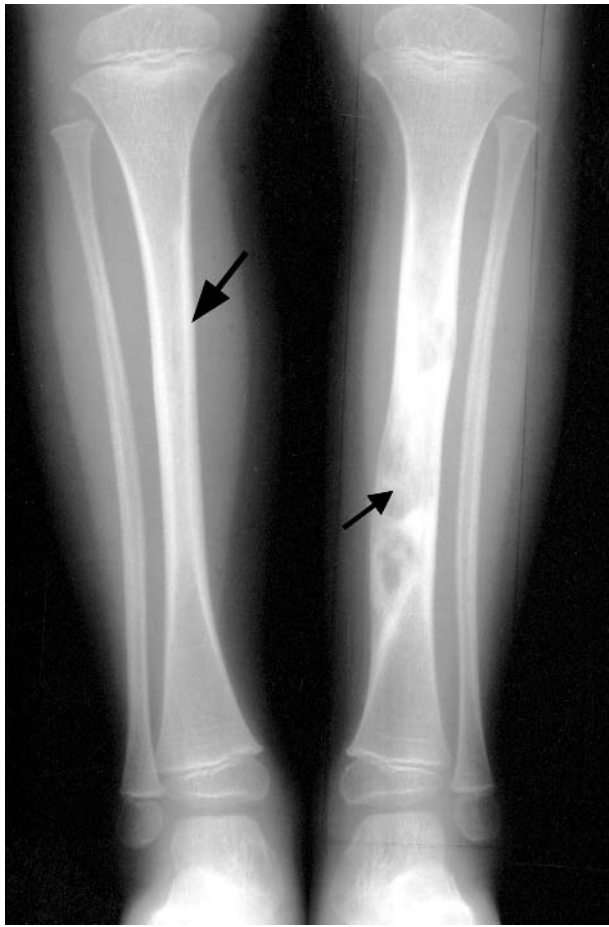

Figure 4 The characteristic x ray findings: slender long bones with thick cortex and narrow medullary channel (big arrow). Fibrous dysplasia in the middle third of left tibia (small arrow).

Silver-Russell syndrome (SRS) is the other dysmorphic growth disorder characterised by severe intrauterine growth failure with absence of postnatal catch up growth. The fact that patients with MUL and SRS both are gracile with similar facial dysmorphism makes SRS the most important differential diagnosis. In early infancy, feeding difficulties occur in both MUL and SRS. These two conditions, however, develop their own distinct characteristics. Clinodactyly, small face with marked triangularity, micrognathia, downturned mouth corners, and skeletal asymmetry with hemihypertrophy are

Table 4 Radiological findings in 85 patients with Mulibrey nanism

Feature	Frequency(%)
Head	
Occipitofrontal bossing	90
Low and shallow (J shaped) sella turcica	89
Laterally rotated orbital fossae	80
Small hypoplastic face	71
Orbital hypertelorism	64
Large cerebral ventricles and cisternas	43
Body	
Accentuated lumbal lordosis	96
Bell shaped thorax with unusually thin ribs	94
Extremities	
Slender long bones	93
Fibrous dysplasia of long bone	25

characteristics of SRS.²⁰⁻²² Hepatomegaly, heart failure due to pericardial constriction or cardiomyopathy, yellow dots in ocular fundi, cortical thickening, and fibrous dysplasia of long bone do not occur in SRS. SRS, however, is considerably variable both clinically²¹ and genetically.²³ A mild phenotype, for example, is observed in SRS patients with maternal uniparental disomy of chromosome 7.²² Furthermore, atypically mild cases with MUL have been diagnosed in three Finnish infants since the analysis of *TRIM37* became available.

The *TRIM37* protein is localised to peroxisomes, but its function is unknown. It is expressed in several tissues.¹⁴ Thus, it is no surprise that MUL shares features with other peroxisomal disorders. These include growth failure, facial dysmorphism with midface hypoplasia, retinal pigmentary changes, skeletal dysplasia, skin changes, cardiac involvement, muscular hypotonicity, and hepatomegaly. In particular, Refsum's disease, with its cardiac manifestations such as cardiomyopathy leading to congestive heart failure, resembles many of the features of MUL.²⁴ Lack of major neurological manifestations and mental retardation are the most notable differences between Mulibrey nanism and the known peroxisomal disorders. The only neurological dysfunctions occurring in MUL are mild muscular hypotonicity and slight delay in motor and speech development.

Constrictive pericarditis²⁵ with restrictive cardiomyopathy, when present, dominates the clinical state as well as the prognosis.²⁶ However, only 12% of our patients had congestive heart failure at the time of diagnosis (median 2.1 years) and even half of the adult patients were free of major heart problem.²⁶ In contrast, almost all patients

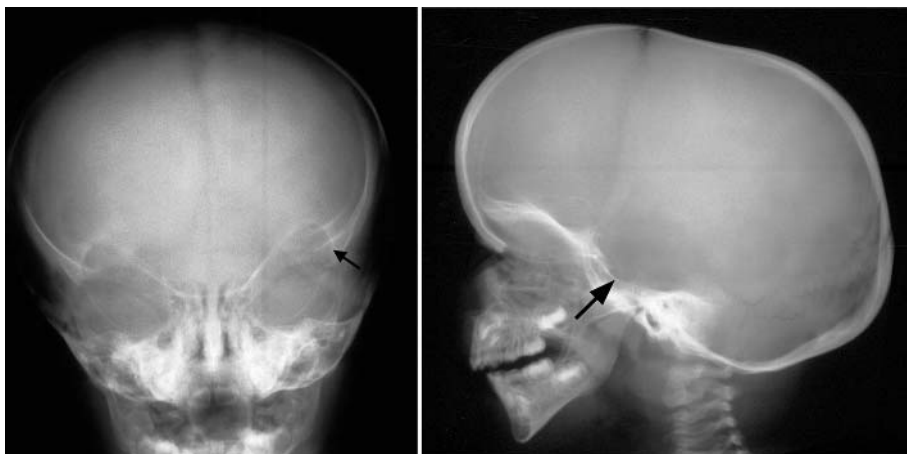

Figure 5 A characteristic cranium with high and broad forehead, small face, orbital hypertelorism, and scaphocephaly with occipitofrontal bossing and J shaped sella turcica (large arrow). Note the characteristic slightly upward slanting orbital fossae with the laterally rotated axis (small arrow).

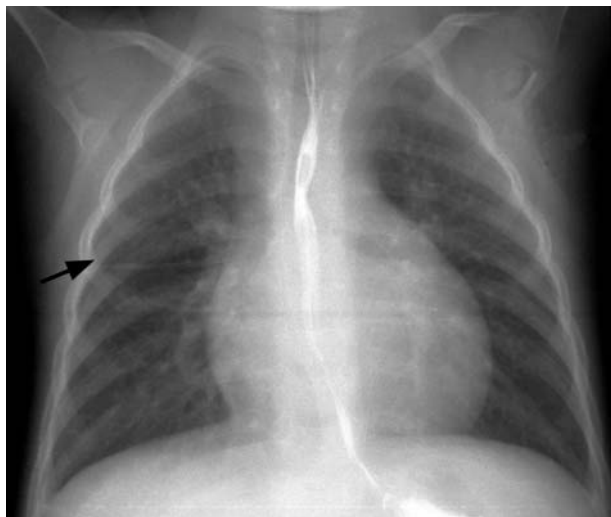


Figure 6 The small bell shaped thoracic cage with thin ribs (arrow). Note the characteristically rounded heart shadow frequently seen in children with MUL.

reported from outside Finland were notably compromised by the heart disease. Presumably, while MUL is relatively well known to Finnish paediatricians, it is elsewhere mostly recognised by its characteristic heart disease. As the heart involvement is critical for the prognosis, its early diagnosis is of major importance.

Hepatomegaly was obvious in half of the patients at the time of the diagnosis. Histopathological studies showed chronic passive congestion, indicating that the liver enlargement is an early clinical sign of the heart disease. At the time of the diagnosis, 10% of the patients had liver tumours as detected by radiological examinations or autopsy. The tumours differed in size and were often multifocal. Histopathological analysis of the tumour samples revealed hamartomas with fibrosis and lipid degeneration. To reveal these lesions, abdominal ultrasonography is regularly performed, and if suspicion of liver tumours arise, MRI is indicated. Beside liver tumours, two of the patients had Wilms' tumour as published previously for one Finnish and one non-Finnish patient.^{6 11} The biological basis of the tumour development remains to be solved.

Feeding difficulties are a major clinical problem during infancy. In general, swallowing is poorly coordinated in infants born prematurely or SGA and the degree of dysfunction is inversely related to the degree of immaturity and growth failure.^{27 28} The oral anatomy of mature infants are particularly well suited for eating by sucking, with the tongue being relatively large, filling the oral cavity.^{27 29} Infants with MUL, however, have a hypoplastic and anteriorly triangular shaped tongue. This is evident in nearly 70% of these infants. The craniofacial hypoplasia, maturational delay,¹⁷ and muscular hypotonicity all probably contribute to the feeding difficulty. Early recognition and management are important because dysphagia poses a threat to the child's respiratory function and nutrition, and may also contribute to the failure of catch up growth.

Patients with MUL are prone for respiratory tract infections and have an exceptionally high risk for pneumonia. No immunological defects have been demonstrated in MUL and the basis of this susceptibility is not known. Possibly, the pneumonia may result from aspiration. Interestingly, infections quite easily lead to respiratory failure, suggesting that the ability to cope with the stress of an infection is subnormal. In our study, two patients

Table 5 Diagnostic signs and their prevalence in 85 patients with Mulibrey nanism (46 females and 39 males) For the diagnosis, three major signs with one minor sign are required, or two major signs with three minor signs

Signs	Frequency(%)
Major signs	
Growth failure (A or B or C)	
A) small for gestational age (SGA) lacking catch up growth	95
B) height in children 2.5 SDS below population mean for age	94
C) height in adults 3.0 SDS below population mean	90
Characteristic radiological findings (A or B)	
A) slender long bones with thick cortex and narrow medullar channels	93
B) low and shallow (J-shaped) sella turcica	89
Characteristic craniofacial features	90
Scaphocephaly, triangular face, high and broad forehead, low nasal bridge and telecanthus	
Characteristic ocular findings	
Yellowish dots in retinal mid peripheral region	79
Mulibrey nanism in a sibling	17
Minor signs	
Peculiar high pitched voice	96
Hepatomegaly	70
Cutaneous naevi flammei	65
Fibrous dysplasia of long bone	25

died in infancy from an infection. At autopsy, both were found to have adrenal cortical hypoplasia. Subnormal stress tolerance could be due to adrenal hypoplasia with adrenocortical failure.

While growth failure, the craniofacial features, and hepatomegaly are important clinical consequences of MUL, they are also common features of other dysmorphic conditions. Hence, the characteristic ocular and radiological findings, cutaneous naevi flammei, fibrous dysplasia of the long bones, or signs of the Mulibrey heart disease are confirmatory of the MUL diagnosis. Based on our present findings and clinical experience, we propose revised diagnostic criteria for Mulibrey nanism (table 5). Importantly, while none of the clinical features was constant, 99% of our patients presented with at least three of the major and one of the minor signs. One patient had only two major signs, but he had three of the minor signs (table 5).

In conclusion, we have delineated the phenotype and defined the clinical diagnostic criteria in the genotypically homogenous series of all known Finnish patients with Mulibrey nanism. Different *TRIM37* mutations may not lead to exactly the same phenotype. However, it is important that infants born SGA, lacking postnatal catch up growth, and having poor weight gain, hepatomegaly, and characteristic craniofacial features should evoke suspicion of Mulibrey nanism. Although rare, this condition might also underlie congestive heart failure and failure to thrive in absence of a clear characteristic dysmorphism.

ACKNOWLEDGEMENTS

We want to thank the families of our patients. We also express our gratitude to the patients' local physicians, particularly Drs S Friman, J Komulainen, H-L Lenko and M Pere, for decades of co-work. This study was supported by grants from the Finnish Foundation for Paediatric Research, the Finnish Academy, and Finska Läkaresällskapet.

Authors' affiliations

N Karlberg, H Jalanko, J Perheentupa, M Lipsanen-Nyman, The Hospital for Children and Adolescents, Biomedicum Helsinki, University of Helsinki, 00029 HYKS, Finland

REFERENCES

- 1 **Perheentupa J**, Autio S, Leisti S, Tuuteri L, Raitta C. Mulibrey nanism: dwarfism with muscle, liver, brain and eye involvement. *Acta Paediatr Scand* 1970;**59**(Suppl 206):74–5.
- 2 **Perheentupa J**, Autio S, Leisti S, Raitta C, Tuuteri L. Mulibrey nanism, an autosomal recessive syndrome with pericardial constriction. *Lancet* 1973;**2**:351–55.
- 3 **Thoren C**. So-called Mulibrey nanism with pericardial constriction. *Lancet* 1973;**29**:731.
- 4 **Cumming GR**, Kerr D, Ferguson CC. Constrictive pericarditis with dwarfism in two siblings (mulibrey nanism). *J Pediatr* 1976;**88**:569–72.
- 5 **Voorhess ML**, Husson GS, Blackman MS. Growth failure with pericardial constriction. The syndrome mulibrey nanism. *Am J Dis Child* 1976;**130**:1146–8.
- 6 **Similä S**, Timonen M, Heikkinen E. A case of mulibrey nanism with associated Wilms' tumor. *Clin Genet* 1980;**17**:29–30.
- 7 **Sanchez-Corona J**, Moran-Vazquez O, Rivera H, Hernandez A, Serrano-Lucas JI, Ocampo-Campos R, Lasso-Avalos L, Maria-Cantus J. Mulibrey nanism in a Mexican child. *Bol Med Hosp Infant Mex* 1983;**40**:45–8.
- 8 **Cotton JB**, Rebelle C, Boiso A, Ladreyt-Ponchon JP, Maillat J. Familial intrauterine nanism with constrictive pericarditis, the MulibrEy syndrome. *Pediatr* 1988;**43**:197–203.
- 9 **Haraldsson A**, van der Burgt CJ, Weemaes CM, Otten B, Bakkeren JA, Stoelinga GB. Antibody deficiency and isolated growth hormone deficiency in a girl with Mulibrey nanism. *Eur J Pediatr* 1993;**152**:509–12.
- 10 **Lapunzina P**, Rodriguez JI, de Matteo E, Gracia R, Moreno F. Mulibrey nanism: three additional patients and a review of 39 patients. *Am J Genet* 1995;**55**:349–55.
- 11 **Seemanova E**, Bartsch O. Mulibrey nanism and Wilms' tumor. *Am J Med Genet* 1999;**85**:76–8.
- 12 **Jaggiello P**, Hammans C, Wiczorek S, Arning L, Stefanski A, Strehl H, Epplen JT, Gencik M. A novel splice site mutation in the TRIM37 gene causes Mulibrey nanism in a Turkish family with phenotypic heterogeneity. *Hum Mut* 2003;**21**:630–35.
- 13 **Avela K**, Lipsanen-Nyman M, Idänheimo N, Seemanova E, Rosengren S, Mäkelä TP, Perheentupa J, de la Chapelle A, Lehesjoki AE. Gene encoding a new RING-B-box-Coiled-coil protein is mutated in mulibrey nanism. *Nat Genet* 2000;**25**:298–301.
- 14 **Lehesjoki AE**, Reed VA, Mark Gardiner R, Greene ND. Expression of MUL, a gene encoding a novel RBCC family ring-finger protein, in human and mouse embryogenesis. *Mech Dev* 2001;**108**:221–5.
- 15 **Kallijärvi J**, Avela K, Lipsanen-Nyman M, Ulmanen I, Lehesjoki AE. The TRIM37 gene encodes a peroxisomal RING-B-box-Coiled-coil protein: Classification of mulibrey nanism as a new peroxisomal disorder. *Am J Hum Genet* 2002;**70**:1215–28.
- 16 **Raitta C**, Perheentupa J. Mulibrey nanism; an inherited dysmorphic syndrome with characteristic ocular findings. *Acta Ophthalmol Suppl* 1974;**123**:162–71.
- 17 **Myllärniemi S**, Koski K, Perheentupa J. Craniofacial and dental study of mulibrey nanism. *Cleft Palate J* 1978;**15**:369–77.
- 18 **Albertsson-Wikland K**, Karlberg J. Natural growth in children born small for gestational age with and without catch-up growth. *Acta Paediatr* 1994;**83**(Suppl 399):64–70.
- 19 **Hokken-Koelega ACS**, De Ridder MAJ, Lemmen RJ, Den Hartog H, De Muinck Keizer-Schrama SMPF, Drop SLS. Children born small for gestational age: Do they catch up? *Pediatr Res* 1995;**38**:267–71.
- 20 **Escobar V**, Gleiser S, Weaver DD. Phenotypic and genetic analysis of the Silver-Russell syndrome. *Clin Genet* 1978;**13**:278–88.
- 21 **Price SM**, Stanhope R, Garrett C, Preece MA, Trembath RC. The spectrum of Silver-Russell syndrome: a clinical and molecular genetic study and new diagnostic criteria. *J Med Genet* 1999;**36**:837–42.
- 22 **Hannula K**, Kere J, Pirinen S, Holmberg C, Lipsanen-Nyman M. Do patients with maternal uniparental disomy for chromosome 7 have a distinct mild Silver-Russell phenotype? *J Med Genet* 2001;**38**:273–8.
- 23 **Hitchins MP**, Stainer P, Preece MA, Moore GE. Silver-Russell syndrome: a dissection of the genetic aetiology and candidate chromosomal regions. *J Med Genet* 2001;**38**:810–19.
- 24 **Leys D**, Petit H, Bonte-Adnet C, Millaire A, Fourrier F, Dubois F, Rosseaux M, Ducloux G. Refsum's disease revealed by cardiac disorders. *Lancet* 1989;**1**:621.
- 25 **Tuuteri L**, Perheentupa J, Rapola J. The cardiopathy of mulibrey nanism, a new inherited syndrome. *Chest* 1974;**65**:628–31.
- 26 **Lipsanen-Nyman M**, Perheentupa J, Rapola J, Sovijärvi A, Kupari M. Mulibrey heart disease: Clinical manifestations, long-term course and results of pericardiectomy in a series of 49 patients born before 1985. *Circulation* 2003;**107**:2810–15.
- 27 **Tuchman DN**. Dysfunctional swallowing in the pediatric patient: clinical considerations. *Dysphagia* 1988;**2**:203–8.
- 28 **Selley WG**, Ellis RE, Brooks WA. Coordination of sucking, swallowing and breathing in the newborn: its relationship to infant feeding and normal development. *Br J Disord Commun* 1990;**25**:311–27.
- 29 **Stevenson RD**, Allaire JH. The development of normal feeding and swallowing. *Pediatr Clin North Am* 1991;**38**:1439–53.

CORRECTION

doi: 10.1136/jmg.2003.010363corr1

DFNA49, a novel locus for autosomal dominant nonsyndromic hearing loss, maps proximal to DFNA7/DFNM1 region on chromosome 1q21-q23 (*J Med Genet* 2003;**40**:832–836).

Owing to a fault in the production process an error was introduced to figure 2 of this paper. The last gene at the bottom of the figure should correspond to CASQ1, and not to ATP1A2, which is mapped just above it. We apologise for this error.



Mulibrey nanism: clinical features and diagnostic criteria

N Karlberg, H Jalanko, J Perheentupa, et al.

J Med Genet 2004 41: 92-98

doi: 10.1136/jmg.2003.014118

Updated information and services can be found at:

<http://jmg.bmj.com/content/41/2/92.full.html>

References

These include:

This article cites 29 articles, 6 of which can be accessed free at:

<http://jmg.bmj.com/content/41/2/92.full.html#ref-list-1>

Article cited in:

<http://jmg.bmj.com/content/41/2/92.full.html#related-urls>

Email alerting service

Receive free email alerts when new articles cite this article. Sign up in the box at the top right corner of the online article.

Notes

To request permissions go to:

<http://group.bmj.com/group/rights-licensing/permissions>

To order reprints go to:

<http://journals.bmj.com/cgi/reprintform>

To subscribe to BMJ go to:

<http://group.bmj.com/subscribe/>